

Noncommunicating isolated enteric duplication cyst in the abdomen in children: report of one case and review of the literature

Hyun-Young Kim, Soo-Hong Kim, Kwi-Won Park and Sung-Eun Jung

Noncommunicating isolated enteric duplications in the abdomen are an extremely rare variant of enteric duplications with their own blood supply. We report a case of a noncommunicating isolated ileal duplication in a 10-month-old boy. He was admitted because of severe abdominal distension and developed irritability abruptly. Abdominal ultrasound and computed tomography scan revealed a closed loop of small bowel that was dilated severely. A large tubular cyst hanging on the narrow vascular pedicle arising from the base of the terminal ileum mesentery was found with torsion of the pedicle in the right upper quadrant of the abdomen. Laparoscopic excision was performed successfully. Here, we will also review the previously reported cases to raise awareness of

Introduction

Enteric duplication cysts are rare congenital anomalies that vary in figure, size, location and symptom. They can develop throughout the entire alimentary tract, but the ileum is the most common site. By definition, enteric duplication cysts are located on the mesenteric side of the alimentary tract and usually share a common blood supply and muscle layer with the adjacent wall of part of the gastrointestinal tract but have a separate mucosa [1,2].

Noncommunicating isolated enteric duplications (NCID) in the abdomen are extremely rare with only 15 previous cases having been reported in the English literature [3–14].

We report the case of a NCID that was excised laparoscopically in a 10-month-old boy and also review previous cases.

Case report

A 10-month-old boy presented to us with abruptly developed abdominal distension and irritability since 2 days. He was previously healthy. At presentation, the child was lethargic and dehydrated. He also had a fever with a body temperature of 38°C. The hematological investigations revealed leukocytosis with WBC counts of $20.11 \times 10^3/\mu\text{l}$ and mild anemia with hemoglobin levels of 10.6 g/dl. The other laboratory findings were remarkable. Abdominal ultrasound and computed tomography scan revealed long-segment dilatation and fluid retention in the small bowel loop in the right abdomen, which was diagnosed as a closed small bowel loop with unknown origin (Fig. 1a and b).

Laparoscopic exploration was performed. A completely isolated small bowel loop hanging on the narrow vascular pedicle arising from the base of the terminal ileum

noncommunicating isolated enteric duplications in the literature. *Ann Pediatr Surg* 9:124–126 © 2013 Annals of Pediatric Surgery.

Annals of Pediatric Surgery 2013, 9:124–126

Keywords: abdomen, children, duplication, isolated, noncommunicating

Department of Pediatric Surgery, Seoul National University College of Medicine, Seoul, Korea

Correspondence to Hyun-Young Kim, MD, Department of Pediatric Surgery, Seoul National University Children's Hospital, 101 Daehang-ro, Yeongseon-dong, Jongro-gu, Seoul 110-744, Korea
Tel: +82 2 2072 2478; fax: +82 2 747 5130; e-mail: spkhy2@snu.ac.kr

Received 22 January 2013 accepted 30 April 2013

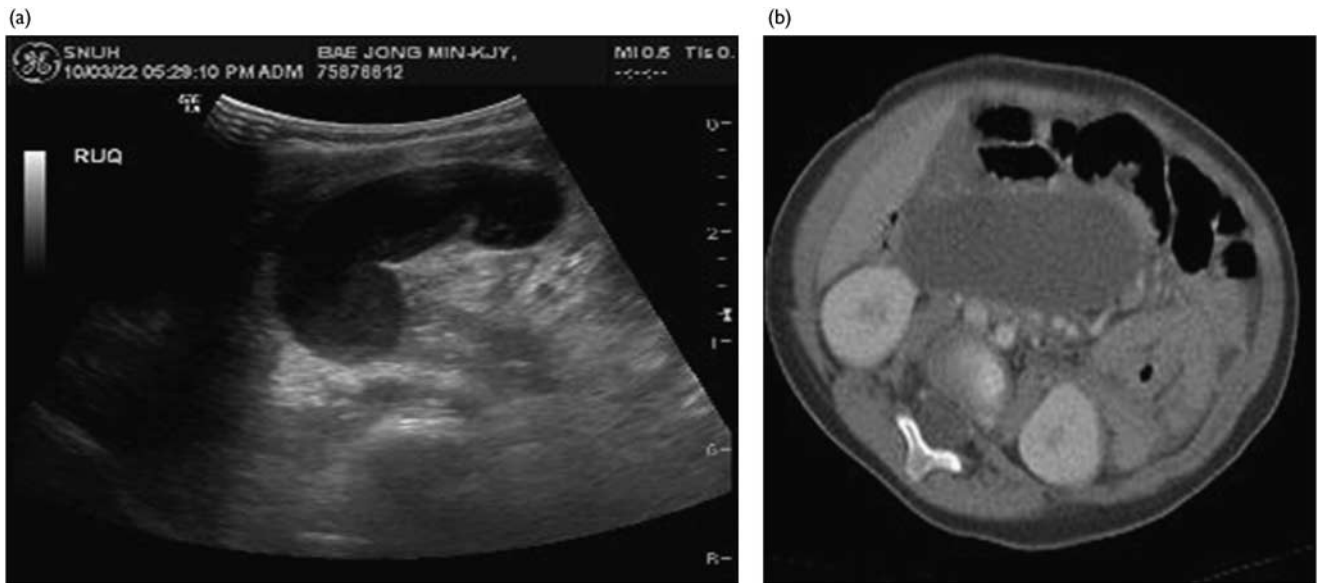
mesentery was found in the right upper quadrant of the abdomen. The torsion of the pedicle of the isolated small bowel loop was identified, and the isolated small bowel loop was severely distended and showed ischemic change. We performed laparoscopic excision using ultrasonic shear, and the large cystic lesion was exteriorized using a 11-mm umbilical port after aspiration of the turbid and gray-colored fluid that filled the lesion. The histopathological findings showed an extremely thin wall with two distinct muscle layers and mostly denuded focally flattened lining epithelium, compatible with a duplication cyst (Fig. 2a and b).

Discussion

Several theories have been proposed to explain the pathogenesis of a noncommunication isolated intestinal duplication cyst. Some authors hypothesized that pathologic events are preceded by torsion or some vascular accident at the proximal end of the diverticulum, which results in detachment of the intestinal wall and ultimately in a completely isolated duplication cyst. However, in several cases, the cyst's feeding vessels might arise from the retroperitoneal space. This findings suggest that isolated duplication cysts could have occurred at an early gestational stage by abnormal splitting of the notochord [3,10,14,15].

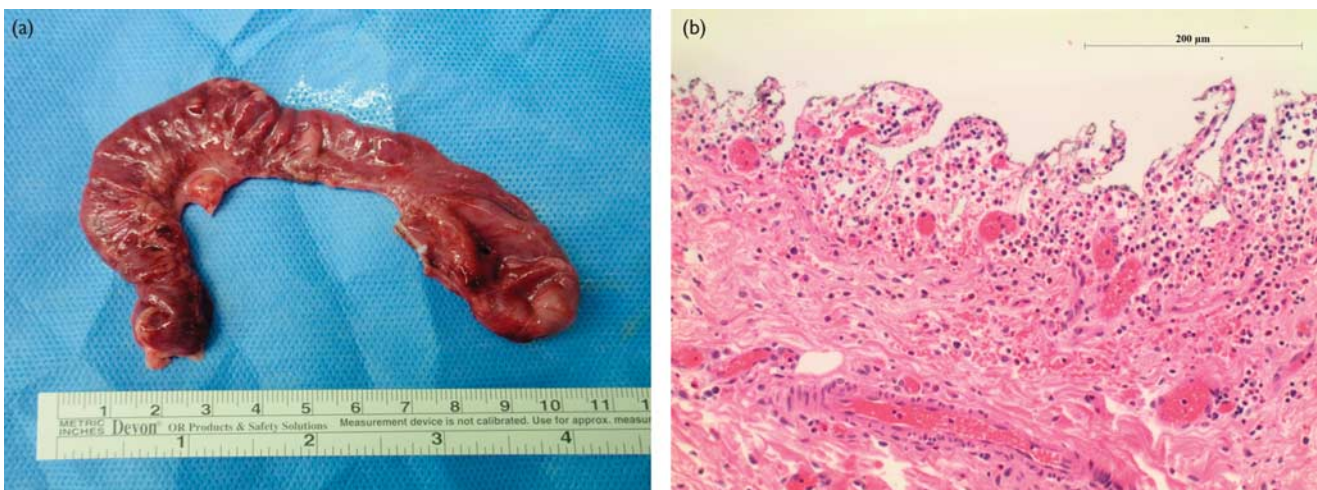
Previous reports recommended the surgical removal of NCID without symptoms because many serious complications or even malignant transformation may result from these anomalies [11]. An NCID attached by a narrow pedicle can undergo torsion and can also rupture because of accumulation of secretions. It could lead to volvulus of the adjacent intestine because of adherence and inflammation [5,7,10,13]. Furthermore, differentiation between intestinal duplication and other cysts including mesenteric, omental, or ovarian cysts using ultrasound findings

Fig. 1



(a, b) Abdominal ultrasound and computed tomography scan showing a long-segmental fluid-filled dilated cyst in the abdomen.

Fig. 2



(a) Operative specimen showing a blind-ended long tubular cyst measuring 15 × 6 cm with its narrow pedicle. (b) Histopathological findings showing an extremely thin wall with two distinct muscle layers and mostly denuded, focally flattened lining epithelium, compatible with a duplication cyst.

or computed tomography scans seems impossible [3–14]. Therefore, the ideal treatment for isolated noncommunication duplication cysts is an early operative removal and can be accomplished safely without the need for bowel resection. Because of the advancement in laparoscopic instruments and methodology, laparoscopic approach is applied widely in the pediatric field. We suggest that laparoscopic surgery could be an appropriate diagnostic and/or therapeutic tool if a cystic lesion of unknown origin is observed in the abdominal cavity in children.

Since Steiner and Mogilner [3] first described it in 1999, 15 cases of NCID in the abdomen have been reported in

the English literature (Table 1) [4–15]. There were 10 male patients and four female patients; the sex of one patient was not described. Except for two patients, 13 were children. Seven cases were prenatally detected. A total of 17 cysts were detected; all patients had solitary NCIDs, except for two who had two cysts [6,10]. The origin of the vascular pedicles for the 17 cysts was as follows: from the ileal mesentery for six cysts, from the mesentery in the vicinity of the Treitz ligament for three cysts, a retroperitoneal origin for two cysts, from the ileocecal area for two cysts, from the sigmoid colon mesentery for one cyst, and from the gastroepiploic vessel for one cyst. The origin of the pedicle of two cysts was not described. The cysts were excised without sacrificing

Table 1 Summary of noncommunicating isolated enteric duplications in the abdomen

References	Age at operation	Sex	Presentation	Origin of feeding vessel	Inner layer	Associated anomaly
Steiner and Mogilner [3]	7 days	M	Prenatal US, abdominal mass	Treitz ligament	Gastric mucosa	–
Kim <i>et al.</i> [4]	28 years	M	Abdominal mass	Treitz ligament	Gastric mucosa	–
Sinha <i>et al.</i> [5]	4 days	F	Abdominal mass, lethargy, failure to feed	Ileum	Gastric mucosa	–
Menon <i>et al.</i> [6]	6 days	M	Abdominal mass	Ileum	?	–
	2 months	M	Abdominal mass	Treitz ligament, retroperitoneal area	?	Mediastinal cystic mass, thoracic vertebra anomaly
Nakazawa <i>et al.</i> [7]	9 days	M	Prenatal US	Gastroepiploic vessel	Gastric mucosa	–
Roeck <i>et al.</i> [8]	11 years	M	Abdominal pain, anorexia, fever	Ileum	Respiratory epithelium	–
Srivastava <i>et al.</i> [9]	3 years	F	Abdominal pain	Ileocecal area	?	–
Maestri <i>et al.</i> [10]	11 days	M	Prenatal US	Ileocecal area	?	Ileal duplication
	1 day	F	Prenatal US	Ileum	?	Ileal atresia, Meckel's diverticulum
	5 months	?	Crying and vomiting	?	?	–
	3 months	M	Prenatal US	Ileum	?	–
Okamoto <i>et al.</i> [11]	27 day	M	Prenatal US, MRI	Retroperitoneal area	Gastric mucosa	–
Tomas <i>et al.</i> [13]	64 years	F	Incidentally detection by abdomen CT	Ileum	Mucinous cystadenoma	Bilateral breast cystadenoma
Talenfeld and Hulett	16 days	M	Prenatal US, poor feeding, irritability	Sigmoid colon	?	–

F, female; M, male; US, ultrasound.

any bowel because they did not share a common blood supply and wall with the adjacent alimentary segment. The age at operation ranged between 64 years and 1 day after birth. Laparoscopic excision was performed only in one patient. The histopathological findings of their epithelial lining were varied: the gastric mucosa in five patients, an unusual respiratory epithelium was observed in one patient, a mucinous cystadenoma was observed in one patient, and almost denuded linings were observed in several cases.

Acknowledgements

Conflicts of interest

There are no conflicts of interest.

References

- Lund DP. Alimentary tract duplications. In: Grosfeld JL, O'Neill JA, Fonkalsrud EW, Coran AG, editors. *Pediatric surgery*. 6th ed. St Louis: Mosby; 2006. pp. 1389–1390.
- Holcomb GW 3rd, Gheissari A, O'Neil JA Jr, Shorter NA, Bishop HC. Surgical management of alimentary tract duplications. *Ann Surg* 1989; **209**:167–184.
- Steiner Z, Mogilner J. A rare case of completely isolated duplication cyst of the alimentary tract. *J Pediatr Surg* 1999; **34**:1284–1286.
- Kim SK, Lim HK, Lee SJ, Park PK. Completely isolated enteric duplication cyst: case report. *Abdom Imaging* 2003; **28**:12–14.
- Sinha A, Ojha S, Sarin YK. Completely isolated, noncontiguous duplication cyst. *Eur J Pediatr Surg* 2006; **16**:127–129.
- Menon P, Rao KLN, Vaiphei K. Isolated enteric duplication cysts. *J Pediatr Surg* 2004; **39**:e5–e7.
- Nakazawa N, Okazaki T, Miyano T. Prenatal detection of isolated gastric duplication cyst. *Pediatr Surg Int* 2005; **21**:831–834.
- De Roeck A, Vervloessem D, Mattelaer C, Schwagten K. Isolated enteric duplication cyst with respiratory epithelium: case report and review of the literature. *Eur J Pediatr Surg* 2008; **18**:337–339.
- Srivastava P, Gangopadhyay AN, Kumar V, Upadhyaya VD, Sharma SP, Jaiman R, *et al.* Noncommunicating isolated enteric duplication cyst in childhood. *J Pediatr Surg* 2009; **44**:9–10.
- Maestri L, Caponcelli E, Fava G, Leva E, Vella C, Marinoni F, *et al.* Completely isolated enteric duplications cysts: a survey of four cases. *Pediatr Med Chir* 2009; **31**:2011–2014.
- Okamoto T, Takamizawa S, Yokoi A, Satoh S, Nishijima E. Completely isolated alimentary tract duplication in a neonate. *Pediatr Surg Int* 2008; **24**:1145–1147.
- Sharma KK, Ranka P, Meratiya S. Isolated cervical esophageal duplication: a rarity. *J Pediatr Surg* 2005; **40**:591–592.
- Tomas D, Zovak M, Čiček S, Sulentic P, Jukić Z, Kruslin B. Mucinous cystadenoma arising in an isolated ileal duplication cyst. *J Gastrointest Cancer* 2007; **38**:127–130.
- Talenfeld AD, Hulett RL. Neonatal diagnosis of an isolated sigmoid colon duplication cyst. *Pediatr Radiol* 2003; **33**:436–438.
- Akers DR, Favara BE, Franciosi RA, Nelson JM. Duplications of the alimentary tract: report of three unusual cases associated with bile and pancreatic ducts. *Surgery* 1972; **71**:817–823.