

# Laparoscopic management of right paraduodenal hernia along with the correction of malrotation in a pediatric patient: a case report

Rahul K. Gupta, Paras Kothari, Abhaya Gupta, Ritesh Ranjan, Krishna K. Kesan, Kedar Mudkhedkar, Parag Karkare and Niyaz Mohammed

Paraduodenal hernias (PDH) are rare; however, they are the most common form of internal hernias. A 11-year-old boy presented to us with a history of intermittent abdominal pain since 1 year. His physical examination was normal. Plain abdominal radiographs and ultrasonography were inconclusive. Contrast-enhanced computed tomography of the abdomen reported a right subhepatic cecum. The patient underwent diagnostic laparoscopy followed by successful laparoscopic right PDH repair (excision of hernial sac, release of Ladd's bands, and appendectomy). Ours is the sixth report to describe laparoscopic repair of a right PDH and the third in the pediatric age group. He was discharged home on

postoperative day 1. He was completely asymptomatic at the 1-year follow-up. *Ann Pediatr Surg* 9:90–92 © 2013 Annals of Pediatric Surgery.

*Annals of Pediatric Surgery* 2013, 9:90–92

**Keywords:** laparoscopic, malrotation, paraduodenal hernia, pediatric

Department of Pediatric Surgery, Lokmanya Tilak Municipal Medical College & General Hospital, Mumbai, India

Correspondence to Rahul K. Gupta, Department of Pediatric Surgery, Lokmanya Tilak Municipal Medical College & General Hospital, Mumbai, India  
Tel: +91 9833112941; e-mail: [drrahulg78@yahoo.co.in](mailto:drrahulg78@yahoo.co.in)

Received 30 March 2012 accepted 3 January 2013

## Introduction

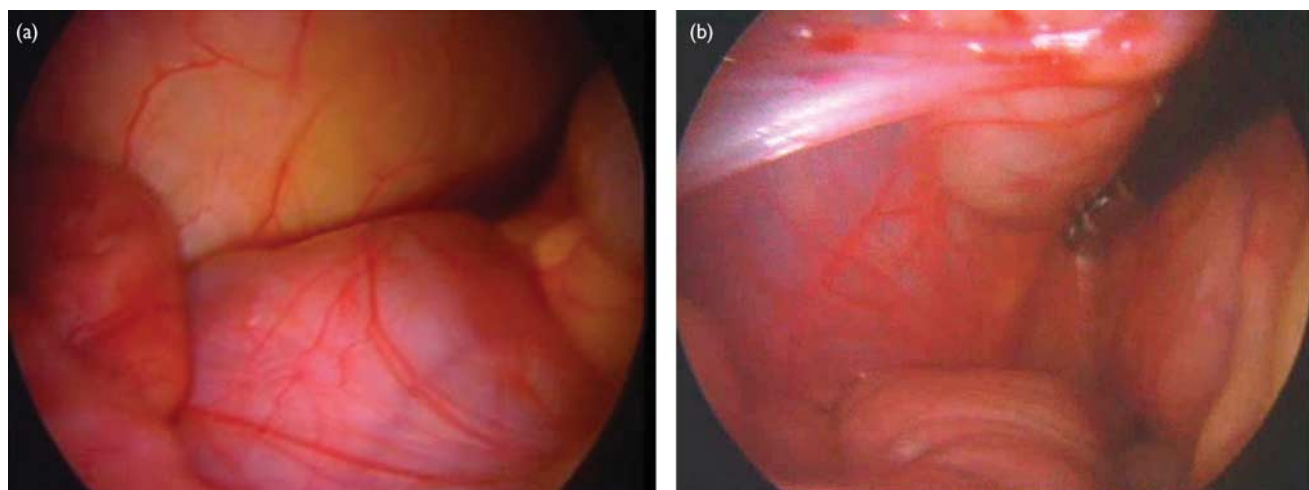
Paraduodenal hernias (PDH) are the most common type of internal hernias, accounting for up to 53% of cases. There are only five prior published reports describing laparoscopic repair of a right PDH [1–5]. We describe herein the successful laparoscopic repair of a right PDH and correction of malrotation in a pediatric patient (youngest of all the patients managed by laparoscopy).

## Case report

An 11-year-old boy presented to us with complaints of intermittent epigastric pain since 1 year. Physical examination, radiography, and ultrasonography of the abdomen were normal. Helical computed tomography (CT) of the

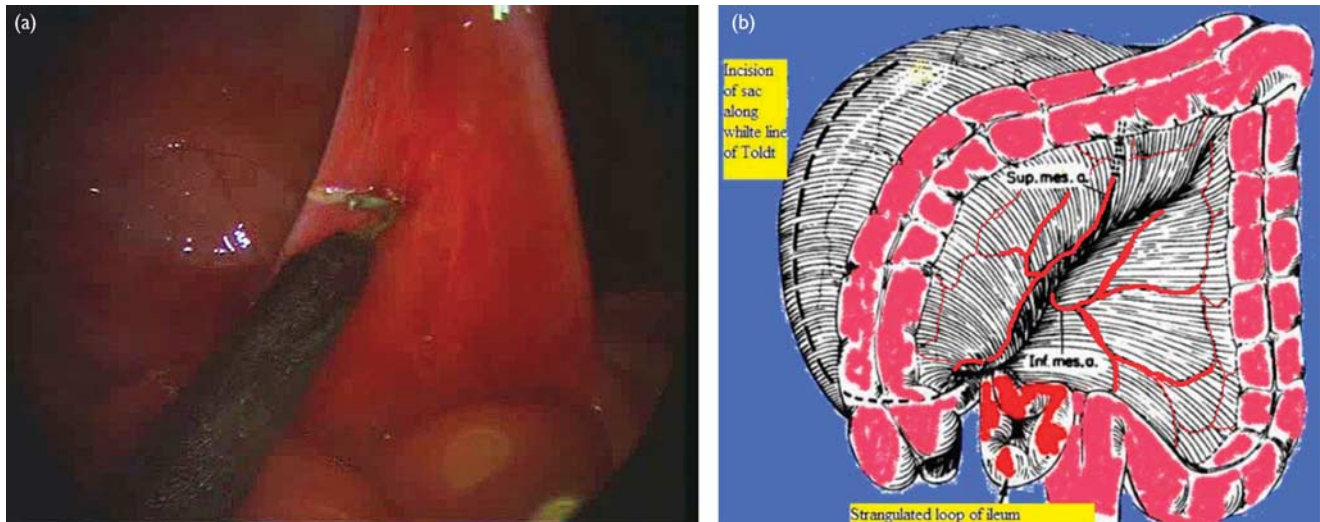
abdomen reported as essentially normal, except for the presence of a right subhepatic cecum with a subhepatic bowel mass. We were also not sure about the preoperative diagnosis. Therefore, diagnostic laparoscopy was planned. The patient was placed in the supine position. Using Hasson's open technique, the pneumoperitoneum (8 mmHg) was reached through a 5-mm umbilical port (used as a camera port for a 5-mm 30° telescope). Two additional 5-mm abdominal trocars (left hypochondrium and midline infraumbilical) were placed as working ports. Diagnostic laparoscopy revealed a right retrocolic mass defect along with herniated jejunum within the PDH sac (Fig. 1a and b). To better visualize the mesenteric defect, the cecum was elevated. The 5 mm laparoscope was then shifted to the left lower quadrant trocar to allow better

Fig. 1



(a) Jejunal loops encased in the hernial sac lateral to the ascending colon are shown. (b) Retrocolic defect with herniated proximal jejunal loops.

Fig. 2



(a) Excision of the everted hernial sac. (b) Schematic representation of the line of incision. Inf.mes.a., inferior mesenteric artery; sup.mes.a., superior mesenteric artery.

visualization of the jejunum, posterior to the superior mesenteric artery and inferior to the third portion of the duodenum. The laparoscope was advanced toward the mesenteric defect to thoroughly delineate the hernia aperture before and during reduction. The distal limb was then reduced using 5-mm atraumatic bowel graspers. The hernial sac was everted inside out and excised with a hook cautery (Fig. 2a). The patient was placed in a head-down position with the table tilted to the patient's left side to facilitate exposure and bowel manipulation. Next, the ascending colon was mobilized along the white line of Toldt using a sharp scissor dissection, and a peritonealized space was subsequently entered consistent with the hernia sac itself (Fig. 2b). The small bowel mesenteric defect was not widely patent, and so we continued the dissection between the right mesocolon medially and the perinephric space laterally to open the hernia defect widely. The hernial defect was left open. The right hepatic flexure was mobilized along with the cutting of Ladd's bands, which were extending from the colon to the right subhepatic region and to the gallbladder, crossing across the second part of the duodenum. Widening of the jejuno-cecocolic isthmus along with appendectomy was carried out. Straightening of the duodenum was also carried out. The entire large bowel was packed on the left side, and trocar wounds were closed. The total operative time was ~130 min. He was discharged on the first postoperative day and was completely asymptomatic at the 1-year follow-up.

## Discussion

PDH is a congenital disorder of midgut rotation and is very rare. Abnormal rotation of the midgut during development results in failure of the mesentery to fuse with the parietal peritoneum. PDH occurs because of failure of the prearterial limb to complete the 270° counterclockwise rotation. Abdominal plain radiographs are unlikely to yield a definitive diagnosis. A preoperative upper gastrointestinal contrast study may demonstrate

a collection of small bowel loops, lateral and inferior to the second portion of the duodenum or behind the ascending colon. An abdominal CT scan can demonstrate a cluster of small bowel behind the right mesocolon, causing mass effect on the ascending colon in the right upper quadrant; encapsulation of the small bowel along with at least one segment of the jejunum can be seen traversing Waldeyer's fossa in the root of the small bowel mesentery posterior to the superior mesenteric vessels, at a position more ventral and leftward to the superior mesenteric vein, with the absence of a normal horizontal duodenum [6].

PDH can be diagnosed successfully by laparoscopy when preoperative imaging studies are inconclusive [1,7]. Reports of laparoscopic surgery for left PDH appear slightly more often in the literature than do reports for right PDH. Till date, five case reports [7–11] depict the use of laparoscopy to confirm the diagnosis of a left PDH. In each of these reports, authors describe laparoscopic repair of a left PDH without the need for conversion [7–10]. One previous report [11] describes the failure of preoperative barium lower gastrointestinal and CT studies to reveal a right PDH, which was identified during laparoscopic colon resection for known diverticulitis. The surgeon in this case converted to an open procedure because of an unclear anatomy. If right PDH is identified incidentally during a laparoscopic procedure, then surgical correction should be undertaken because of a lifetime risk of incarceration approaching 50%. We recommend the use of sound surgical judgment to guide the operative approach in this situation.

Only five published reports [1–5] detail laparoscopic repair of a right PDH in the world literature till date. The first case was reported by Antedomenico *et al.* [1] in a 24-year-old woman associated with malrotation. The second reported case was of a boy of 13 years diagnosed incidentally after a road traffic accident [2]. The third case was a 13-year-old girl, who presented with features

of small bowel obstruction [3]. The fourth case was of a 26-year-old woman, who presented with intermittent, bilateral inguinal, and epigastric pain associated with nausea and emesis [4]. In the fifth report, all of the four patients with PDH presented with features of intestinal obstruction [5]. Our patient, a 11-year-old, was one of the youngest patients. In the above reported cases, they obtained access to the peritoneal cavity through one periumbilical 10-mm trocar, a 5-mm trocar in each quadrant of the abdomen (working ports) along with an additional 5-mm port for better delineation of the hernial orifice (a total of four ports). In cases 1, 2, and 4, the authors then opened the hernia sac widely through a lateral approach and released the small bowel into the abdominal cavity, whereas in case 3, the hernial opening was closed laparoscopically. The patients' hospital courses were uncomplicated, and they were discharged on the third postoperative day. This differs from the present case, in which we elected to use three laparoscopic trocars with one 5-mm periumbilical, one 5-mm left lower quadrant, and one 5-mm lower quadrant trocars. Our operative approach and the patient's hospital length of stay also differed slightly. After diagnostic laparoscopy, we first reduced the small bowel into the peritoneal cavity gently and altered the patient's position to facilitate visualization of Waldeyer's fossa, and then we completely opened the small bowel mesenteric defect from a lateral approach. We also mobilized the right hepatic flexure along with the cutting of Ladd's bands that were extending from colon to the right subhepatic region and to the gallbladder, crossing across the second part of the duodenum. Widening of the cecocolic isthmus along with appendectomy was carried out. The patient tolerated the procedure without complication and was discharged on postoperative day 1.

The surgical principles are reduction and closure of the hernia defect without a mesh or widening of the hernial neck if the contents are not reducible. With left PDH, bowel can often be reduced easily and the peritoneum of the descending mesentery adjacent to the inferior mesenteric vein can be approximated easily with the posterior abdominal wall lateral to the fourth portion of the duodenum. Right PDH often poses more of a

problem, as the hernia contents can be fixed to the retroperitoneum. In principle, the operation tries to recreate the embryological situation before rotation (or better malrotation) of the prearterial midgut. Therefore, the lateral attachments of the ascending colon in the paracolic gutter should not be approached medially, as the superior mesenteric artery, the ileocolic artery, and the right colic vein are in danger of being injured.

To expedite diagnosis and to reduce the length of hospital stay, surgeons must keep the diagnosis of PDH in their mind while evaluating chronic abdominal pain. Physical examination and abdominal radiographs followed by diagnostic laparoscopy and definitive laparoscopic repair is a viable option for patients with right PDH.

## Acknowledgements

### Conflicts of interest

There are no conflicts of interest.

## References

- 1 Antedomenico E, Singh NN, Zagorski SM, Dwyer K, Chung MH. Laparoscopic repair of a right paraduodenal hernia. *Surg Endosc* 2004; **18**:165–166.
- 2 Dassinger MS, Eubanks JW. Laparoscopic repair of a right paraduodenal hernia in a child. *JLS* 2007; **11**:266–267.
- 3 Bhartia V, Kumar A, Khedkar I, Savita K, Goel N. Laparoscopic repair of a right para duodenal hernia. *J Minim Access Surg* 2009; **5**:121–123.
- 4 Bittner JG IV. Laparoscopic right paraduodenal hernia repair. *J Minim Access Surg* 2010; **6**:89–90.
- 5 Palanivelu C, Rangarajan M, Jategaonkar PA, Anand NV, Senthilkumar K. Laparoscopic management of paraduodenal hernias: mesh and mesh-less repairs. A report of four cases. *Hernia* 2008; **12**:649–653.
- 6 Osadchy A, Weisenberg N, Wiener Y, Shapiro-Feinberg M, Zissin R. Small bowel obstruction related to left-side paraduodenal hernia, CT findings. *Abdom Imaging* 2005; **30**:53–55.
- 7 Finck CM, Barker S, Simon H, Marx W. A novel diagnosis of left paraduodenal hernia through laparoscopy. *Surg Endosc* 2000; **14**:87.
- 8 Uematsu T, Kitamura H, Iwase M, Yamashita K, Ogura H, Nakamura T, Oguri H. Laparoscopic repair of a paraduodenal hernia. *Surg Endosc* 1998; **12**:50–52.
- 9 Fukunaga M, Kidokoro A, Iba T, Sugiyama K, Fukunaga T, Nagakari K, et al. Laparoscopic surgery for left paraduodenal hernia. *J Laparoendosc Adv Surg Tech A* 2004; **14**:111–115.
- 10 Rollins MD, Glasgow RE. Left paraduodenal hernia. *J Am Coll Surg* 2004; **198**:492–493.
- 11 Brunner WC, Sierra R, Dunne JB, Simmang CL, Scott DJ. Incidental paraduodenal hernia found during laparoscopic colectomy. *Hernia* 2004; **8**:268–270.