

Tubularized incised plate technique for recurrent hypospadias: a local experience from Egypt

Ossama M. Zakaria^a, Ashraf Hussein^a and Tamer A. Sultan^b

Objectives To evaluate our local experience of tubularized incised plate (TIP) repair (Snodgrass method) in the management of recurrent hypospadias.

Summary background data TIP repair has been well described for use in salvage hypospadias repairs, with good results.

Patients and methods This prospective, descriptive study was carried out over a period of 5 years from December 2003 to December 2008. The study included 30 patients; all of these patients had previously undergone hypospadias repair, and the indication for surgery was complete failure of the previous repair. Classic TIP repair was performed, although tissues for barrier layers between the neourethra and skin closures were not as readily available.

Results Secondary TIP repair was successful in 25/30 patients (83.3%). These patients showed no postoperative complications and had a slit-like meatus and a forward-

directed urinary stream without branching. Their parents were satisfied with the repair results.

Conclusion Our local experience coincides with data of the literature that TIP is an excellent option in the treatment of recurrent hypospadias when the results of primary techniques are unsatisfactory. *Ann Pediatr Surg* 8:80–85 © 2012 Annals of Pediatric Surgery.

Annals of Pediatric Surgery 2012, 8:80–85

Keywords: recurrent hypospadias, salvage hypospadias, tubularized incised plate

^aDepartment of Surgery, Division of Pediatric and Plastic Surgery, Faculty of Medicine, Suez Canal University, Ismailia and ^bDepartment of Surgery, Faculty of Medicine, Menoufia University, Shebin El-Koum, Egypt

Correspondence to Ossama M. Zakaria, MD, PhD, Department of Surgery, Division of Pediatric and Plastic Surgery, Faculty of Medicine, Suez Canal University, Ismailia, Egypt
Tel: +20 101 223 233; e-mail: ossamaz2004@yahoo.com

Received 28 July 2011 accepted 3 March 2012

Introduction

Although modern hypospadias repairs have low complication rates, inevitably, there are occasional failures that require reoperation. Primary hypospadias repairs are associated with failure rates of 5–20% depending on the type of procedure performed, the location of the original meatus, and the quality of tissue available for the initial repair [1–6].

The principles of reoperation remain identical to those of the primary operation. The challenges of performing a secondary hypospadias repair include the lack of healthy or adequate amount of local tissue to create flaps for both the replacement and the coverage of the defective urethra and resurfacing the penile shaft [7].

These secondary procedures are often more difficult than the original surgery because there is less skin available to create flaps, and the vascularity of previously operated tissues may be suboptimal, resulting in further complications [2,5]. The potential advantages of tubularized incised plate (TIP) urethroplasty under these circumstances include the creation of the neourethra with no need for skin flaps and the opportunity to achieve good cosmetic results despite previous surgery [5,6,8–10].

Our study aimed to evaluate our local experience with TIP urethroplasty in the management of recurrent hypospadias.

Patients and methods

This prospective, descriptive study was carried out over a period of 5 years from December 2004 to December 2008, with a follow-up period of more than 2 years after surgery. The study included 30 patients; all of these patients had previously undergone different types of

hypospadias repair and the indication for surgery was complete failure of the previous repair. All patients were subjected to a thorough history taking, with particular focus on parental consanguinity, associated congenital anomalies, and clinical examination, with a special emphasis on the number(s) and type(s) of the previous original primary operations if available.

Thorough local examination was carried out to assess the state of the urethral plate, preputial skin if present, site of hypospadias, and the presence of chordee and the scrotum for a possible scrotal transposition. TIP was performed using a surgical technique similar to the primary TIP repair [11], except that tissues for barrier layers between the neourethra and skin closures were not as readily available.

In most cases, the urethral plate was not sufficiently wide at this point to tubularize it into a functional neourethra. Therefore, a relaxing incision was made in the midline from within the meatus to the end of the plate. The depth of the relaxing incision varies depending on whether the plate is flat or grooved, but always extends through the epithelium to near the underlying corpora cavernosa.

A suitable-sized stent is passed into the bladder [6–8] and secured with the glans traction suture. 6-0 vicryl is then used to tubularize the urethra, starting from the meatus to the glans. Tubularization is completed with a two-layer running subepithelial closure. Spongiosum is dissected and secured over the neourethra with interrupted sutures from proximal to distal; any adjacent dartos tissues are used to cover the neourethra dissected from the shaft of the penis, preputial skin, or tunica vaginalis flap. The tourniquet is removed and hemostasis is performed.

Reconstruction of the glans was performed by approximating the coronal margin with subepithelial 6-0 vicryl. The stent was fixed to the glans with transfix suture. Skin closure was performed using transverse mattress 5-0 vicryl sutures.

Finally, a sofra-Tulle dressing was used; a topical antibiotic cream was applied around the stent.

Follow-up was performed through outpatients' clinic visits. These visits were scheduled to be in the first week after surgery, followed by a session every 2 weeks in the first month, and then monthly for a period of at least 2 years period after surgery.

Functional results were assessed through urethral calibration after 2 months of surgery and uroflowmetry, whereas cosmetic results were evaluated by genital examination and on the basis of the family's satisfaction with the function and appearance of the penis. These measurements were performed weekly in the first month and then every 2 weeks in the subsequent months. After the second month, assessment of the neourethra by urethral calibration through a urethral catheter was performed during every visit. Patients with meatal stenosis were treated by urethral dilatation, whereas patients with fistulae were treated by fistula repair after the failure of spontaneous closure.

The urinary flow pattern, maximum (Q_{max}), and average flow rate (Q_{ave}) were determined; the results were expressed as percentiles and compared with the Toguri values from normal children. The Q_{max} and Q_{ave} were considered normal if they were above 25th percentile, equivocally obstructed if in the 5–25th percentile, and obstructed if below 5th percentile. The flow pattern was classified as a bell ring shape, plateau, or intermittent [12].

The Statistical Package for Social Sciences (SPSS version 17; SPSS, Chicago, Illinois, USA) was used for both data tabulation and analysis. Data were presented as appropriate as frequencies and percentages, mean, and SD; the χ^2 -test was used for qualitative data and Student's *t*-test was used for quantitative data. The level of significance for this study was *P*-value 0.05 or less.

Results

A total of 30 patients with recurrent hypospadias were enrolled in this study. The data on their preoperative characteristics are shown in Table 1.

The most commonly reported type of previous repair was meatal advancement and glanduloplasty (MAGPI) in six patients (20%). One patient who had been subjected to TIP urethroplasty had presented after 1 year of the previous repair. The rest of the patients had presented after a mean duration of 4.9 ± 3.1 years from the previous repair (Table 2).

On preoperative assessment of the status of the urethral plate, the results in terms of the presence or absence of foreskin because of circumcision are shown in Table 3. Only one patient in our series showed complete failure of the procedure. This patient had presented with a disturbed urethral plate that was markedly scarred

Table 1 Preoperative patient characteristics

Characteristics	N (%) (n=30)
Age (years)	
Mean \pm SD	7.5 \pm 3.9
Range	3–18
Consanguinity	
Positive	8 (26.7%)
Negative	22 (73.3%)
Chordee	
With chordee	10 (33.3%)
Without chordee	20 (66.7%)
Meatal location	
Coronal	7 (23.4%)
Distal penile	10 (33.3%)
Midshaft	10 (33.3%)
Proximal	2 (6.7%)
Penoscrotal	1 (3.3%)
History of other anomalies	
Congenital inguinal hernia	1 (3.3%)
Undescended testis	1 (3.3%)

Table 2 Distribution of the patients studied according to the type of previous repair

Type of previous repair	N (%)	Duration from the last repair (years)
MAGPI	6 (20%)	3.4 \pm 1.5
TIP	1 (3.3%)	1
Mathieu	3 (10%)	1.2 \pm 0.8
Unknown repair	20 (66.7%)	5.6 \pm 2.8

MAGPI, meatal advancement and glanduloplasty; TIP, tubularized incised plate.

(Fig. 1). A statistically significant difference was found between patients with a disturbed urethral plate and patients with an undisturbed urethral plate in terms of the reported complications (Table 3).

Postoperative urethral calibration was equal to or more than 8 Fr in cases of successful repair without meatal stenosis according to the patient's age; a calibration of 8–10 Fr was used on patients older than 3 years and up to 10 years of age, 10–12 Fr on patients from 10 to 15 years of age, and 12–14 Fr on patients 15 years of age or older.

Uroflowmetry results showed that the flow pattern was normal bell-shaped for all the patients, except one, with Q_{max} below the 25th percentile according to the Toguri nomogram. He had a plateau flow pattern and was found to have an asymptomatic meatal stenosis, which improved with urethral dilatation.

Considering meatal stenosis and fistulae rate, and a functional neourethra with a cosmetically normal slit-like meatus, our success rate was 86.7%.

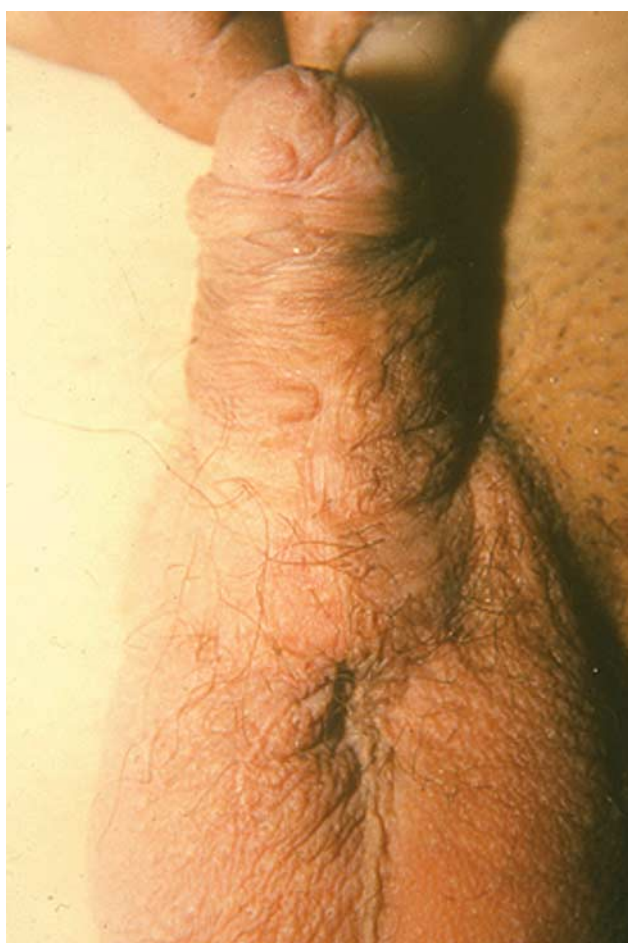Twenty-five patients showed no postoperative complications and had a slit-like meatus and a forward-directed urinary stream without branching and their parents rated the repair results as satisfactory. According to the meatal position and flow of urine, the results can be classified into highly acceptable when it fulfills all the objectives of hypospadias corrections, which include complete straightening of the penis, location of the meatus at the tip of the glans, formation of a symmetric conically shaped glans, construction of a neourethra that is uniform in

Table 3 Distribution of the patients studied according to the preoperative state of the urethral plate, and complications according to the condition of the urethral plate

	With a disturbed urethral plate	With an undisturbed urethral plate	Total	P-value
Distribution	17 (56.7%)	13 (43.3%)	30 (100%)	
Complete failure cases	1 (5.9%)	0 (0.0%)	1 (3.3%)	0.57 (NS)
Success cases	16 (94.1%)	13 (100.0%)	29 (96.7%)	
Total	17	13	30 (100%)	
Meatal stenosis	1 (5.9%)	1 (7.6%)	2 (6.7%)	> 0.05
Fistula rate	1 (5.9%)	1 (7.6%)	2 (6.7%)	
Both	2 (17.6%)	2 (15.2%)	4 (13.3%)	

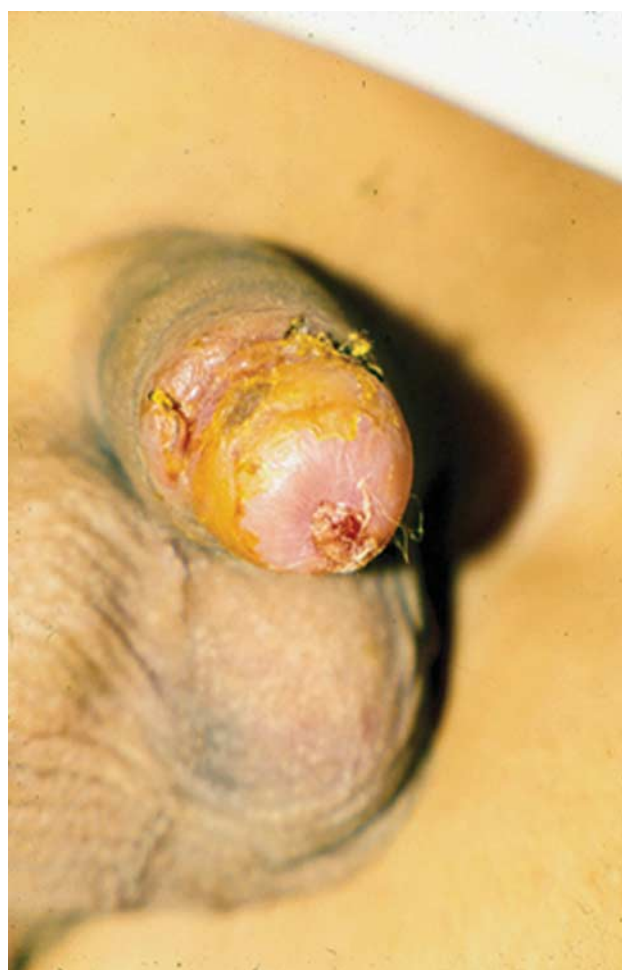NS, no statistically significant difference.

Fig. 1



Disturbed urethral plate with a scar on a previously repaired crippled hypospadias.

Fig. 2



Properly located meatus at the tip of the glans penis after tubularized incised plate repair (highly satisfactory).

caliber, and achievement of satisfactory cosmetic skin coverage with a forward stream of urine (Figs 2 and 3).

The results were considered as acceptable or satisfactory when the meatal opening is present at the glans, but in a slightly different position from normal, with no other deviations from the objectives (Figs 4 and 5 and Table 4).

Our results also showed no significant association between the outcome of the operation and meatal location, previous repair, and the presence of chordee. It was found that the younger the age of the patients and

the shorter the duration from the previous repair, the better the outcome of the operation (Table 4).

Discussion

In modern hypospadias surgery, achievement of normal anatomy and esthetically satisfactory penile appearance has become as important as functional results [13,14].

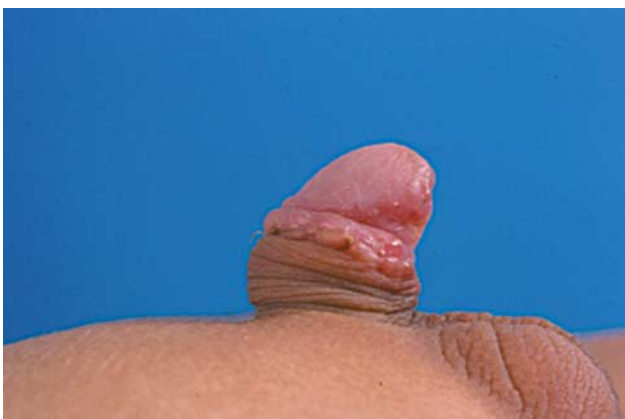
TIP repair for hypospadias has become more popular as an easy single-stage hypospadias repair technique, with many studies in the literature showing good results not only in primary hypospadias repair but also in the

Fig. 3



Normal forward flow of urine after tubularized incised plate repair (highly satisfactory).

Fig. 4

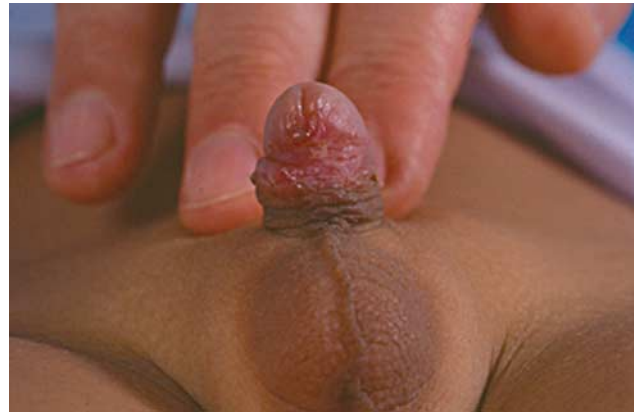

Urethral opening slightly shifted from the tip of the penis (satisfactory).

treatment of those with previously failed or unsatisfactory hypospadias repair [1–3,5,6,8–10,15–17].

In this study conducted on the local population, TIP was performed on 30 patients ranging in age from 3 to 18 years as the hypospadias repair age is still high in our country,

Fig. 5



Urethral opening slightly shifted from the tip of the penis (satisfactory).

especially in rural areas with poorer resources. These data are in agreement with those of others who have reported on a series of older patients, wherein the oldest hypospadias patient was 20 years old. The advanced age may lead to psychological problems in addition to those of erection and the risk of infection, especially in patients older than 15 years of age [13,17]. Moreover, some other researchers have reported data [18] in agreement with those of ours, wherein the oldest age of repaired hypospadias was also 18 years, in contrast to a report by Snodgrass [19], who, in 1994, reported that TIP was performed in 16 boys with primary hypospadias ranging in age from 6 months to 11 years. However, the same author in another study [20] reported a maximum age of 15 years for reoperation in hypospadias repair.

Our study did not have patients younger than 3 years of age. This may be because of the fear of another repair failure among Egyptian parents. This may also explain the high cooperation by all patients and their families with the follow-up, although it may have been tough for them to attend the outpatient department very frequently postoperatively.

In our series, 10 patients with penoscrotal, proximal, and midshaft hypospadias had mild-type chordee that resolved with penile degloving and dissection of the ventral dartos.

It was reported in a published study of 15 patients that three patients required dorsal plication to correct the ventral curvature [21]. Most of our patients had been operated upon previously by general surgeons: seven patients with coronal, 10 with distal penile, 10 with midshaft, two with proximal, and one with penoscrotal recurrent hypospadias. Of those, six patients had a previously failed MAGPI repair, one patient had failed TIP repair, three patients had failed Mathieu repair, and 20 patients presented after an unknown failed repair. This may have been because of an inadequate file system, and most parents were unaware of the complications of surgical repair in terms of the possibility of reoperation.

These data are comparable with those of another published report involving 15 patients in whom the

Table 4 Relation between the outcome of the operation and patients' characteristics

	Highly satisfactory	Satisfactory	Unsatisfactory	P-value
Age (years)	4.5 ± 1.7	9.1 ± 2.1	18 ± 0	0.001*
Meatal location				
Coronal	7 (100%)	0 (0%)	0 (0%)	0.6 (NS)
Distal penile	6 (66.7%)	3 (33.3%)	0 (0%)	
Midshaft	5 (45.5%)	5 (45.5%)	1 (9.0%)	
Proximal	1 (50%)	1 (50%)	0 (0%)	
Penoscrotal	1 (100%)	0 (0%)	0 (0%)	
Previous repair				
MAGPI	6 (100%)	0 (0%)	0 (0%)	0.4 (NS)
TIP	1 (100%)	0 (0%)	0 (0%)	
Mathieu	2 (66.7%)	1 (33.3%)	0 (0%)	
Unknown repair	12 (60%)	7 (35%)	1 (5%)	
Chordee				
With chordee	6 (50%)	5 (41.7%)	1 (8.3%)	0.2
Without chordee	13 (72.2%)	5 (27.8%)	0 (0%)	
Duration from previous repair (years)	2.3 ± 1.4	4.1 ± 1.9	6 ± 0	0.001*

MAGPI, meatal advancement and glanduloplasty; TIP, tubularized incised plate.

*Statistically significant difference, NS indicates no statistically significant difference.

meatus at reoperation was subcoronal or on the distal shaft in all, except one boy, who had a midshaft hypospadias; all the patients had previously undergone one attempt at hypospadias repair, except for one patient, who presented after two failed MAGPI procedures [21].

We calibrated the neourethra in all of our patients using a catheter with a calibration of 8 Fr or higher according to the patient's age on the first postoperative follow-up visit. During the follow-up period, the calibration was increased to be 10 Fr or more according to the patient's age and penile size. This calibration and dilatation may have led to a decrease in the fistulae rate as it reduces the incidence of meatal stenosis. Our results were similar to those of others [19], who reported using a neourethral calibration of 10 Fr or higher. Yet, two of our patients with meatal stenosis did show improvements with regular dilatation during the follow-up visit throughout the 24 weeks of follow-up.

Fistulae were reported in two of our patients (6.7%), who underwent surgical repairs. It has been hypothesized that the development of fistulae after TIP reoperation may be partly attributable to the relative lack of tissues available for coverage over the neourethra suture line [21]. Other authors found that four of the five boys who developed fistulae in their series had no barrier layer interposed over the urethra, and recommended mobilization of a dartos or a tunica vaginalis flap to reduce the incidence of fistulae [17]. Another report described the creation of a dartos flap from subcoronal shaft skin, with the development of a fistula only in one patient among 13 patients [22]. We used dartos flaps from several locations, but fistulae developed when adjacent tissues were sutured over the neourethra, probably indicating the need for a flap to be developed that can be secured over the urethra using laterally based sutures; otherwise, sutures from the neourethra, barrier layer, and skin closures may overlap.

The patient who had dehiscence and complete breakdown had previously undergone partial excision of the urethral plate during an unknown procedure for midshaft hypospadias; gross inspection showed supple tissues

extending from a coronal meatus that were incised and tubularized.

Contraindications to TIP urethroplasty for hypospadias reoperations may therefore include previous resection of the urethral plate or obvious scarring of the plate after a previous surgery. We were reluctant to incise skin that had been used to replace the urethral plate, as we expected re-epithelialization to occur, although it has been reported previously to succeed in six reoperations with satisfactory results [23].

It is unclear how many midline incisions can be made into the urethral plate with a reasonable expectation of a successful urethroplasty. Only one patient had undergone more than one previous operation; the TIP repair resulted in a neourethra with no meatal stenosis or stricture.

Other options for a one-stage reoperation include skin flaps and grafts. However, previous surgery often limits the availability of skin for urethroplasty, and even one operation can impair the blood supply to skin, increasing the risk of complications, including strictures and meatal stenosis. Accordingly, the complication rates for secondary flip-flaps, onlay, and tubularized flaps range from 14 to 56% in a large series [24]. Others have similarly concluded that these risks are too high and instead recommend onlay or tubularized buccal grafts [25]. One-stage buccal repairs in which the ventral urethra is reconstructed with a graft still rely on the variable blood supply of previously operated dartos and skin layers, and therefore, not surprisingly, complications occur in over half the patients [26]. This has been replaced by the two-stage Bracka's repair with a buccal mucosal graft as it is currently considered the best tool for complicated reoperative cases known as hypospadias cripples. Currently, the one-stage buccal mucosal graft is not favored [27,28].

We found no significant association between the outcome of the operation and meatal location, previous repair, and the presence of chordee. It was found that the younger the age of the patients and the shorter the duration since the previous repair, the better the outcome of the operation. However, the results of uroflowmetry showed

that the flow pattern was normal bell-shaped for all the patients, except one, with Q_{\max} below the 25th percentile according to the Toguri nomogram.

This was an unexpected result because the reconstructed urethras lack the expansile properties of a native urethra. This may have been because of the long follow-up period, which may have led to a better spontaneous improvement in the uroflowmetry pattern, in agreement with recently published data [29].

Conclusion

For recurrent hypospadias, TIP is an excellent treatment option, with some restrictions of its use in patients with a disturbed urethral plate with an apparent scarring of the plate as it may result in an excellent cosmetic appearance of the penis. It should be considered as the first reoperation option when the results of primary techniques are unsatisfactory. This work represents a regional experience from a developing country and provides some practical points for pediatric surgeons, especially those interested in hypospadias surgery.

Further meta-analytic and data-based evidence may be required to overcome the limitations of our study, which included the following: the small number and variability in the patient population, and the subjective assessment of the urethral plate and the cosmetic outcomes of the procedure.

Acknowledgements

Conflicts of interest

There are no conflicts of interest.

References

- Dolatzas T, Chiotopoulos D, Antipas S, Demetriades D, Ipsilantis S. Hypospadias repair in children: review of 250 cases. *Pediatr Surg Int* 1994; **9**:383–386.
- Gürdal M, Tekin A, Kireççi S, Şengör F. Intermediate-term functional and cosmetic results of the Snodgrass procedure in distal and midpenile hypospadias. *Pediatr Surg Int* 2004; **20**:197–199.
- Coplen DE. Reoperative hypospadias surgery and management of complications. In: Brandes SB, editor. *Urethral reconstructive surgery*. New York, USA: Humana Press; 2008. pp. 285–295.
- Hinderer UT. Functional and aesthetic results in hypospadias repair with Hinderer's techniques. *Aesthetic Plast Surg* 2000; **24**:323–343.
- Çakan M, Yalçinkaya F, Demirel F, Aldemir M, Altuğ U. The midterm success rates of tubularized incised plate urethroplasty in reoperative patients with distal or midpenile hypospadias. *Pediatr Surg Int* 2005; **21**:973–976.
- Mouriquand P, Mure P, Zeidan S. Management of failed hypospadias repairs. In: Hadidi AT, Azmy AF, editors. *Hypospadias surgery*. 1st ed New York: Springer; 2004.
- Eliçevik M, Tireli G, Demirali O, Ünal M, Sander S. Tubularized incised plate urethroplasty for hypospadias reoperations in 100 patients. *Int Urol Nephrol* 2007; **39**:823–827.
- Mustafa M, Wadie BS, Abol Enein H. Standard Snodgrass technique in conjunction with double-layer covering of the neourethra with dorsal dartos flap is the therapy of first choice for hypospadias. *Int Urol Nephrol* 2008; **40**:573–576.
- Pieretti RV, Pieretti A, Pieretti Vanmarcke R. Circumcised hypospadias. *Pediatr Surg Int* 2009; **25**:53–55.
- Mustafa M. The concept of tubularized incised plate hypospadias repair for different types of hypospadias. *Int Urol Nephrol* 2005; **37**:89–91.
- Lorenzo AJ, Snodgrass WT. Regular dilatation is unnecessary after tubularized incised-plate hypospadias repair. *BJU Int* 2002; **89**:94–97.
- Kaya C, Kucuk E, Ilktac A, Ozturk M, Karaman MI. Value of urinary flow patterns in the follow-up of children who underwent Snodgrass operation. *Urol Int* 2007; **78**:245–248.
- Fuse H, Akashi T, Yasuda K, Mizuno I. Tubularized incised plate urethroplasty for distal hypospadias, using overlapping dorsal subcutaneous flaps. *Int Urol Nephrol* 2002; **34**:535–537.
- Elder JS, Duckett JW. Urethral reconstruction following an unsuccessful one-stage hypospadias repair. *World J Urol* 1987; **5**:19–24.
- Al Hunayan AA, Kehinde EO, Elsalam MA, Al Mukhtar RS. Tubularized incised plate urethroplasty: modification and outcome. *Int Urol Nephrol* 2003; **35**:47–52.
- Baccala AA Jr., Ross J, Detore N, Kay R. Modified tubularized incised plate urethroplasty (Snodgrass) procedure for hypospadias repair. *Urology* 2005; **66**:1305–1306.
- Borer JG, Bauer SB, Peters CA, Diamond DA, Atala A, Cilento BG Jr, et al. Tubularized incised plate urethroplasty: expanded use in primary and repeat surgery for hypospadias. *J Urol* 2001; **165**:581–585.
- Elbakry A. Tubularized-incised urethral plate urethroplasty: Is regular dilatation necessary for success? *BJU Int* 1999; **84**:683–688.
- Snodgrass W. Tubularized, incised plate urethroplasty for distal hypospadias. *J Urol* 1994; **151**:464–465.
- Snodgrass WT, Lorenzo A. Tubularized incised-plate urethroplasty for hypospadias reoperation. *BJU Int* 2002; **89**:98–100.
- Snodgrass WT, Lorenzo A. Tubularized incised-plate urethroplasty for proximal hypospadias. *BJU Int* 2002; **89**:90–93.
- Shanberg AM, Sanderson K, Duel B. Re-operative hypospadias repair using the Snodgrass incised plate urethroplasty. *BJU Int* 2001; **87**:544–547.
- Luo CC, Lin JN. Repair of hypospadias complications using the tubularized, incised plate urethroplasty. *J Pediatr Surg* 1999; **34**:1665–1667.
- Simmons GR, Cain MP, Casale AJ, Keating MA, Adams MC, Rink RC. Repair of hypospadias complications using the previously utilized urethral plate. *Urology* 1999; **54**:724–726.
- Baskin LS, Duckett JW, Ueoka K, Seibold J, Snyder HM III. Changing concepts of hypospadias curvature lead to more onlay island flap procedures. *J Urol* 1994; **151**:191–196.
- Metro MJ, Wu HY, Snyder HM III, Zderic SA, Canning DA. Buccal mucosal grafts: lessons learned from an 8-year experience. *J Urol* 2001; **166**:1459–1461.
- Bracka A. A versatile two-stage hypospadias repair. *Br J Plast Surg* 1995; **48**:345–352.
- Bhattacharya S. A modified tubularised incised plate urethroplasty technique and a revised hypospadias algorithm. *Indian J Plast Surg* 2010; **43**:21–27.
- Andersson M, Doroszkiewicz M, Arfwidsson C, Abrahamsson K, Holmdahl G. Hypospadias repair with tubularized incised plate: does the obstructive flow pattern resolve spontaneously? *J Pediatr Urol* 2011; **7**:441–445.