

Post-Bacillus Calmette-Guérin lymphadenitis in Egyptian children: an outbreak

Rasha H. Hassan^a, Kamal Abel-Elah Aly^b, Shaimaa M. Kandil^a and Maysaa El Sayed Zaki^c

Background/purpose Intradermal vaccinations with Bacillus Calmette-Guérin (BCG) give rise to a classic primary complex that consists of a cutaneous nodule at the site of injection and swelling of the regional lymph nodes. This study was performed to evaluate the clinical course of BCG lymphadenitis in relation to different management strategies and to assess the microbial resistance to an Indian BCG strain causing an Egyptian outbreak.

Patients and methods Prospective analytical follow-up of 152 patients with BCG lymphadenitis attending the Mansoura University Children Hospital between March 2010 and May 2011; of these, eight patients who had lymph nodes that were ~1 cm in size (group A=5.3%) were managed with regular follow-up, 86 patients who presented with lymph nodes larger than 1–3 cm in size (group B=56.6%) received isoniazid and rifampicin for 6 months, and 58 patients who presented with lymph nodes larger than 3 cm in size or with BCG abscess or sinus (group C=38.1%) were subjected to early surgical excision.

Results Of the 152 patients, the male-to-female ratio was 1.7:1. The mean age was 5.97 months. The site of the lesions was the left axilla (132 patients, 86.84%), left supraclavicular (10 patients, 6.58%), cervical (four patients, 2.63%), and left axillary and supraclavicular (six patients, 3.95%). BCG lymphadenitis regressed spontaneously in four patients of group A (50%), 24 patients of group B showed an improvement in 6–9 months (27.9%), and progressive enlargement (44 cases, 51.2%) and

development of BCG abscesses (18 cases, 20.9%) occurred in the rest of the patients who needed surgical treatment. For group C, surgical excision was performed from the start. Pathological examination was performed for all excised lymph nodes (124 patients, 81.6%) and revealed granulomas with extensive caseation necrosis. Microbiological examination was performed in all cases and revealed acid fast bacilli in 100 samples (80.6%) that were resistant to isoniazid, pyrazinamide, and streptomycin but sensitive to rifampicin only in 25 samples.

Conclusion As antituberculous therapy was found to be ineffective in the management of BCG lymphadenitis, we recommend a careful choice of BCG vaccines to avoid multidrug-resistant strains, early surgical excision of lymph nodes larger than 3 cm and lymphadenopathy complicated with abscess or sinus formation, and regular follow-up of smaller lymph nodes. *Ann Pediatr Surg* 8:69–73

© 2012 Annals of Pediatric Surgery.

Annals of Pediatric Surgery 2012, 8:69–73

Keywords: Bacillus Calmette-Guérin lymphadenitis, outbreak, tuberculosis, vaccination

^aPediatric Infectious Diseases and Malnutrition Unit, ^bPediatric Surgery Department and ^cClinical Pathology Department, Faculty of Medicine, Mansoura University, Mansoura, Egypt

Correspondence to Kamal Abdel-Elah Aly, Pediatric Surgery Department, Faculty of Medicine, Mansoura University, Mansoura, Egypt
Tel: +20 122 447 637; fax: +2 050 9182131; e-mail: kamalaly5@yahoo.com

Received 20 November 2011 accepted 15 February 2012

Introduction

Mycobacterium bovis Bacillus Calmette-Guérin (BCG) vaccine is one of the most commonly administered vaccines worldwide. It is a live-attenuated vaccine derived from *M. bovis*, and for historical reasons, a number of genetically different BCG vaccine strains are in use today [1,2]. It is administered to all babies in Egypt within the first 40 days of life as a part of the global expanded program of immunization recommended by the WHO [3].

Intradermal vaccinations with BCG give rise to a classic primary complex that consists of a cutaneous nodule at the site of injection and swelling of the regional lymph nodes. This is usually self-limiting and requires no treatment [4].

Despite being considered a safe vaccine, complications because of BCG vaccination can be classified into mild and severe. Mild complications are usually localized, and the most common complication is regional lymphadenitis. Cutaneous complications, such as lupoid reaction and eczema vaccinatum, form part of the mild spectrum of complications. The incidence of mild complications because of BCG is less than one per 1000 cases [5].

Severe complications caused by BCG are suppurative lymphadenitis, osteitis/osteomyelitis, and disseminated BCG infection. Their incidence rates are 100–1000 cases, one to 700 cases, and two cases per 1 million vaccinations, respectively [6].

The reported treatment of BCG lymphadenitis varies from observation and follow-up to medical treatment or surgical excision of the involved lymph nodes [7–9].

The influence of the particular BCG vaccine strain or its susceptibility pattern to antituberculous drugs is not considered when treating local adverse reactions and disseminated BCG disease [10,11]. There are only limited data on the susceptibility of BCG to different antituberculous drugs and even less on the influence of genetic differences between BCG vaccine strains on susceptibility [12].

This study was conducted to evaluate the course of BCG lymphadenitis occurring during an outbreak, which was initiated because of a change from a Danish strain to an Indian one, and its response to different management

strategies as there are no clear data on the best treatment of these infants.

Patients and methods

This study was a prospective analytic follow-up of 152 patients with BCG lymphadenitis attending Mansoura University Children Hospital between March 2010 and May 2011. They were assessed for age at presentation, sex, place of vaccinations, site and size of lymphadenitis, development of abscesses or discharging sinuses, microbiological and histopathological data, chest radiographs, treatment, and outcome.

The criteria for the diagnosis of BCG lymphadenitis were as follows:

- (1) Isolated axillary, supraclavicular, or cervical lymph node enlargement,
- (2) history of BCG vaccination on the same side,
- (3) absence of fever and other systemic symptoms [10].

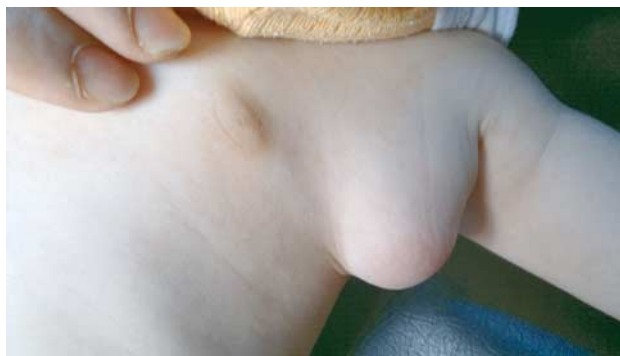According to the presenting features and sizes of the lesions, the patients were categorized into three groups: eight patients whose lymph nodes were ~1 cm in size (group A, 5.3%) were managed by regular follow-up, 86 patients who presented with lymph nodes larger than 1–3 cm in size (group B, 56.6%) received isoniazid and rifampicin for 6 months, and 58 patients (group C, 38.1%) who presented with lymph nodes larger than 3 cm in size (38 cases) or presented with BCG abscess (16 cases) or sinus (four cases) were subjected to early surgical excision. Thus, group B was the only group that received antituberculous drugs.

Surgical technique

The cases were preoperatively prepared with a 10-day course of macrolides to decrease inflammation and facilitate surgical dissection. Surgery was performed under general anesthesia. The arm was abducted to expose the lesion (Fig. 1) An axillary or a supraclavicular skin crease incision was performed. This incision was substituted with an elliptical skin incision when the lesion was attached to the skin. The mass with the surrounding tissues and other enlarged lymph nodes were dissected and excised without injury to the axillary structures (Fig. 2). The abscess (Fig. 3) was similarly managed after drainage of the necrotic material. Tuberculous sinus, when present, was circumscribed and excised with the underlying lymph nodes. Then, the wound was irrigated with saline and a penrose drain was inserted. The wound was closed with 4/0 polygalactin sutures. Macrolides were administered for the first 10 postoperative days [8,13,14]. The drain and the sutures were removed 7 days after the operation. During the postoperative follow-up (4–6 months) period, the operative site was observed for the development of abscesses, sinuses, or lymph nodes.

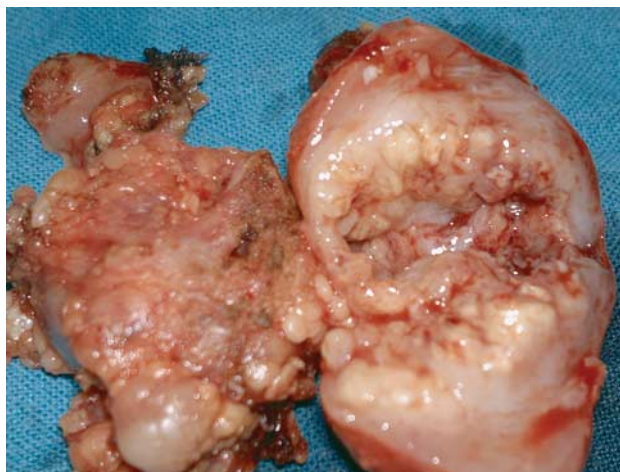
The excised mass was preserved in saline 0.9% and processed for culture and Ziehl–Neelsen stain of mycobacteria using standard procedures in multiple media. The deposit of the ground homogenized specimen

Fig. 1



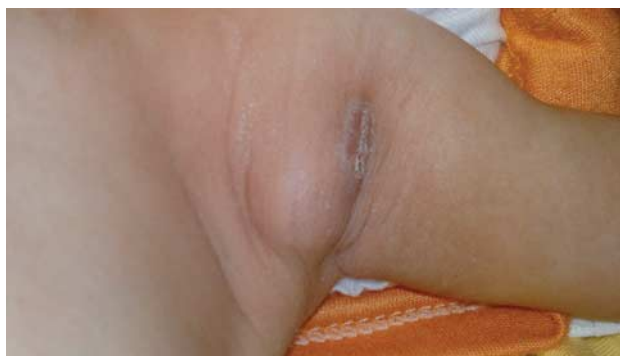Post-Bacillus Calmette-Guérin axillary mass.

Fig. 2



The excised mass.

Fig. 3



Bacillus Calmette-Guérin abscess.

was decontaminated with H₂SO₄ 5%, neutralized with distilled water, and inoculated onto two sets of four media, that is Lowenstein–Jensen (LJ), LJ with sodium pyruvate 0.5% (LJ-P), and selective mycobacterial growth indicator tubes as indicated by the supplier (Becton and

Dickinson Franklin Lakes, NJ, USA) and examined every week for any visible growth. Subcultures were prepared at the end of the sixth week or when any growth was observed. Cultures were identified on the basis of the results from the niacin and thermo stable catalase tests and growth on LJ medium containing *para*-nitrobenzoic acid [15].

Results

Of the 152 patients included, 96 were males and 56 were females (1.7:1) and the mean age was 5.97 months (range 2 months to 2 years) (Table 1). The age distribution for each group is presented in (Table 2). The site of the lesions was the left axilla in 132 patients (86.84%), the left supraclavicular in 10 patients (6.58%), cervical in four patients (2.63%), and left axillary and supraclavicular in six patients (3.95%) (Table 3). An enlarged noninflamed mass was the most common presentation (94 patients, 61.84%) (Table 4).

BCG lymphadenitis regressed spontaneously in four patients of group A (50%), whereas the other four patients showed progressive enlargement of their lymph nodes and developed abscesses that were surgically excised. Twenty-four patients in group B showed an improvement over a period of 6–9 months (27.9%), whereas progressive enlargement (44 cases, 51.2%) and development of BCG abscesses (18 cases, 20.9%) occurred in the rest of the patients who needed surgical treatment. For group C, surgical excision was performed from the start (Table 5).

Pathological examination was performed for all excised lymph nodes (124 cases, 81.6%) and revealed granulomas with extensive caseation necrosis. Microbiological exam-

Table 4 Description of involved lymph nodes at the time of presentation

Lymph node state	Number			%		
Only enlarged mass	94			61.84		
	A=6	B=56	C=32	A=6.4	B=59.6	C=34
Inflamed mass	38			25		
	A=2	B=30	C=6	A=5.3	B=78.9	C=15.8
Abscess	16			10.53		
	A=0	B=0	C=16	A=0	B=0	C=100
Sinus	4			2.63		
	A=0	B=0	C=4	A=0	B=0	C=100
Total	152			100		

ination was performed in all cases and revealed acid fast bacilli in 100 samples (80.6%) that were resistant to INH, pyrazinamide, and streptomycin, but sensitive to rifampicin only in 25 samples (25%); resistance to the four drugs was found in 75 samples (75%) as shown in culture and sensitivity testing (Fig. 4).

From Table 5, we can see that surgical interference was performed for 124 cases (81.6%) (58 in group C and 66 of the complicated cases in groups A and B). No intraoperative complications were reported despite the presence of residual tissue edema and inflammation during surgical dissection; this may be attributed to the superficiality of the lesion under the skin.

The postoperative follow-up period was 4–6 months for the cases that were subjected to surgery (124 patients). During this period, three cases developed abscesses formation and one case developed recurrent sinus. These cases (3.2%) were reoperated on, without further recurrence. Pathological examination of the four specimens revealed tuberculous lesions.

Discussion

The BCG vaccine is a live-attenuated vaccine that is generally well tolerated and free from severe adverse reactions. In immunocompetent individuals, local adverse reactions such as injection site abscess and lymphadenitis occur in less than 1% of vaccinations [16]. However, complications of the BCG vaccine have been well documented. They typically occur when the vaccine strains are changed or, less frequently, when there is an error in manufacture, storage, or administration.

The Pediatric Surgery Department at Red Cross Children's Hospital has observed a significant increase in the number of complications since 2000. The complications were initially minor and attributed to the change in the vaccine strain in that same year [17]; similarly, in our series, we have observed an increase in complicated cases referred to our hospital from different localities after the change from the Danish vaccine to the Indian BCG one (Indian Serum Institute Ltd, Pune, India).

Analysis of all epidemics has revealed that BCG lymphadenitis is an exaggerated response to a more immunogenic strain that was introduced in the immunization schedule [18–20]; this could explain this outbreak of BCG lymphadenitis with the introduction of a new BCG vaccine strain.

Table 1 Demographic data of the studied group

	N (%)
Sex	
Males	96 (63.16)
Females	56 (36.84)
Total	152 (100)
Age (months)	
2–6	98 (64.47)
6–12	46 (30.26)
12–24	8 (5.26)
Total	152 (100)

Table 2 Age distribution of the affected groups

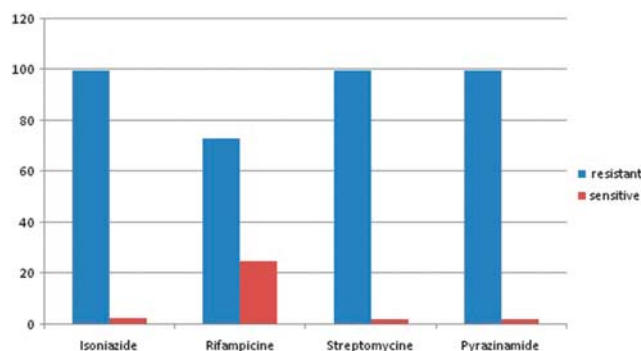
Age (months)	Group A	Group B	Group C
2–6	6	42	50
6–12	1	37	8
12–24	1	7	–

Table 3 Distribution of the involved lymph node groups in the studied patients

Involved lymph nodes groups	N (%)
Left axillary	132 (86.84)
Left supraclavicular	10 (6.58)
Cervical	4 (2.63)
Left axillary and supraclavicular	6 (3.95)
Total	152 (100)

Table 5 The course of *Bacillus Calmette-Guérin* lymphadenitis in the studied groups during 9 months

Group of patients	N (%)	
	Improved	Complicated by significant inflammation or abscess
Group A (8)	4 (50%)	4 (50%)
Group B (86)	24 (27.9%)	62 (72.1%)
Group C (58)	0 (0%)	58 (100%)
Total	28	124

Fig. 4

Results of sensitivity testing for lymph node samples that yielded mycobacterium tuberculosis complex cultures.

Study was carried out to evaluate the course of BCG lymphadenitis occurring during this outbreak and its response to different management strategies as there are no clear evidence-based data for the best treatment of these infants.

BCG lymphadenitis presented at the age of 2–6 months in 64.47% of our patients, although there can be a delay up to 24 months, as found in this study, and the same has been reported by Barouni *et al.* [21]. Several factors such as age of the child, technique of vaccination, the BCG strain, and the dose, potency, viability, and immunogenicity of the vaccine are implicated in the pathogenesis of lymphadenitis [20].

On reviewing the literature, we found that there are different management strategies for BCG lymphadenitis as in the study by Goraya and Virdi [10], who recommended expectant follow-up for nonsuppurative BCG lymphadenopathy, but we observed that only four out of eight patients (group A) who were managed only by regular follow-up showed an improvement, whereas the other four patients were managed surgically.

Other interventions have been used including systemic isoniazid or systemic erythromycin [6]. Responses to 1-month courses of treatment with isoniazid and erythromycin were similar [7]. In 2000, Mark Fitzgerald [22] reported that there was no difference between infants treated with erythromycin, isoniazid, and a combination of isoniazid and rifampicin as rapid development of lymphadenopathy associated with a higher incidence of suppuration and spontaneous drainage was observed irrespective of medical therapy. Similarly, in our study,

only 24 patients out of 86 patients (group B) showed an improvement on antituberculous therapy (27.9%). The rest of the group was managed surgically.

At the time of presentation, patients of group C had either lymph node abscesses (16 patients), sinuses (four patients), or inflamed enlarged lymph nodes approximately 3 cm in size (38 patients); in addition, 62 patients of group B developed the same complications of either abscesses (18 patients) or progressive inflammation and enlargement of the lymph nodes (44 patients). In agreement with our results, Bolger *et al.* [20] reported, in a retrospective study of 58 patients referred to their hospital with BCG lymphadenopathy, that 32 patients developed suppurative adenitis, 17 developed inoculation site abscess, three patients had both inoculation site abscess and suppurative adenitis, and only six had nonsuppurative adenopathy.

Surgical excision of the involved lymph nodes was found to be yield the best results according to Merry and Fitzgerald [23] in a review study that included all cases referred to the pediatric surgical clinic with BCG lymphadenitis over an 11-year period; their results were in agreement with Bhandari *et al.* [24], Hengster *et al.* [19] and also with the results of our series.

Nazir and Qazi [4] reported that out of 60 children who presented with BCG lymphadenitis, 52 who presented with large (~3 cm) fluctuant lymph nodes required a surgical procedure to avoid spontaneous rupture and sinus formation. In our study, 81.6% of our cases finally required a surgical intervention. However, Goraya and Virdi [10] recommended needle aspiration of suppurative BCG lymphadenitis and surgical excision was meant only for cases of failed needle aspiration or for draining BCG nodes. Similarly, Abdulhamed and Hummaida [25] found a 92% success rate with needle aspiration and intake of erythromycin for 4–6 weeks. Also, Paramasivan *et al.* [15] showed no clear benefit of any particular surgical intervention. Their studies question the role of a surgical intervention at all; moreover, complete lymphadenectomy in the acute setting is not a viable option because of a lack of any discernible dissection plane and the risk of damaging vital axillary structures in the presence of an inflamed and distorted anatomy. In our study, and to avoid these surgical catastrophes, the affected child received macrolides 10 days before surgical excision to decrease tissue edema and inflammation and facilitate easy and safe surgical dissection. No intraoperative complications occurred in the operated cases, with an uneventful postoperative course; this may be attributed to the superficiality of the lesion under the skin.

Cultures of excised lymph nodes revealed resistance to isoniazid, pyrazinamide, and streptomycin; however, sensitivity to rifampicin was reported in 25 samples, which could explain the poor response to antituberculous drugs in 62 patients of group B, whereas an improvement was reported in 24 patients. Thus, we were dealing with a multidrug-resistant strain of the BCG vaccine when compared with other strains that were multidrug sensitive such as BCG-Bulgaria (SL 222 Sofia), BCG-Connaught, BCG-Denmark

(SSI 1331), BCG-Japan (Tokyo 17'2), and BCG-Medac (RIVM from 1173-P2). As in our series, Ritz *et al.* [12] and Barouni *et al.* [21] reported that a multidrug-resistant mycobacterial strain was isolated from a 24-month-old child with BCG lymphadenopathy who had received the Brazilian BCG strain.

Conclusion

As antituberculous therapy has been found to be ineffective in the management of BCG lymphadenitis and resistance to isoniazid, rifampicin, pyrazinamide, and streptomycin was detected, we recommend the careful choice of BCG vaccines (to be of appropriate reactogenicity) to avoid multidrug-resistant strains, early surgical excision of lymph nodes larger than 3 cm in size and lymphadenopathy complicated with abscess or sinus formation, and regular follow-up of smaller lymph nodes.

Acknowledgements

Conflicts of interest

There are no conflicts of interest.

References

- Behr MA, Wilson MA, Gill W P, Salamon H, Schoolnik GK, Rane S, Small PM. Comparative genomics of BCG vaccines by whole-genome DNA microarray. *Science* 1999; **284**:1520–1523.
- Ritz N, Hanekom WA, Robins-Browne R, Warwick J, Britton Nigel Curtis. Influence of BCG vaccine strain on the immune response and protection against tuberculosis. *FEMS Microbiol Rev* 2008; **32**:821–841.
- Milstien JB, Gibson JJ. Quality control of BCG vaccine by WHO: a review of factors that may influence vaccine effectiveness and safety. *Bull World Health Organ* 1990; **68**, pp. 93–108.
- Nazir Z Qazi SH. Bacillus Calmette-Guerin (BCG) lymphadenitis – changing trends and management. *J Ayub Med Coll Abbottabad* 2005; **17**:16–18.
- World Health Organization. BCG vaccine. WHO position paper. *Wkly Epidemiol Rec* 2004; **79**:27–38.
- Department of Vaccines and Biologicals. Supplementary information on vaccine safety: part 2: background and rates of adverse events following immunization. In: Clements CJ, editor. Geneva: World Health Organization; 2000.
- Close GC, Nasiiro R. Management of BCG adenitis in infancy. *J Trop Pediatr* 1985; **31**:286–289.
- Murphy PM, Mayers DL, Brock NF, Wagner KF. Cure of Bacilli Calmette-Guerin vaccination abscess with erythromycin. *Rev Infect Dis* 1989; **11**:335–337.
- Hanley SP, Gumb J, Macfarlane JT. Comparison of erythromycin and isoniazid in treatment of adverse reaction to BCG vaccination. *Br Med J* 1985; **290**:970–973.
- Goraya JS, Viridi VS. Bacilli Calmette-Guerin lymphadenitis. *Postgrad Med J* 2002; **78**:327–329.
- Hesseling AC, Rabie H, Marais BJ, Manders M, Lips M, Schaaf HS. Bacille Calmette-Guerin vaccine-induced disease in HIV-infected and HIV-uninfected children. *Clin Infect Dis* 2006; **42**:548–558.
- Ritz N, Tebruegge M, Connell TG, Sievers A, Robins-Browne R, Curtis N, Robins-Browne R and Curtis N: susceptibility of *Mycobacterium bovis* BCG vaccine strains to antituberculous antibiotics. *Antimicrob Agents Chemother* 2009; **53**:316–318.
- Singh G, Singh M. Erythromycin for BCG cold abscess. *Lancet* 1984; **2**:979.
- Hanley SP, Gumb J, MacFarlane JT. Comparison of erythromycin and isoniazid in treatment of adverse reactions to BCG vaccination. *BMJ* 1985; **290**:970.
- Paramasivan CN, Kumar V, Alexander C, Venkatesan P, Somasundaram PR, Prabhakar R. Use of multiple media for the cultivation of mycobacteria from specimens other than sputum. *Ind J Med Res* 1987; **86**:290–294.
- Turnbull FM, McIntyre PB, Achat HM, Wang H, Stapledon R, Gold M, Burgess MA. National study of adverse reactions after vaccination with bacille Calmette-Guérin. *Clin Infect Dis* 2002; **34**:447–453.
- Alexander A, Rode H. Adverse reactions to the Bacillus Calmette-Guerin vaccine in HIV-positive infants. *J Pediatr Surg* 2007; **42**:549–552.
- Praveen KN, Smikle MF, Prabhakar P, Pande D, Johnson B, Ashley D. Outbreak of Bacillus Calmette-Guerin associated lymphadenitis and abscesses in Jamaican children. *Pediatr Infect Dis J* 1990; **9**: 890–893.
- Hengster P, Schnapka J, Fille M, Menardi G. Occurrence of suppurative lymphadenitis after a change of BCG vaccine. *Arch Dis Child* 1992; **67**:952–955.
- Bolger T, O'Connell M, Menon A, Bulter K. Complications associated with the bacille Calmette-Guérin vaccination in Ireland. *Arch Dis Child* 2006; **91**:594–597.
- Barouni AS, Augusto C, Queiroz MV, Lopes MT, Zanini MS, Salas CE. BCG lymphadenopathy detected in a BCG-vaccinated infant. *Braz J Med Biol Res* 2004; **37**:697–700.
- Mark Fitzgerald J. Management of adverse reactions to Bacille Calmette-Guérin vaccine. *Clin Infect Dis* 2000; **31** (Suppl 3):S75–S76.
- Merry C, Fitzgerald J. Regional lymph adenitis following BCG vaccination. *Pediatr Surg Int* 1996; **11**:269–271.
- Bhandari B, Khurana R, Mandowara SL. Management of post-BCG lymphadenitis. *Indian J Pediatr* 1980; **47**:367–370.
- Abdulhameed FD, Hummaida TI. Surgical management of BCG vaccine-induced regional lymph nodes adverse effects. *Annals of Pediatr Surg* 2009; **5**:187–193.