

Laparoscopic repair of Morgagni diaphragmatic hernia in infants and children: do we need to resect the hernia sac?

Taha Alkhatrawi, Radi Elsherbini and Djamal Ouslimane

Purpose Removal of the hernia sac for Morgagni diaphragmatic hernia repair in infants and children is a controversial issue. In our series, we elected not to excise the sac in all the cases.

Methods Nine children with retrosternal (Morgagni) hernias underwent primary laparoscopic repair without excision of the hernia sac, and we analyzed our results, complications, and outcome.

Results Between January 2007 and March 2011, nine children, comprising five boys and four girls, with Morgagni hernia underwent repair laparoscopically at our hospital. The mean age of the children was 15.1 months (range, 3–38 months), mean operative time was 50.5 min, and mean hospital stay was 3.6 days. There were no intraoperative or postoperative complications. The mean follow-up time was 32.8 months (range, 6–54 months). There were no recurrences.

Introduction

Congenital retrosternal diaphragmatic hernia is rare in children. Morgagni hernias account for 1–6% of all surgically corrected diaphragmatic hernias [1,2]. Numerous approaches to their repair have been described over the years, ranging from open procedures to minimally invasive techniques. Excision of the hernia sac has come under debate in the literature.

Methods

Records of all children who underwent laparoscopic repair for Morgagni hernia between January 2007 and January 2011 at our hospital were retrospectively reviewed. Data gathered included age, sex, body weight, clinical presentation, mode of diagnosis, operative details, hospital stay, complications, follow-up, and outcome.

Technique

The child is placed supine with legs extended on abducted leg supports. Younger children are placed in a frog-like position. The table is tilted in reverse Trendelenburg to allow the bowel to move out of the way. The surgeon stands between the legs of the patient. The first 5 mm port is inserted just below the umbilicus by means of an open technique. Pneumoperitoneum is achieved up to 12 mmHg. A 30° 5-mm telescope is inserted through the 5-mm port. Two 3 or 5 mm working ports are inserted into each subcostal lateral to the rectus muscle. Evaluation of the contents, defect, and hernia sac is carried out (Fig. 1). Reduction of the hernia contents and any adhesions are noted. The falciform ligament is divided by electrocautery hook or by vascular sealing device. No

All patients had complete obliteration of the residual cavity.

Conclusion Laparoscopic closure of the defect by suturing the posterior rim of the hernia to the full thickness of the anterior abdominal wall without excision of the hernia sac is safe and effective in repairing Morgagni hernia without any risk accruing from leaving the hernia sac intact. *Ann Pediatr Surg* 8:1–4 © 2012 Annals of Pediatric Surgery.

Annals of Pediatric Surgery 2012, 8:1–4

Keywords: laparoscopic Morgagni hernia repair, Morgagni diaphragmatic hernia, retrosternal diaphragmatic hernia

Department of Pediatric Surgery, Maternity and Children's Hospital, Madinah, Kingdom of Saudi Arabia

Correspondence to Taha Alkhatrawi, Consultant Pediatric Surgeon, Maternity and Children's Hospital, P.O. Box 6147, Madinah, Kingdom of Saudi Arabia
Tel: +966500064079; fax: +96648393025; e-mail: tkhatrawi@yahoo.ca

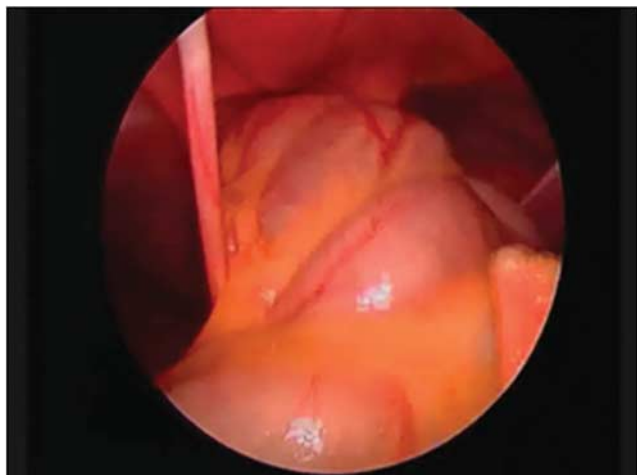
Received 25 September 2011 accepted 16 November 2011

attempt was made to excise the sac in any of the cases. A 1 cm skin incision was made directly over the central portion of the anterior margin of the defect in the epigastric region. Undermining under the subcutaneous tissue all around the skin incision. A 2-0 silk stitch is used for the repair. The first stitch is passed through the abdominal wall through the middle of the posterior edge of the defect using a laparoscopic needle driver and then outside through the abdominal wall with the help of an 18-G intravenous cannulae with 4-0 prolene suture introduced through the abdominal wall; the previous needle is introduced through the loop of the prolene and pulled out. Both ends of the suture are held together on an artery forceps (Fig. 2a). About three sutures are required on each side of the first stitch in the same manner (Fig. 2b). Also in younger children it is possible to directly suture the defect after the first stitch. After applying all the required sutures (Fig. 3), all the untied sutures are pulled up using an artery forceps and the defect closure is tested under direct laparoscopic vision (Fig. 4a and b). All the sutures are tied and subcuticular stitches are applied to the skin.

Results

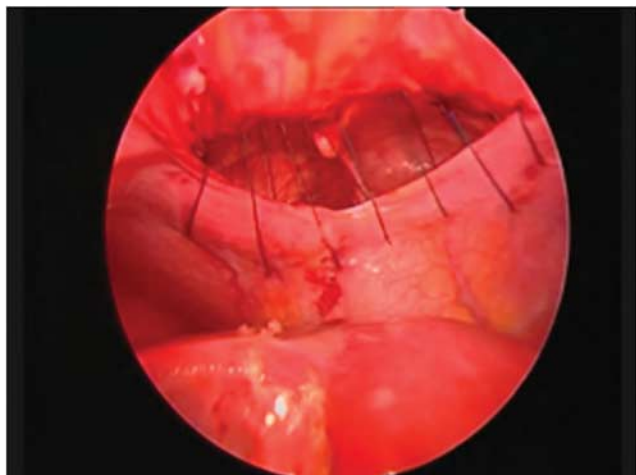
Between January 2007 and January 2011, nine children, comprising five boys and four girls, with Morgagni hernia underwent repair laparoscopically at our hospital. Their mean age was 15.1 months (range, 3–38 months), mean operative time was 50.5 min, and mean hospital stay was 3.6 days. There were no intraoperative or postoperative complications. The mean follow-up time was 32.8 months (range, 6–54 months). Details of age, weight, presentation, diagnosis, operative time, and hospital stay

Fig. 1



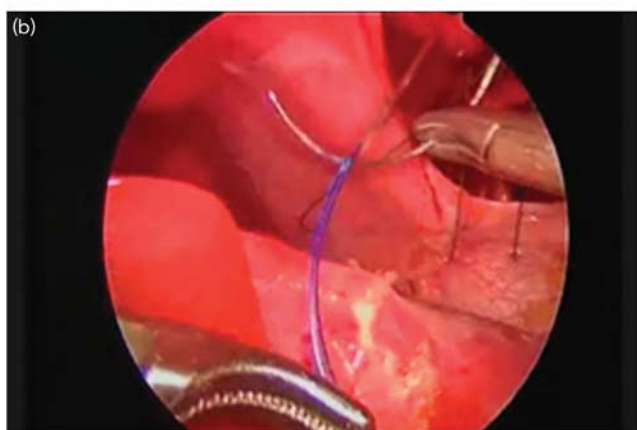
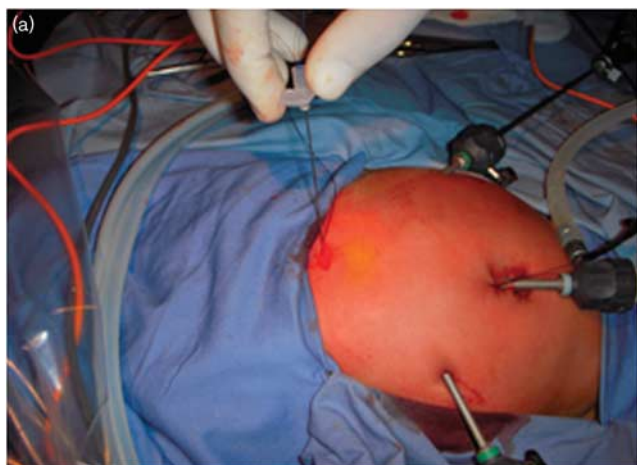
Evaluation of the contents, defect, and hernia sac.

Fig. 3



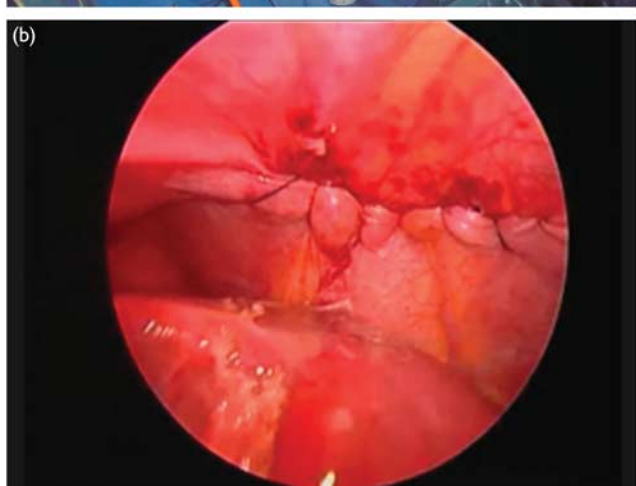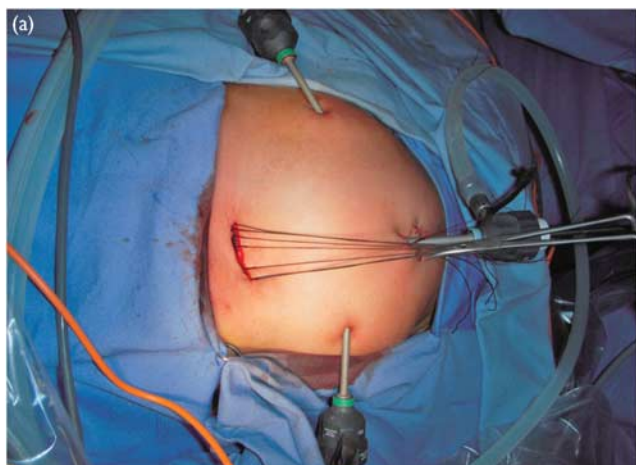
All the required sutures are applied.

Fig. 2



(a) Retrieval of the intra-abdominal needle using an 18-gauge intravenous cannulae with a 4-0 prolene suture introduced through the abdominal wall; (b) the intra-abdominal needle is introduced through the loop of the prolene and pulled out.

Fig. 4



(a) All the untied sutures are pulled up using an artery forceps, and (b) the defect closure is tested under direct laparoscopic vision.

are given in table 1. There were no recurrences. All the patients showed complete obliteration of the residual cavity on the routine chest radiograph follow-up.

Discussion

The Morgagni–Larrey hernia is a retrosternal or anterior diaphragmatic hernia. It is defined as Larrey hernia when

Table 1 Clinical details of nine patients presenting with Morgagni hernia

No	Age (months)	Sex	Weight (kg)	Presentation	Diagnosis	OR time (min)	Discharge (days)
1	23	M	12.3	Recurrent chest infection	Chest radiograph	45	3
2	15	M	13.4	Nonspecific respiratory symptoms	Chest radiograph Barium enema	60	3
3	13	F	10.5	Chest infection	Chest radiograph	50	3
4	24	M	15.7	Chest infection	Chest radiograph	40	3
5	9	F	9	Asthma-like symptoms	Chest radiograph CT-scan	45	3
6	7	M	8	Chest infection	Chest radiograph	40	3
7	4	M	5.3	Recurrent chest infection	Chest radiograph Barium enema	80	7
8	38	F	21	Recurrent chest infection	Chest radiograph CT-scan	45	3
9	3	F	4	Chest infection with Down's syndrome	Chest radiograph	50	5

F, females; M, males; OR, operative room.

located on the left of the sternum or as Morgagni hernia when located on the right of the sternum [3]. If the opening is wide enough that it includes both hiatus, the defect is called Morgagni–Larrey hernia. The herniation usually occurs to the right because of the presence of the heart and pericardial attachment on the left side. A hernia sac is found in 95% of the cases [4]. Very rarely there is no sac present, in which case the defect extends into the pericardial space. Such defects are usually part of the pentalogy of Cantrell [5].

Patients are usually asymptomatic and cases are discovered incidentally from a chest or an abdominal radiograph undertaken for unrelated reasons [6]. More rarely patients may present with respiratory symptoms, strangulation, and perforation of abdominal viscera, gastric volvulus, or cardiac tamponade [7]. In our series, all the patients had symptoms not related to their retrosternal hernia (Table 1). These patients were diagnosed by the pediatrician who referred them to us. Diagnosis is usually made by incidental radiologic investigation, in which an anteroposterior and lateral radiograph of the chest shows a right paracardiac mass [8]. In difficult cases or in doubtful cases, Barium enema, computed tomography scan, and MRI may be required, like in our series, although this is not always necessary. Barium enema can confirm the presence of a herniation of the abdominal viscera. Computed tomography scan and MRI provide further information regarding the relationship between the hernia and the adjacent abdominal organ and about the contents of the sac (which is usually the transverse colon and the omentum) and can allow three-dimensional reconstruction of the diaphragmatic defect [9]. Although the diagnosis is frequently obvious, a Morgagni hernia can be misdiagnosed as congenital lobar emphysema, cystic adenomatoid malformation of the lung, pneumothorax, anterior mediastinal mass, or lung abscess secondary to a staphylococcal pneumonia [10,11].

Surgical correction is recommended in all cases of Morgagni hernia to avoid the risk of bowel strangulation, even though it is rare [12,13]. In a Morgagni hernia the retrosternal rim of the diaphragm is frequently absent, and a simple suture technique is usually not possible. Suturing of the diaphragmatic hernial margin to the peritoneum or periosteum behind the sternum is difficult and not very solid, particularly with the laparoscopic approach [14]. Morgagni hernias have been treated traditionally by laparotomy or by thoracotomy with

inherited longer postoperative recovery and considerable morbidity.

Georgacopulo *et al.* [15] reported the first successful laparoscopic repair of Morgagni hernia in a child. In recent years, there have been various reports of repair using minimal access surgical techniques in children. The methods have included primary intracorporeal sutured repair [16], full-thickness anterior abdominal wall repair using a Keith needle and multiple skin incisions [17], mesh repair [15], or laparoscopic full-thickness anterior abdominal wall repair [18]. The defect itself may be closed either by primary sutured closure, primary placement of a mesh, or by a combination of both [18,19]. In our series, we performed laparoscopic repair of Morgagni hernia using the full thickness of the anterior abdominal wall, with extracorporeal knot tying in the subcutaneous tissue without the need of a mesh in all the cases.

Removal of the hernia sac for Morgagni hernia repair in children is a controversial issue in the literature. The debate includes three groups of authors. The first group recommend not to excise the sac [4,5,7,8,14,20], the second group recommend removal [2,21–23], and the third group recommend removal of the sac when it can be safely carried out [3,18]. Mallick and Alqahtani [20] reported 15 children with Morgagni hernia treated laparoscopically with no attempt to excise the sac but with complete obliteration of the residual cavity in all the cases with no recurrences. Anđelka *et al.* [22] recommend excision of the hernia sac to avoid leaving a loculated space-occupying lesion in the chest that might result in recurrence or mesothelium-lined cyst formation. Georges Azzie *et al.* [18] prefer to excise the sac when it can be done safely. In one of their four cases of laparoscopic repair, an attempt to excise the hernia sac resulted in cardiac arrhythmia and therefore it was left *in situ*.

In our nine cases, we chose not to excise the hernia sac as we believed that there was no need for excision. Further, there is a risk of injury to the phrenic nerve, pleura, and pericardium that might be associated with sac excision. In addition, sac excision is demanding and will prolong operative time unnecessarily. We did not encounter a fluid-filled retention cyst as a result of leaving a loculated space-occupying lesion in the chest in any of our cases, nor did we observe such an outcome in other author reports [4,5,7,14,19,20,24]. Follow-up radiographs showed complete obliteration of the residual cavity in all our

cases. Obliteration of the residual cavity has been reported by other authors as well [19,20,24]. In our series, there were no short-term or long-term complications or consequences on leaving the hernia sac intact.

Conclusion

Laparoscopic closure of the defect by suturing the posterior rim of the hernia to the full thickness of the anterior abdominal wall without excision of the hernia sac is safe and effective in repairing Morgagni hernia without any risk occurring from leaving the hernia sac behind.

This technique for primary laparoscopic repair of Morgagni hernia is easy to perform, well tolerated by the patient, and gives excellent cosmetic results.

Acknowledgements

Conflicts of interest

There are no conflicts of interest.

References

- Contini S, Dalla Valle R, Bonati L, Zinicola R. Laparoscopic repair of a morgagni hernia: report of a case and review of the literature. *J Laparoendosc Adv Surg Tech A* 1999; **9**:93–99.
- Fernandez Cebrian JM, De Oteyza JP. Laparoscopic repair of hernia of foramen of Morgagni: a new case report. *J Laparoendosc Surg* 1996; **6**:61–64.
- Becmeur F, Philippe P, Van der Zee D, Bax NMA, Allal H, Reinberg O, et al. Laparoscopic surgery of Morgagni-Larrey hernias: a multicenter study of the Groupe d'Étude en Coelochirurgie Infantile (GECI). *Pediatr Endosurg Innovat Tech* 2003; **7**:147–152.
- Akbiyik F, Tiryaki TH, Şenel E, Mambet E, Livanelio-lu Z, Atayurt H. Is hernial sac removal necessary? Retrospective evaluation of eight patients with Morgagni hernia in 5 years. *Pediatr Surg Int* 2006; **22**:825–827.
- Lima M, Dòmini M, Aquino A. Laparoscopic treatment of Morgagni-Larrey diaphragmatic hernia. In: Lima M, Dòmini M, Aquino A, editors. *Endoscopic surgery in infants and children*. 2008. pp. 558–561.
- De Vogelaere K, de Backer A, Delvaux G. Laparoscopic repair of diaphragmatic Morgagni hernia. *J Laparoendosc Adv Surg Tech A* 2002; **12**:457–460.
- Papia G, Gerstle JT, Langer JC. Laparoscopic repair of Morgagni diaphragmatic hernia in children: technical challenges and results. *Pediatr Endosurg Innovat Tech* 2004; **8**:245–249.
- Percivale A, Stella M, Durante V, Dogliotti L, Serafini G, Saccomani G, et al. Laparoscopic treatment of Morgagni-Larrey hernia: technical details and report of a series. *J Laparoendosc Adv Surg Tech A* 2005; **15**:303–307.
- Yildirim B, Ozaras R, Tahan V, Artis T. Diaphragmatic Morgagni hernia in adulthood: correct preoperative diagnosis is possible with newer imaging techniques. *Acta Chir Belg* 2000; **1**:31–33.
- Booker PD, Meerstadt PWD, Bush GH. Congenital diaphragmatic hernia in the older child. *Arch Dis Child* 1981; **56**:253–257.
- Paierolo PC, Trastek VF, Payne WS. Esophagus and diaphragmatic hernias. In: Schwartz SI, editor. *Principles of surgery*. 1989 New York: McGrawHill. pp. 1118–1132.
- Kimmelstiel FM, Holgersen LO, Hilfer C. Retrosternal (Morgagni) hernia with small bowel obstruction secondary to a Richter's incarceration. *J Pediatr Surg* 1987; **22**:998–1000.
- Al Salem AH. Congenital hernia of Morgagni in infants and children. *J Pediatr Surg* 2007; **42**:1539–1543.
- Van De Winkel N, De Vogelaere K, De Backer A, Delvaux G. Laparoscopic repair of diaphragmatic Morgagni hernia in children: review of 3 cases. *J Pediatr Surg* 2011; **46**:E23–E26.
- Georgacopulo P, Franchella A, Mandrioli G, Stancanelli V, Perucci A. Morgagni-Larrey hernia correction by laparoscopic surgery. *Eur J Pediatr Surg* 1997; **7**:241–242.
- Lima M, Dòmini M, Libri M, Morabito A, Tani G, Dòmini R. Laparoscopic repair of Morgagni-Larrey hernia in a child. *J Pediatr Surg* 2000; **35**:1266–1268.
- Van der Zee DC, Bax NMA, Valla JS. Laparoscopic repair of diaphragmatic conditions in infants and children. In: Bax NMA, Georgesson GE, Najmaldin AS, editors. *Endoscopic surgery in children*. 1999 New York, NY: Springer. pp. 327–328.
- Azzie G, Maoate K, Beasley S, Retief W, Bensoussan A. A simple technique of laparoscopic full-thickness anterior abdominal wall repair of retrosternal (Morgagni) hernias. *J Pediatr Surg* 2003; **38**:768–770.
- Korkmaz M, Güvenç BH, Senel U. Minimal access surgical repair of Morgagni hernia: the fate of the unresected hernia sac. *J Laparoendosc Adv Surg Tech* 2007; **17**:833–836.
- Mallick MS, Alqahtani A. Laparoscopic-assisted repair of Morgagni hernia in children. *J Pediatr Surg* 2009; **44**:1621–1624.
- Rau HG, Schardey HM, Lange V. Laparoscopic repair of a Morgagni hernia. *Surg Endosc* 1994; **8**:1439–1442.
- Andelka S, Zoran M, Ivona D, Zorica J, Ivana B. Congenital herniation through the foramen Morgagni – clinical presentation, diagnosis and treatment in pediatric population. *Cent Eur J Med* 2011; **6**:131–135.
- Jetley NK, Al Assiri AH, Al Helal AS, Al Bin Ali AM. Down's syndrome as a factor in the diagnosis, management and outcome in patients of Morgagni hernia. *J Pediatr Surg* 2011; **46**:636–639.
- Del Castillo D, Sanchez J, Hernandez M, Sanchez A, Domenech J, Jara J. Morgagni's hernia resolved by laparoscopic surgery. *J Laparoendosc Adv Surg Tech A* 1998; **8**:105–108.