



## Case Report

*Annals of Pediatric Surgery*  
Vol. 6, No 1, January 2010, PP 41-43

# Anterior Abdominal Wall Desmoids Tumor in a Five Year Old Girl – A Pre Operative Diagnostic Challenge in Resource-Poor Setting

Ademuyiwa A.O, Bode C O, Elebute O A

*Pediatric Surgery Unit, Department of Surgery, Lagos University Teaching Hospital, Idi Araba, Lagos*

### ABSTRACT:

*Desmoid tumors are rare, slow – growing, mesenchymal monoclinic proliferation. It may occur as intra-abdominal tumor usually affecting the mesentery of the intestine or it could be extra-abdominal in which they may affect the popliteal region, the chest wall or the anterior abdominal wall. Reports in children less than 10 years is rare. Here, we report a 5 year old girl with anterior abdominal wall desmoid that was managed in our unit and challenges at reaching a diagnosis are highlighted.*

*Index Word: Desmoid tumor, Diagnosis, Pediatric age groups.*

### INTRODUCTION

Desmoid tumors are rare, slow – growing, mesenchymal monoclinic proliferation<sup>1</sup>. It may occur as intra-abdominal tumor usually affecting the mesentery of the intestine or it could be extra-abdominal in which they may affect the popliteal region, the chest wall or the anterior abdominal wall<sup>2-4</sup>. Anterior abdominal wall desmoids sometimes occur with Familial adenomatous polyposis syndrome<sup>5</sup>. Reports in children less than 10 years is rare; in a large series of 106 patients<sup>2</sup>, only 4 were below 16 years and all of them were above 12 years. This is a report of a 5 year old girl with anterior abdominal wall desmoid that was managed in our unit and challenges at reaching a diagnosis are highlighted.

having some discomfort from the mass with change of position 5 months before presentation. There was no history of trauma prior to the time mass was noticed by the parents. No associated history of nausea, vomiting, progressive abdominal distention, intermittent cries or constipation. There was also no history of weight loss, fever or swelling in other parts of the body. Parents decided to seek medical attention on account of abdominal discomfort. Two previous abdomino-pelvic ultrasound scans showed different conclusions: one was lipoma while the other was gastrointestinal stromal tumor.

The pregnancy, birth and neonatal history was uneventful and she completed the National Programme on Immunization schedule for her age. No prior history of hospitalization or surgery. The developmental milestones were within normal limits.

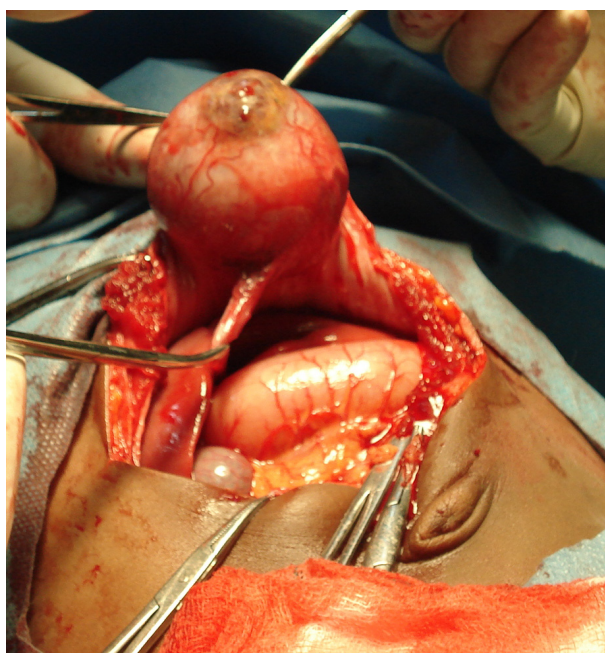
Examination at presentation showed a pleasant well fed young girl, not pale, anicteric, afebrile and well hydrated. Examination of the central nervous system, the chest, cardiovascular and musculoskeletal systems revealed normal findings

### CASE REPORT

A 5 year old girl presented with a 2 year history of progressively increasing supra-umbilical mass. The mass was initially painless but the patient started

The abdomen was full, moves with respiration and there were no areas of tenderness. There was a supraumbilical mass measuring about 6 cm in diameter, spherical in shape with well defined edges. The mass was not warm, not tender, firm in consistency and was not attached to skin but attached to underlying structures. Carnett's sign was demonstrated with the mass less prominent when the anterior abdominal wall muscles are tensed. Rectal examination was essentially normal.

An assessment of subcutaneous lipoma to rule out mesenteric cyst with soft tissue sarcoma as a differential was made and patient was worked up for excisional biopsy.



**Fig 1: shows the tumor which is attached to the posterior rectus sheath. Note the stomach and liver appear grossly normal**

Findings at surgery were that of a well encapsulated, firm, spherical shaped mass measuring 6 cm in diameter, attached to the posterior rectus sheath and the inferior limit is about 5 cm from the umbilicus. The mass had areas of necrosis within it. The stomach and other intraperitoneal organs were grossly normal and no ascites was found.

Patient had a wide excision of the mass (Fig.1) with about 1-2cm margin. Histopathology of the excised tissue show low grade sarcoma (desmoid tumour).

Patient is being seen in the paediatric surgical outpatient clinic and she is presently doing well. She is 12 weeks post operative.

## DISCUSSION

Desmoid tumors are typically slowly growing mesenchymal tissue; however, they may infiltrate tissue planes<sup>1</sup> hence the need for adequate excision margin. They often occur in the second or third decade of life but some series have documented desmoid tumors in the middle aged and elderly.<sup>2</sup> Anterior abdominal wall desmoid tumors are sometimes associated with familial adenomatous polyposis<sup>5</sup>. Occurrence of desmoid tumor in the first decade of life is very rare, our index patient has an anterior abdominal wall desmoid tumor however, and there is no family history of adenomatous polyposis.

Our patient had noticed the anterior abdominal mass for about 2 years without symptoms and the size had only increased moderately showing the slow growing nature of the tumor. Preoperative diagnosis of the tumor was difficult in our setting because of the prohibitive cost of procuring a computerized tomographic scan even though it is available in our center. The abdominopelvic ultrasound scans (USS) – which are cheap, non invasive with no risk of irradiation – were more readily available and was requested. Two scans were performed; one from the referring center and the other was done in our center. The conclusions were conflicting: the first concluded it was a subcutaneous lipoma while the second suggested it was a gastrointestinal stromal tumor. Physical examination of the mass (Carnett's sign) suggested that it was probably an intraperitoneal or subfascial mass. Due to the rarity of this tumor, it was low in the differential diagnosis with a mesenteric cyst or a subfascial lipoma high on the differential.

At surgery, a well circumscribed tumor mass attached to the inner layer of the rectus abdominis muscle was found (fig 1) and this was excised completely with about 1cm tumor margin. In children, negative margin of resection significantly reduces the

recurrence of tumor<sup>6</sup> however, this is not so in adults where it has been reported that recurrence can occur in tumor free margin.<sup>7</sup> Adjuvant radiotherapy or chemotherapy was not considered due to the benign nature of the tumor and the age of our patient

### CONCLUSION

While anterior abdominal wall desmoid tumors are rare, a high index of suspicion is necessary for accurate diagnosis in a slow growing tumor of this nature and wide excisional biopsy is advocated, at least in children. Comprehensive preoperative imaging technique including computerized tomography will enhance preoperative diagnosis. A long follow up is necessary to pick any recurrence early.

### REFERENCES

1. Melis M. Zager JS. Sondak VK. Multimodality management of desmoid tumors: how important is a negative surgical margin? *J Surg Oncol.* 98(8):594-602, 2008

2. Stoeckle E. Coindre JM. Longy M. Binh MB. Kantor G. Kind M. de Lara CT. Avril A. Bonichon F. Bui BN. A critical analysis of treatment strategies in desmoid tumours: a review of a series of 106 cases. *Eur J Surg Oncol* 35:129-34, 2009

3. Shiu MH. Flancbaum L. Hajdu SI. Fortner JG. Malignant soft-tissue tumors of the anterior abdominal wall. *Arch Surg* 115:152-5, 1980

4. Tsuchishima S. Nishizawa H. Matsumoto Y. Kitagawa S. Shimizu T. Yuasa K. A desmoid tumor of the chest wall. *Kyobu Geka* 51:1055-9, 1998

5. Clark SK. Phillips RKS. Desmoids in familial adenomatous polyposis. *Br J Surg* 83: 1494-1504, 1996

6. Faulkner LB. Hajdu SI. Kher U. et al. Pediatric desmoid tumor: Retrospective analysis of 63 cases. *J Clin Oncol* 13:2813-2818, 1995

7. Merchant NB. Lewis JJ. Woodruff JM. et al. Extremity and trunk desmoid tumors: A multifactorial analysis of outcome. *Cancer* 86: 2045-2052, 1999