

Anastomosis Procedure through an Inguinal Hernia Incision in Simultaneous Laparoscopic Anterior Resection and Inguinal Hernia Repair

Toshimasa Suzuki, Hidejiro Kawahara¹, Naoko Iida, Masaru Naruse, Takeyuki Misawa¹, Katsuhiko Yanaga¹

Department of Surgery, Sakuragaoka General Hospital, Shizuoka, ¹Jikei University School of Medicine, Tokyo, Japan

INTRODUCTION

For laparoscopic anterior resection, an additional small incision is usually made in the left lower quadrant or the suprapubic portion. As a left inguinal hernia incision is close to both the left lower quadrant and the suprapubic portion, such an incision can be used for reconstruction in laparoscopic anterior resection without any additional incisions, provided the risk of the surgical site infection is not increased. We report a patient who underwent laparoscopic anterior resection with colorectal anastomosis through a left inguinal hernia incision, for concomitant left inguinal herniorrhaphy.

CASE REPORT

A 65-year-old male with a left inguinal hernia was referred to our institution for the treatment of T3 upper rectal carcinoma. The patient was placed in the modified lithotomy position, and two trocars, 12 mm in diameter, were inserted into the abdominal cavity, one supraumbilically and the other in the lower-right quadrant of the abdomen. Three other trocars, 5 mm in diameter, were also inserted through stab incisions in the upper- and lower-left quadrants of the abdomen, as

ABSTRACT

For laparoscopic anterior resection, an additional small incision is usually placed in the left lower quadrant or the suprapubic portion. As a left inguinal hernia incision is close to both the left lower quadrant and the suprapubic portion, such an incision can be used for anastomosis in laparoscopic anterior resection, without additional incisions. We report a laparoscopic anterior resection using a left inguinal hernia incision for colorectal anastomosis, in a patient who underwent concomitant left inguinal hernia repair. After a total mesorectal excision was performed laparoscopically, the distal portion of the rectum was transected by a stapler. A 4 cm skin incision was made in the left inguinal region and carried down to the peritoneum through the hernia sac. The bowel resection was performed extracorporeally, and an anvil was placed at the proximal end of the colon over a purse-string suture. After colorectal anastomosis was performed using a circular stapler inserted through the anus, the inguinal hernia was repaired with a mesh. The inguinal wound healed without surgical site infection, and the patient was discharged ten days after surgery.

Key words: Inguinal hernia, laparoscopic anterior resection, surgical incision

well as, in the upper-right quadrant, respectively. Thus, a total of five trocars were used. The superior rectal artery (SRA) was lifted up ventrally and the medial mesenteric attachments were incised. The superior hypogastric nerve plexus was preserved and separated dorsally from the SRA. Dissection was extended from the dorsal SRA to the left lateral attachment of the sigmoid colon. The mesorectum was separated along the plane of total mesorectal excision^[1,2] and extended to the levator muscles. The distal line in the rectum was laparoscopically transected by a stapler. A 4 cm skin incision was then made in the left inguinal region and carried down to the peritoneum through the hernia sac [Figure 1]. Bowel resection was performed extracorporeally, and an anvil was placed at the proximal end of the colon, over a purse-string suture [Figure 2]. After the hernia sac was closed with a Kelly forceps, pneumoperitoneum was re-established [Figure 3]. Colorectal anastomosis was performed using a circular stapler inserted through the anus. The

Access this article online

Quick Response Code:



Website:

www.jstcr.org

DOI:

10.4103/2006-8808.78468

Address for correspondence: Dr. Hidejiro Kawahara, Department of Surgery, Jikei University School of Medicine, 3-25-8 Nishi-Shinbashi, Minatoku, Tokyo 105-8461, Japan. E-mail: kawahide@jikei.ac.jp

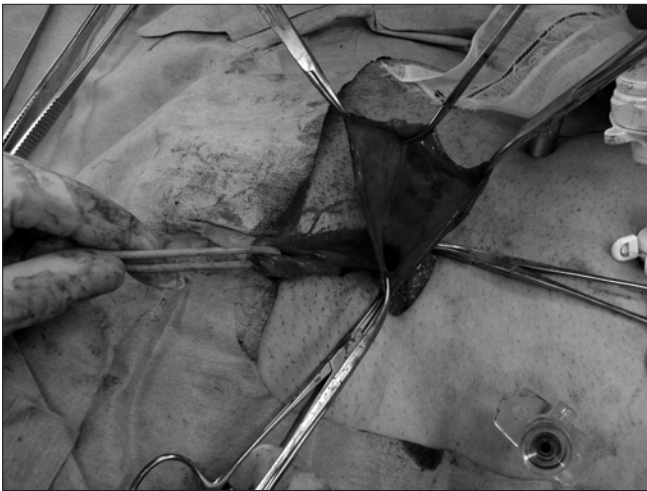


Figure 1: A 4 cm skin incision was made in the left inguinal region and carried down to the peritoneum to open the hernia sac

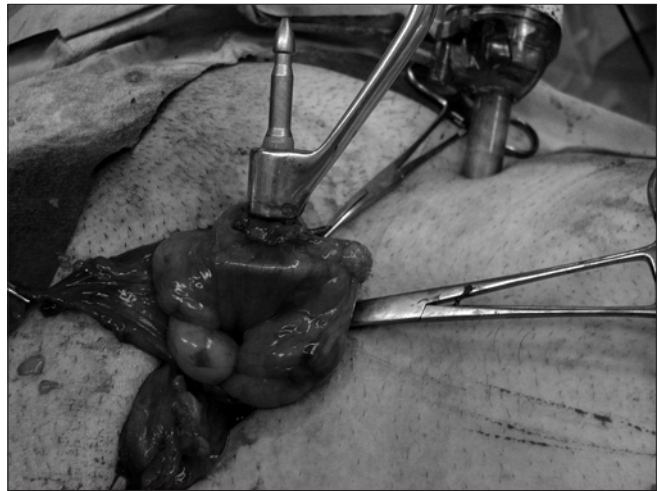


Figure 2: The bowel resection was performed extracorporeally through the hernia sac, and an anvil was placed in the proximal end of the colon over a purse-string suture

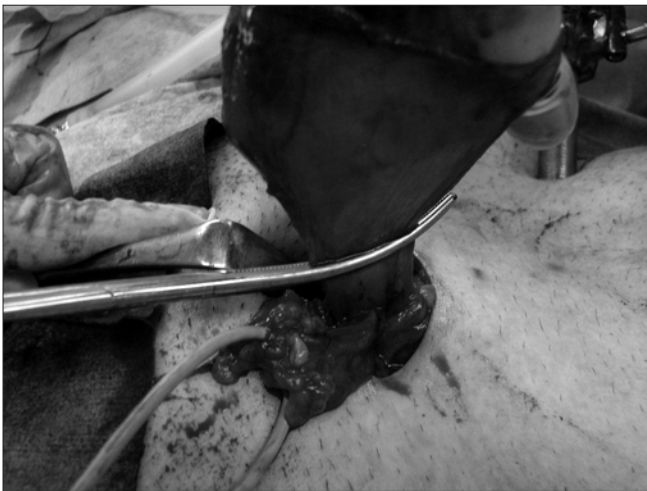

Figure 3: After the hernia sac was clamped with Kelly forceps, pneumoperitoneum was re-established

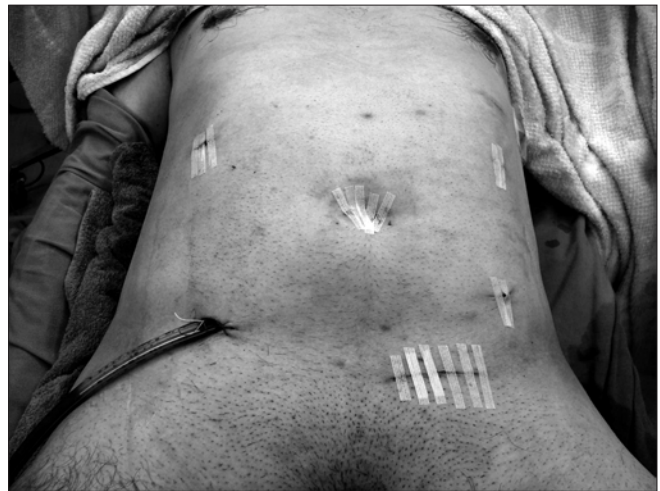

Figure 4: At the end of the operation, the patient had only a hernia repair wound and five trocar wounds

wound was irrigated with a copious amount of saline. Thereafter, the hernia sac was ligated in the neck and the inguinal hernia was repaired with a mesh [Figure 4]. His postoperative course was uneventful without surgical site infection, and he was discharged ten days after the operation.

DISCUSSION

We had reported the validity of anthropometric placement of an incision in laparoscopic anterior resection, for transection of the rectum and colorectal anastomosis, in which the superiority of the suprapubic incision was demonstrated as compared to a left lower abdominal incision.^[3] However, for patients with left inguinal hernia, such an incision could be placed in the left inguinal region rather than in other areas. By

doing so, both procedures, inguinal hernia repair and laparoscopic anterior resection could be performed through the same incision, provided the risk of surgical site infection of the inguinal wound was not increased. In this procedure, the pneumoperitoneum for colorectal anastomosis was re-established by closing the hernia sac rather than by the regular procedure, using the Lap protector (Hakko Medical, Hyogo, Japan) covered with a surgical glove.^[4] It was an easy and safe procedure.

As for the technique for inguinal hernia repair, anatomical repair would minimize the chance of surgical site infection. In the current case, however, contamination was minimized by maximal care for wound contamination. In this particular case, we used tension-free repair with a mesh plug, and did not

perform laparoscopic transabdominal preperitoneal repair (TAPP), because we could not sufficiently irrigate the place replaced with mesh in the procedure by using laparoscopic TAPP, and the risk of infection at the site would be high after the surgery. In fact, few reports have been published on bowel-related mesh or bowel complication after transabdominal preperitoneal hernioplasty.^[5] Postoperative mesh infection could be avoided by preventive methods, such as careful hemostasis, asepsis, conscientious dissection, and good hemostasis, to reduce the likelihood of hematoma and seroma formation.^[6] In addition, proper preperitoneal dissection reduces the risks of inadvertent peritoneal cavity violation and of failure to close the peritoneal opening of the hernia sac.

In our procedure, even if contamination occurred at the hernia sac, it would be only on the inside of it. As the hernia sac was ligated and divided after the irrigation with a copious amount of saline, the risk of contamination at the place replaced with mesh would

be extremely low. The mesh infection was not actually encountered.

REFERENCES

1. Heald RJ, Husband EM, Ryall RD. The mesorectum in rectal cancer surgery: The clue to pelvic recurrence? *Br J Surg* 1982;67:757-61.
2. Enker WE. Potency, cure and local control in the operative treatment of rectal cancer. *Arch Surg* 1992;127:1396-402.
3. Kawahara H, Kobayashi T, Watanabe K, Kobayashi S, Kashiwagi H, Yanaga K. Where is the best surgical incision for laparoscopic anterior resection? *Hepatogastroenterol* 2009;56:1629-32.
4. Ichihara T, Takada M, Fukumoto S, Yasuda T, Kuroda Y. A novel technique of finger-assisted laparoscopic surgery. *Am J Surg* 2004;187:285-7.
5. Tamme C, Scheidbach H, Hampe C, Schneider C, Kockerling F. Totally extraperitoneal endoscopic inguinal hernia repair (TEP) - results of 5,203 hernia repairs. *Surg Endosc* 2003;17:190-5.
6. Han HJ, Kim CY, Choi SB, Kwak JM, Lee SI. Sigmoid colon fistula following totally extraperitoneal hernioplasty: An improper treatment for mesh infection or iatrogenic injury? *Hernia* 2010;14:655-8.

How to cite this article: Suzuki T, Kawahara H, Iida N, Naruse M, Misawa T, Yanaga K. Anastomosis procedure through an inguinal hernia incision in simultaneous laparoscopic anterior resection and inguinal hernia repair. *J Surg Tech Case Report* 2011;3:31-3.

Source of Support: Nil, **Conflict of Interest:** None declared.