

## TUBERCULOSIS OF THE BREAST: A CASE REPORT

<sup>1</sup>ADEJUMO A.A<sup>1</sup> (FMCS), <sup>1</sup>ADEOSUN A (FWACS, FICS), <sup>1</sup> OMOREGIE O.P (FWACS), <sup>2</sup> Garba Y (FMC Path), <sup>3</sup>OLUWOLE O.P. (FMC Path)

1. Department of Surgery, Federal Medical Centre, Keffi, Nasarrawa State, Nigeria.
2. Department of Histopathology, Federal Medical Centre, Keffi.
3. Department of Histopathology and Morbid Anatomy, University of Abuja Teaching Hospital, Gwagwalada, FCT.

### Corresponding Author:

**Dr ADEJUMO, Adeyinka Ayodele,**

P. O. Box 324, Gwagwalada, Abuja. FCT. Email: [dradejumooa@gmail.com](mailto:dradejumooa@gmail.com)

Phone: +234 703 770 0349.

### ABSTRACT

*Tuberculosis of the breast is a rare disease. It is often misdiagnosed because it exhibits features that mimic a carcinoma both clinically and radiologically. This in the past has led to unnecessary mastectomies. The objective is to report a patient who presented with left breast mass and ipsilateral axillary swellings that was confirmed to be tuberculosis. The index patient is a 20- year old female who presented with left breast mass predated by ipsilateral axillary swellings of 7 weeks duration prior to presentation. Excision biopsy of both the breast mass and axillary swellings revealed tuberculous mastitis. She was commenced on anti-tuberculous treatment with significant improvement. With a high index of suspicion, a diagnosis will be established. It is therefore advised that surgeons should always think of this disease entity as a differential diagnosis when dealing with breast masses.*

**Keywords:** Tuberculosis, Breast, Histopathology

### Introduction.

Tuberculosis is a disease entity that affect many organs and systems in the body, the commonest being the lungs. <sup>[1]</sup> Other systems that could be affected include the brain, bones, spine and lymph nodes. <sup>[1]</sup> However, organs like the spleen and the skeletal muscles are rarely affected. <sup>[2]</sup> Though an uncommon disease entity, tuberculosis of the breast (tuberculous mastitis) just like other breast pathologies usually present with breast lumps. <sup>[3]</sup> These lumps at time exhibit features closely resembling that of a malignant breast disease. <sup>[2,3]</sup> This makes it imperative therefore for surgeons practicing in the tropics to always consider it as a differential diagnosis of breast lumps.

### Case report.

UH is a 20 year old female post-secondary school student. She presented to the surgical out-

patient clinic with a progressive history of left axillary lumps as well as left breast lump. She was apparently well until seven weeks prior to presentation when she noticed multiple lumps in her left axilla. These lumps were initially the size of 'orange seeds' and progressively increased to the size of the distal phalanx of her little finger. There was associated pain. Four weeks later, she noticed a painful mass in the upper part of her left breast that was progressively increasing in size. There were no associated skin changes over the breast mass, no nipple discharge, no jaundice or neck swellings and no history of cough. However, there was a history of weight loss and consumption of unpasteurized milk. No previous history of breast disease in the patients and no family history of breast cancers

Examination revealed a young lady, ill-looking, not pale and afebrile. Vital signs were all stable. Breast examination revealed a mass in the left breast measuring about 6x8cm located in the upper and lower outer quadrants. The mass has well

defined margins, rough surface, tender and no attachment to the overlying skin and the pectoralis muscle. Nipple-areolar complex was normal. Left axilla was full with presence of tender, matted lymph nodes. However, there was no skin involvement. The right breast and axilla were essentially normal. No ascitis, liver and spleen were not palpably enlarged and chest was clinically clear.

Breast sonography done was inconclusive. Chest x-ray was normal Full blood count revealed Hb 10.6g/dl, WBC  $6.7 \times 10^9/l$ , ESR 27mm/hr. retroviral and hepatitis screening were non-reactive. Trucut biopsy done was inconclusive and patient eventually had an excision biopsy of both the breast and accompanied axillary masses were sent for histopathological analysis.

**Histopathology:** Received two specimens in the same container, one is tagged (breast mass) with silk suture, while the second tissue was not tagged. The tagged tissue firm grey tissue measure 5.5x3.3x1.5cm and weighs 20g. The axillary mass measure 4.6x3.5x2.9cm and weighs 15g. Their cut sections show grey appearance with extensive areas of caseous necrosis.

Sections from both specimens are the same; they both show total effacement of the nodal and breast lobular architecture by extensive caseous necrosis and multiple granulomata. The granuloma is composed of epithelioid cells, Langhans and foreign body giant cells surrounded by a rim of lymphocytes, plasma cells, young fibroblasts and extensive hyalinized fibrocollagenized tissue. Other areas show residual lymphoid and breast tissues with thrombosed vascular channels, haemorrhage and fibrin. The diagnosis is consistent with tuberculous mastitis and adenitis. She was referred to the infectious disease specialist to commence anti-tuberculous therapy (ATT); to be seen in follow up clinic.

### Discussion

Tuberculosis is a disease that often affects the pulmonary system as well as other regions of the body.<sup>[1]</sup> The causative organism is *Mycobacterium tuberculosis*.<sup>[1]</sup> Tuberculosis of the breast (tuberculous mastitis) is a rare entity and accounts for 0.1-3% of all breast diseases. This incidence is however expected to increase because of the endemicity of retroviral disease.<sup>[3]</sup> The breast is a rare site of involvement because of non-availability of conducive factors necessary for the growth and

multiplication of the organism.<sup>[4]</sup>

Tuberculous mastitis is not a new disease as it has been reported over two centuries ago by Astley Cooper when he described it as scrofulous disease of the bossom.<sup>[3]</sup> It usually presents as breast lump and this may mimic other breast lesions like fibroadenoma, fibroadenosis or carcinoma thereby causing a diagnostic conundrum.<sup>[3, 5]</sup> However, unlike carcinoma of the breast, it often associated with pain.<sup>[2]</sup> It could be secondary to a previous tuberculous lesion present elsewhere in the body and it could also arise primarily in the breast although; this is not too common.<sup>[3]</sup>

Tuberculous mastitis has been found to affect predominantly women between the ages of 20 and 40years.<sup>[2]</sup> Our patient fell into this age bracket in which benign breast lesions such as fibroadenoma are commonly seen. The presentation of pain with the breast lumps in the index patient raised the suspicion of an on-going inflammatory lesion that could be confused with fibroadenosis. Tuberculous mastitis has also been documented in pregnant and lactating women has been reported as well.<sup>[2,6,7]</sup> Medical literature has also reported the occurrence of this disease entity in post-menopausal women.<sup>[8]</sup>

The breast lump observed in our index patient in exhibited some atypical features which should raise the suspicion of the attending surgeon. These include the presence of ipsilateral axillary adenopathy that predated the breast lump as well as the presence of dull pains, irregular outline and surface as well as hard consistency of the mass. These features are almost the same as those exhibited by a carcinoma however; the presence of axillary lymph node (present in up to 75% of patients) that predated the breast lump [as the case was in our patient] should downplay the possibility of a malignancy.<sup>[9]</sup> It should be borne in mind that tuberculous mastitis could actually co-exist with a carcinoma as this has been reported by other workers.<sup>[10]</sup>

The pathology of axillary nodes that the breast lump could be related to the retrograde lymphatic flow from the lungs.<sup>[7,11]</sup> The retrograde pathway follows the trachea-bronchial nodes via the mediastinal nodes to the internal mammary nodes, then axillary and cervical nodes in that order.<sup>[10]</sup> Other routes of infection include the haematogenous spread, contiguous spread, direct inoculation and ductal infection.<sup>[2]</sup> Direct inoculation and ductal infection could occur when an infant with infected

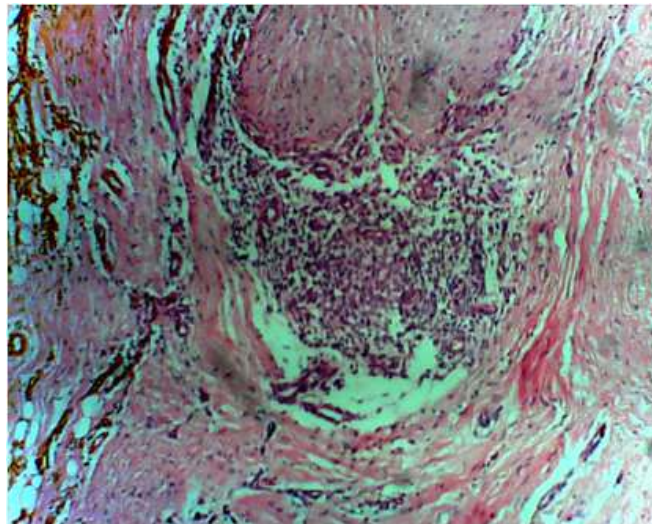
faucial tonsils sucks the nipple thereby infecting the lactiferous ducts and lobules.<sup>[5]</sup>

In diagnosing tuberculous mastitis, a detailed history and physical examination will raise the suspicion of the disease entity. Histopathological examination of the specimen was confirmatory of the disease as radiological and other investigations were misleading and inconclusive. Other authors have reiterated the undisputed role of histopathological diagnosis as this differentiates tuberculous mastitis from a carcinomatous lesion; both of which may exhibit similar radiological features.<sup>[10]</sup> Surgical biopsy in form of incisional or excisional biopsy will give enough tissues for histopathological analysis in which the caseating granuloma, Langhans cell and epithelioid cells which typify tuberculous lesions will be seen.<sup>[5,7]</sup>

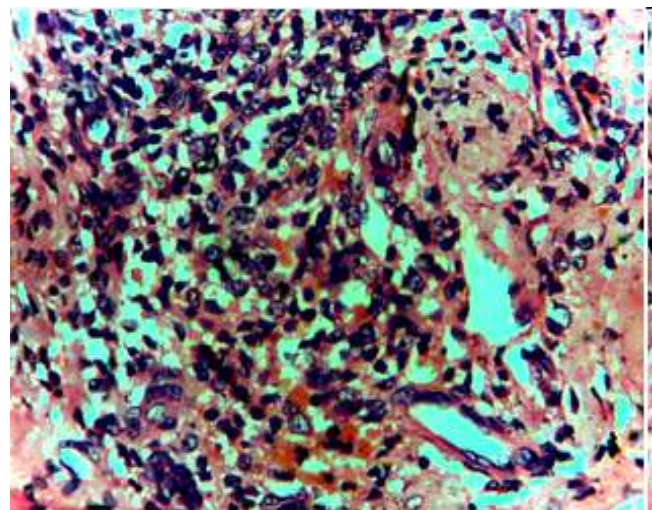
After confirming the diagnosis, the patient was commenced on anti-tuberculous therapy (ATT) for a period of 12 months. The axillary nodes regressed completely and the general outlook of the patient improved. Residual breast lump if present is removed surgically. Other indications for surgical intervention in tuberculous mastitis include the drainage of abscess, biopsy and scrapping the wall of abscess cavity or sinus for histopathological analysis.<sup>[4,5]</sup>

In the event that of a carcinoma co-exists with tuberculous mastitis, such is treated in accordance with the standard oncologic guidelines with respect to the stage of the disease, receptor status, and patient's performance status.

In conclusion, the diagnosis of tuberculous mastitis could be challenging and confusing to the unsuspecting surgeon. Biopsy at times may be inconclusive especially if large samples are not taken. The surgeon therefore, needs to be thorough in his assessment of breast lesions and always consider the possibility of tuberculous mastitis to avoid unwarranted mastectomies.



**Figure 1:** Section shows discrete granuloma adjacent to compressed breast ducts in a background of hyalinized fibrocollagenized tissue. H&EX40



**Figure 2:** Section shows epithelioid cells, foreign body and Langhans multinucleated giant cells in a background of necrosis. H&EX100

### References.

1. Stead WW. Bacterial diseases - Tuberculosis. In: The Merck manual of diagnosis and therapy. Berkow R, Fletcher AJ (Eds), 16<sup>th</sup> ed. New Jersey: Merck and Co., Inc; 1992: 131-146.
2. Mirsaeidi SM, Masjedi MR, Mansouri SD, Velayati AA. Tuberculosis of the breast: report of 4 clinical cases and literature review. EMHJ. 2007; 13(3): 270-276.
3. Sen M, Gorpelioglu C, Bozer M. Isolated primary breast tuberculosis-report of three cases and review of the literature. CLINICS. 2009; 64(6):607-610.
4. Shinde SR, Chandawakar RY, Deshmanka

- SP, Tuberculosis of the breast masquerading as carcinoma: a study of 100 patients. *World J Surg.* 1995; 19:379-381.
5. Tewari M, Shukla HS. Breast tuberculosis: diagnosis, clinical features and management. *Indian J Med Res.* 2005; 122:103-110.
  6. Akinola DO, Adejuyigbe O, Odesanmi WO. Primary tuberculous mastitis in a Nigerian woman. *WAfr J Med.* 1989; 8(3):209-212.
  7. Tauro LF, Martis JS, George C, Kamath A, Lobo G, Hegde BR. Tuberculous mastitis presenting as breast abscess. *Oman Med J.* 2011; 26(1):53-55.
  8. Bouti K, Soualhi M, Marc K, Zahraoui R, Benamor J, Bourkadi JE et al. Postmenopausal breast tuberculosis-report of 4 cases. *Breast care.* 2012; 7: 411-413.
  9. Sharma PK, Babel AL, Yadav SS. Tuberculosis of breast (Study of 7 cases). *J. Postgrad Med* 1991; 37:24-26.
  10. Alzaraa A, Dalal N. Co-existence of carcinoma and tuberculosis in one breast. *World J. Surg Oncol.* 2008; 6: 29.
  11. Khanna R, Prasanna GV, Gupta P, Kumar M, Khanna S, Khanna AK et al. Mammary tuberculosis: report of 52 cases. *Postgrad Med. J.* 2002; 78: 422-424.