

# SYNCHRONOUS CONGENITAL NASAL PIRIFORM APERTURE STENOSIS AND ATRESIA : A RARE ACCOMPANIMENT OF MID-FACIAL DYSTOSIS AND CAUSE OF NEONATAL UPPER AIRWAY OBSTRUCTION.

## A CASE REPORT

John EN<sup>1</sup>, Mbam TT<sup>2</sup>, Nimkur LT<sup>3</sup>, Fasunla AJ<sup>4</sup>

Correspondence: [Jeanemmanu@yahoo.com](mailto:Jeanemmanu@yahoo.com)

1. Senior registrar, department of ORL, Jos University Teaching Hospital, Jos, Nigeria
2. Senior registrar, department of ORL, University college Hospital, Ibadan, Nigeria
3. Consultant ORL/HN Surgeon, Jos University Teaching Hospital, Jos, Nigeria
4. Consultant ORL/HN Surgeon, University college Hospital, Ibadan, Nigeria

### ABSTRACT

*Congenital nasal piriform aperture stenosis (CNPAS) is a recently distinguished clinical entity that causes airway compromise in neonate as a result of a narrowing of the nasal piriform aperture. It may be bilateral or unilateral. Often considered as a form of holoprosencephaly. Being the narrowest part of the nasal airway, any slight reduction in its cross sectional area will profoundly increase the nasal airway resistance with the attendant clinical challenges. Readily making an accurate clinical diagnosis may be very challenging when CNPAS occurs in the setting of a craniofacial dysostosis. This communiqué is aimed at increasing awareness among clinicians involved in paediatric care of the clinical entity congenital nasal piriform aperture stenosis and atresia presenting atypically as synchronous disorder with midfacial dysostosis. Hence, it should be kept in mind as a rare mimicker of bilateral choanal atresia and requires mandatory high resolution computerized tomography to confirm the diagnosis.*

**Keywords:** Congenital nasal piriform aperture stenosis, atresia, craniofacial dysostosis, neonate

### INTRODUCTION

The first radiological report of congenital nasal piriform aperture (CNPAS) was in 1988 by Chinwuba and Wallman<sup>1</sup>, while, the first clinical description of CNPAS was 1989<sup>2</sup>.

Neonatal nasal obstruction due to CNPAS is very rare and uncommon<sup>2,3,4</sup>. Estimated to occur at a frequency of between one fifth to one third that of choanal atresia<sup>5</sup>. It is a potentially lethal form of airway obstruction in newborns<sup>6</sup>. Since, newborns are obligatory nasal breathers, immediate recognition and appropriate therapy is mandatory to avoid untoward consequences<sup>7</sup>. This anomaly may present as an isolated malformation or may be associated with other craniofacial anomalies including central nervous system and endocrine abnormalities<sup>5</sup>. CNPAS has been considered by some authors as a form of holoprosencephaly<sup>8</sup>. The piriform aperture (bony inlet) is the narrowest portion of the normal nasal passage, therefore, any further reduction in the cross sectional area results in an overt increase in nasal airway resistance<sup>9</sup>.

Clinically, CNPAS shows non-specific symptoms of nasal airway obstruction such as apnoeic crisis,

episodic or cyclical cyanotic spells, feeding difficulty which may subsequently result in poor weight gain and failure to thrive<sup>6</sup>. Presentation may be soon after delivery or many weeks after birth. Respiratory distress is often relieved on crying, thereby, making this conditions a true mimicker of choanal atresia<sup>5</sup>. The breathing problem may be triggered by episodes of recurrent upper respiratory tract infections<sup>5</sup>. Provisional diagnosis is suggested by history and physical examination; however, imaging is essential to confirm CNPAS<sup>2</sup>. It has been suggested that a total nasal piriform aperture width less than 8mm in a term infant is diagnostic of CNPAS<sup>2</sup>.

Surgery is indicated in cases of severe respiratory distress, feeding difficulties, and when there is no benefit with conservative treatment<sup>3</sup>. Surgical correction done via sub-labial approach followed by nasal stenting has proven to be most effective surgical treatment with very low risk of re-stenosis during the long term follow-up period<sup>6</sup>.

The midfacial dysostosis encountered in the index case report is Crouzon's syndrome. Crouzon

syndrome is a hereditary syndrome of craniofacial dysostosis and it is an autosomal dominant disorder with complete penetrance and variable expressivity<sup>10</sup>. Characteristically patients have premature closure of the calvaria and cranial base sutures as well as bones of the orbit and maxillary complex (craniosynostosis). Other clinical features include hypertelorism, exorbitism, strabismus, beaked nose, short upper lip, hypoplastic maxilla and relative mandibular prognathism<sup>10</sup>. Prevalence of this condition is 1 case per 60,000 live births and responsible for approximately 4.8% of all cases of craniosynostosis<sup>11</sup>. There is no racial or sex predilection. The unique anatomy of the skull base, facial skeleton and nasopharynx in these newborns with craniofacial dysostosis predispose them to having severely narrowed nasal and nasopharyngeal tract hence making them high risk group for development of obstructive sleep apnoea and nasal airway obstruction. The nasal symptoms of craniofacial dysostosis may therefore mask an otherwise obvious choanal atresia or CNPAS during assessment by the unsuspecting physician. This case report is aimed at increase the awareness of clinicians involved in paediatric care on the clinical entity congenital nasal piriform aperture stenosis and atresia which is though rare but may occur concurrently and misdiagnosed as choanal atresia.

### **Case Report**

Patient is a 5 weeks old male, first child of a non-sanguinous parents. Patient was delivered at term via spontaneous vaginal route by traditional birth attendant (TBA). Index pregnancy was neither booked nor supervised in the hospital. However, pregnancy was said to be uneventful. No history of ingestion of any identifiable teratogenic drugs and no family history of congenital anomaly. Apgar score and birth weight were not known, however, baby cried immediately after birth. Soon after birth, he continued to have noisy breathing, recurrent copious mucoid left nasal discharge, apnoeic spells, mouth breathing and refusal to suck from the breast. Childhood immunization was delayed due to the unremitting symptoms mentioned above.

Upon the advice of the TBA, mother presented with patient at the emergency paediatric unit of the University college hospital, Ibadan. Patient was assessed by both the paediatricians on duty and otorhinolaryngological team. Examination

revealed an obviously mouth breathing male child with dysmorphic craniofacial features i.e. bilateral buphthalmos, marked hypertelorism, beaked nose, hypoplastic maxilla and almost completely closed anterior and posterior fontanelles. Patient was also having intermittent cyanotic spells. Attempts at passing a well lubricated size 5 G feeding tube via both nasal cavities was not successful. However, scanty nasal air current was demonstrable from the left nasal cavity after suctioning of mucoid secretion. No other obvious structural defect detected in the ear, external genitalia or limbs. Admission weight and PCV were 3kg and 30% respectively. Patient was transferred to the special baby care unit for proper monitoring and nursing care.

Breast feeding and all oral feeds were stopped and patient commenced on intravenous fluid regimen. Patient was nursed in propped up position and connected to humidified oxygen delivered via appropriate size oropharyngeal airway anchored to the lips and buccal commissures.

Given the severe financial constraint of the parents, the hospital indigent fund was access to do an urgent computerized tomography (CT) scan of the paranasal sinuses was done. An urgent abdominal ultrasound scan, echocardiography and otoacoustic emission were also done with no significant abnormal findings. However, axial projections of CT done revealed hyperdense shadow in the region of the both right and left maxillary nasal processes worse on the right. Complete Atresia of the right nasal piriform aperture also noted. There is also severe narrowing of the left nasal piriform aperture, width measures about 1mm at the level of inferior turbinate. Overall, features are in keeping with synchronous congenital nasal piriform aperture stenosis and atresia.

Parents of the child were educated on the disease condition and re-assured. Non-operative management and patient followed up closely at the outpatient clinic with consideration of surgical correction later if symptoms persist. Please see figure 1,2,3 and 4 below for pictures and images

### **Discussion**

Neonatal nasal obstruction can present at birth as severe birth asphyxia. It is a potentially life threatening condition unless it is recognized early and treated, it may lead to profound respiratory distress in neonates because they are obligate nasal

breathers. When complete bilateral nasal obstruction is missed, it can lead to apnoeic crisis and repeated cyanotic episodes. The nasal pathology in the index case was missed at birth by the TBA, hence, the similar clinical presentation. The differential diagnosis of neonatal nasal obstruction includes skull base defects (meningoencephalocele and encephalocele), bony obstruction, cyst (dacryocystocele, dermoid and epidermoid cysts), traumatic lesions (subluxated septum and septal hematoma), tumoral processes (glioma, hemangioma, lymphangioma, teratoma, rhabdomyosarcoma) and nasal hypoplasia (chondroplasia punctata, warfarin teratogenicity).<sup>12,13</sup> In the absence of a cystic nasal mass, choanal atresia is often blamed as a cause of congenital neonatal airway obstruction and may be part of CHARGE syndrome. Congenital nasal piriform aperture stenosis and atresia is even a more remote cause of nasal bony obstruction in neonates<sup>2,4</sup>. This may explain why a diagnosis of choanal atresia and not CNPAS was entertained prior to performing a CT scan when the size 5G feeding tube could not be passed.

The nasal piriform aperture (pear shaped bony inlets) of the nose is formed by the nasal and maxillary bones and represent the narrowest part of the normal nasal passage<sup>9</sup>. Anatomically, the piriform aperture is bounded laterally by the nasal processes of the maxilla and inferiorly by the junction of the horizontal process of the maxilla. Embryologically, the palate is derived from 2 primordia; the primary and secondary palates<sup>15</sup>. The primary palate is formed from the merging of the medial nasal prominences and becomes the premaxillary portion of the maxilla, which contains the incisor teeth. It represents only a small part of the adult hard palate, the **Os incisivum** (located anterior to the incisive foramen) and forms the floor of the piriform apertures<sup>15</sup>. The secondary palate develops from the lateral palatine processes of the maxilla, and gives rise to the hard palate and soft palates (located caudal to the incisive foramen)<sup>15</sup>.

With respect to the pathogenesis of CNPAS, two theories have been popularized, namely, (1) Deficiency of the primary palate, associated with triangular hard palate, and (2) bony overgrowth in the nasal process of the maxilla, with normal shaped palate<sup>16</sup>. The index case had the latter form of presentation consistent with a spectrum of event with stenosis in one nasal cavity

and atresia in the other.

Phenotypically, there are 2 forms of CNPAS, namely, an isolated form and another variant that is associated with other anomalies including a midface dystostosis, endocrine and CNS abnormalities<sup>17</sup>. CNPAS with single central maxillary mega-incisor (SCMI) has been recognized as a microform of holoprosencephaly. The presence of CNPAS with SCMI should prompt further genetic analysis, endocrine disease assessment and radiological imaging to rule out possible holoprosencephaly and pituitary deficiency<sup>18,19,20</sup>.

The diagnosis of piriform aperture stenosis and atresia starts from the bedside when passing of size 5 or 6 feeding tube is attempted and then confirming the condition with a CT scan, by obtaining thin (1.5 to 3mm) contiguous axial sections in a plane parallel to the anterior hard plate. It is necessary to demonstrate the narrowing on contiguous sections, as apparent narrowing may be caused by oblique imaging<sup>16</sup>. The extent of nasal obstruction is shown is revealed on axial CT scan of the nose and paranasal sinuses. For confirmation of diagnosis of CNPAS, each piriform aperture width be less than 3mm or whole piriform aperture width measured from lateral wall of left nasal cavity to lateral wall of right nasal cavity must be less than 8mm. Other radiological findings include the presence of a narrowed anterior nasal inlet and bony overgrowth of the maxillary nasal process<sup>5</sup>. These radiological features fits the index case report while on axial CT images showed about 1.5mm aperture width on the left nasal cavity and unrestricted bony proliferation of the right maxillary nasal process resulting in piriform aperture atresia of the right nasal cavity. These features are clearly distinct from those seen in choanal atresia which are essentially thickening of the vomer (>5.5mm), narrowing of posterior choanal orifices (<3.4mm) and occasionally bowing of the maxillary sinus posterior wall<sup>8</sup>. In neonates with holoprosencephaly, they may have associated clinical features of pre-maxillary dysgenesis (hypotelorism and flat nasal bridge) and chromosomal abnormalities (trisomy 13 and 18).<sup>4,17,21</sup>

The co-existence of midfacial dysostosis may confound the rational clinical judgement and mind set of the attending clinician. Knowing fully well that craniodysostosis is due to premature closure of

suture lines in skull base and cranial vaults and these anatomic site share boundaries with the nasal cavity and nasopharynx<sup>10</sup>.

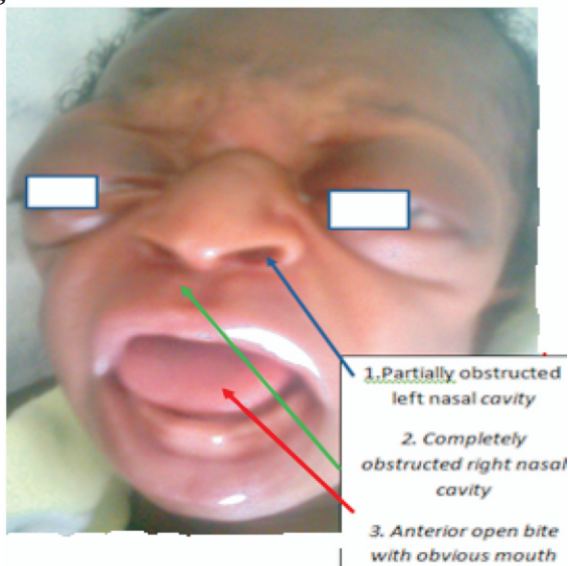
Once the diagnosis of CNPAS has been established, conservative treatment, which involves the use of topical nasal decongestants, humidification, insertion of oral airway, and small frequent feeding is the initial line of management. This was the option of treatment instituted in the index case report and surgical correction reserved in the event of worsening symptoms during follow up evaluation at the out-patient clinic. Surgical treatment aims at widening the bony inlet via a sublabbial approach and usually indicated when the conservative treatment does not suffice<sup>20</sup>. This is in contrast to the treatment of posterior choanal atresia, which is mainly surgical dilatation and stenting via transpalatal, transnasal or trans-septal

resection using endoscopic sinus surgery technique<sup>22</sup>.

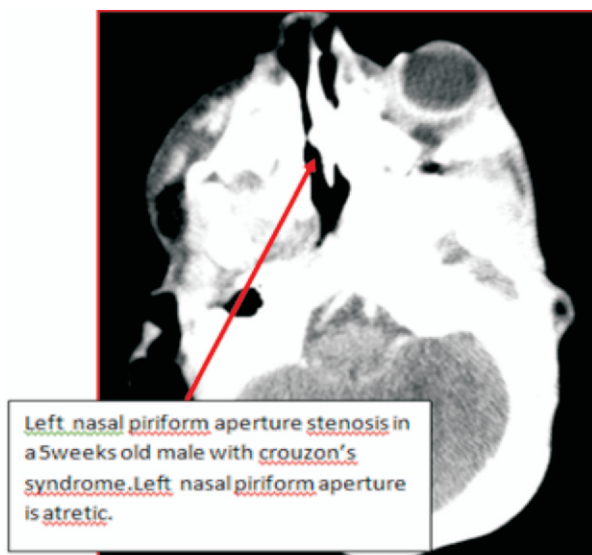
**Conclusion**

Although, a rare clinical entity, CNPAS should be suspected in newborns with clinical signs of severe nasal obstruction associated with difficulty to negotiate a small catheter through the anterior nasal valve. Congenital nasal piriform aperture stenosis and atresia can occur simultaneously in association with midfacial dysostosis. CT scan is a sine qua non for proper diagnosis. MRI, metabolic and genetic screening are indicated in suspected cases of CNPAS with holoprosencephaly. Timely recognition is mandatory to forestall potential fatal outcome. Surgical correction of the disorder can be delayed until conservative treatment fails and sublabbial approach followed by nasal stenting has revealed to be the most effective treatment for these patients with isolated form of CNPAS.

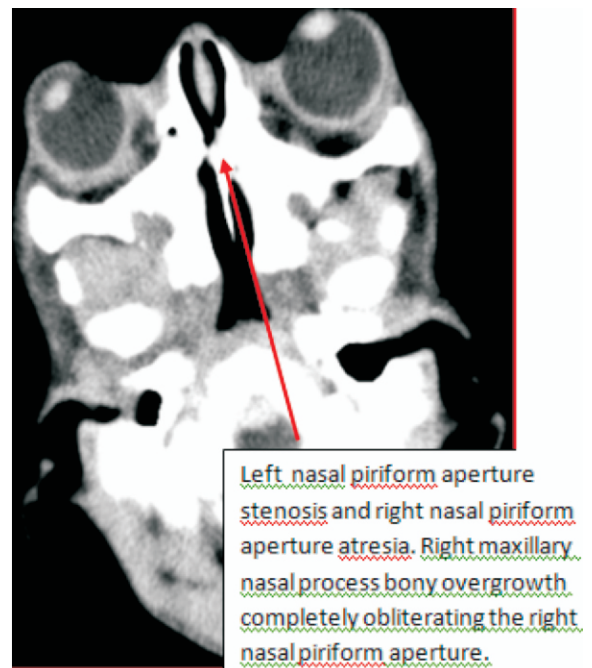
**Fig 2.**



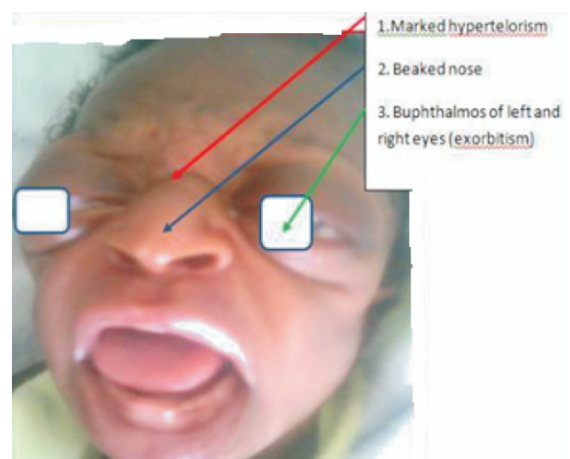
**Fig 3.**



**Fig 4.**



**Fig 1.**



## References

1. Chinwuba C, Wallman J, Stand R. Nasal airway obstruction CT assessment. *Radiology* 1986;159:503-506
2. Brown OE, Myer CM, Manning SC. Congenital nasal piriform aperture stenosis. *Laryngoscope* 1989;99:86-91
3. Phillippe JP, Wojciechowski M, Kominck M, Kurotova A, Claes J. A rare cause of neonatal nasal obstruction. *Journal of paediatric surgery* 2006;41:5-7
4. Van Den A, Triglia JM, Francois M, Nancy P. Congenital nasal piriform aperture stenosis: Diagnosis and Management of 20 cases. *Ann Otol Rhinol Laryngol* 2001 ; 110: 70 -75
5. Belden CJ, Mancuso AA, Schmalfuss IM. Features of congenital nasal piriform aperture stenosis: Initial experience. *Radiology* 1999; 213:495-501
6. Enrico S, Massimiliano L, Bruno B, Gabriele O and Andrea F. Congenital nasal piriform aperture : Diagnosis and Management. *Italian Journal of paediatrics*. 2012, 38:24
7. Elsa MT, Sridhar G, Jyoti SP, John M. Congenital nasal piriform aperture stenosis: A rare cause of nasal airway obstruction in a neonate. *Indian Journal of radiology and imaging*, 2010;20(4):266-268
8. Current Diagnosis and Treatment Otolaryngology, Head and Neck Surgery, 2<sup>nd</sup> Edition, Anil KL, Mc Graw Hill Companies Inc & Lange Medical books, 2008,, Chapter 10, Pg244-245
9. Rozner L. Nasal obstruction due to restriction of bony nasal inlet. *Br J Plast Surg*. 1964;17:287-296
10. Ahmed I , Afzal A. Diagnosis and evaluation of crouzon syndrome. *J coll Physicians Surg Pak*. 2009;19(5):318-320
11. Cohen MM, Kreiborg S. Birth prevalence studies of crouzon syndrome: Comparison of direct and indirect methods. *Clin Genet*. Jan 1992;41(1):12-15
12. Lowe LH, Broth TN, Joglar JM, Rollins NK. Midface anomalies in children. *Radiographics* 2000;20:907-922
13. Leraillez J. Neonatal nasal obstruction. *Arch paediatr* 2001;8:214-220
14. Kenman MA. Congenital disorders of nose. 16<sup>th</sup> edition. *Text book of paediatrics*, 2000p.1258
15. Moore KL. The branchial apparatus of the head and neck. *The developing human: Clinically oriented embryology*. Philadelphia: Saunders;1982
16. Ey EH , Ham BK, Towbin RB, Jaun WK. Bony inlet stenosis as a cause of nasal airway obstruction. *Radiology* 1988; 168: 477-479.
17. Arlis H, Ward RF. Congenital nasal piriform aperture stenosis. Isolated abnormality versus developmental field defects. *Arch Otolaryngol Head Neck Surg* 1992;118:989-991
18. Lo FS, Lee YJ , Lin SP, Shen EY, Huang JK, Lee KS. Solitary maxillary central incisor and congenital nasal piriform aperture stenosis. *Eur J Paediatr* 1998;157:39-44
19. DeMyer W, Zeman W, Palmer CG. The face predicts the brain: Diagnostic significance of median facial anomalies for holoprosencephaly (arhinencephaly). *Paediatrics* 1964;34:256-263
20. Devambez M, Delatte A, Fayoux P. Congenital nasal piriform aperture stenosis: Diagnosis and management. *Cleft palate Craniofac J* 2009;46:262-267
21. Tarvin E, Stecker E, Marion R. Nasal piriform aperture stenosis and the holoprosencephaly spectrum. *Int J Pediatr Otorhinolaryngol* 1994; 28: 199-204
22. Ramsden JD, Campisi P, Forte V. Choanal atresia and choanal stenosis. *Otolaryngol Clin North Am* 2009; 42:339-352