

## Case report

### Right paraduodenal hernia in an adult patient: emergency management

Adriá Rosat<sup>1&</sup>, Ana María Feria<sup>1</sup>, María Aranzazu Varona<sup>1</sup>, Víctor Vázquez<sup>2</sup>, Manuel Barrera<sup>3</sup>

<sup>1</sup>Department of General Surgery, Hospital Universitario Nuestra Señora de Candelaria, Ctra. Del Rosario 145, 38010 Sta Cruz de Tenerife, Spain, <sup>2</sup>Radiodiagnostic Service, Hospital Universitario Nuestra Señora de Candelaria, Ctra. Del Rosario 145, 38010 Sta. Cruz de Tenerife, Spain, <sup>3</sup>Transplantation Surgery Unit and General Surgery Service, Hospital Universitario Nuestra Señora de Candelaria, Ctra. Del Rosario 145, 38010 Sta. Cruz de Tenerife, Spain

<sup>8</sup>Corresponding author: Adriá Rosat, Department of General Surgery, Hospital Universitario Nuestra Señora de Candelaria, Ctra. Del Rosario 145, 38010 Sta Cruz de Tenerife, Spain

Key words: Right paraduodenal, hernia intestinal, malrotation adult emergency

Received: 03/10/2015 - Accepted: 16/10/2015 - Published: 27/04/2016

#### Abstract

We report a case of right paraduodenal hernia in an adult patient and its emergency diagnosis and management in an acute clinical presentation. A twenty-eight-year-old male patient was admitted in our outside hospital's emergency room after 12 hours of evolution of diffuse abdominal pain, nausea and vomiting. He referred a similar episode several months ago that ceased spontaneously. An abdominal CT scan with intravenous contrast demonstrated an encapsulated cluster of small bowel loops occupying mainly the right upper quadrant, lateral to the duodenum, suspicious for an internal hernia in the context of an intestinal malrotation. The patient underwent a laparotomy, which revealed a large sac containing dilated small bowel loops as shown by radiologic studies. The patient did well in postoperative and was discharged home on the fourth day after the surgery. In a year follow up the patient remained asymptomatic.

**Pan African Medical Journal. 2016; 23:240 doi:10.11604/pamj.2016.23.240.8104**

This article is available online at: <http://www.panafrican-med-journal.com/content/article/23/240/full/>

© Adriá Rosat et al. The Pan African Medical Journal - ISSN 1937-8688. This is an Open Access article distributed under the terms of the Creative Commons Attribution License (<http://creativecommons.org/licenses/by/2.0>), which permits unrestricted use, distribution, and reproduction in any medium, provided the original work is properly cited.

## Introduction

---

The first definition of a right paraduodenal hernia was proposed by Moynihan in 1906 and included the following criteria: most of the small bowel is trapped within a peritoneal sac between the right and transverse colon and is positioned right of midline, the hernia sac opens to the left at the ligament of Treitz, and either the superior mesenteric or ileocolic artery is found at the anterior aspect of the sac [1]. Signs and symptoms of paraduodenal hernia are extremely variable and may occur at any age [2]. The majority of cases are noted between the 4th and 6th decades of life. The average age at described diagnosis described is 38.5 years [3]. The most common presentation is acute small bowel obstruction, with crampy abdominal pain, nausea, vomiting and distension. The patient may complain of vague and chronic abdominal pain or periodic distension, which results from partial obstruction. Unfortunately, these nonspecific symptoms are often incorrectly attributed to biliary disease, gastritis, or gastroesophageal reflux. Physical examination is usually not revealing unless the hernia is large enough to produce an abdominal mass or causes intestinal obstruction [3]. The severity of signs and symptoms is directly proportional to the degree of obstruction [2, 4-6]. A paraduodenal hernia may be discovered incidentally at autopsy [2, 5]. In many cases it causes no symptoms and diagnosis may be made when a barium x-ray examination shows the small bowel either to the right or left of the midline in the abdomen [2]. We report a case of right paraduodenal hernia in an adult patient and its emergency diagnosis and management in an acute clinical presentation.

## Patient and observation

---

A twenty-eight-year-old male patient was admitted in our outside hospital's emergency room after 12 hours of evolution of diffuse abdominal pain, nausea and vomiting. There was no history of previous abdominal surgery. Blood analysis was unremarkable. He referred a similar episode several months ago that ceased spontaneously. An abdominal CT scan with intravenous contrast demonstrated an encapsulated cluster of small bowel loops occupying mainly the right upper quadrant, lateral to the duodenum, suspicious for an internal hernia in the context of an intestinal malrotation. There was a portion of bowel with less enhancement of contrast and associated mesenteric oedema, suggesting bowel suffering (Figure 1). The patient underwent a

laparotomy, which revealed a large sac containing dilated small bowel loops as shown by radiologic studies with suffering signs. Immediately after the liberation of the bowel inside the hernia, it recovered its normal aspect (Figure 2). The peritoneum of Treitz's angle was too lax and baggy (Figure 3) and so, in order to avoid recurrences of the hernia, we decided to open it and make a plicature over itself and to the preaortic retroperitoneum. The patient did well in postoperative and was discharged home on the fourth day after the surgery. In a year follow up the patient remained asymptomatic.

## Discussion

---

Paraduodenal hernia is the most common type of internal hernia, accounting for 53% of reported cases [4, 6]. The term 'paraduodenal hernia' refers to a hernia of the entire small bowel, or part of it, into a sac derived from folds of peritoneum and fossae normally found at the terminal or 4th portion of the duodenum. It represents a rare congenital anomaly which arises from an error of rotation of the midgut. There are two variants, right and left paraduodenal hernia, the right being less common [2]. A right paraduodenal hernia is formed when the prearterial limb fails to rotate around the superior mesenteric artery (SMA). The prearterial segment is the portion cephalic to the vitello-mesenteric duct and comprises the distal duodenum and the entire small bowel to the distal ileum. Therefore, a portion of the small bowel remains to the right of the SMA. Fusion of the ascending colonic mesentery to the retroperitoneum causes entrapment of the bowel within the primitive coelom, affecting from a single loop to the entire small bowel. The result is a hernia orifice that is always to the right of the midline and usually faces medially and slightly downward. The mesentery of the ascending colon and a portion of the transverse colon make up the anterior wall of the sac, while the SMA and ileocolic artery lie in the free edge of the sac [2]. A CT scan may demonstrate the characteristic features of internal herniation with clustered bowel loops with or without obstruction. In patients with internal hernias, CT scan demonstrated abnormalities in 56% of cases [7]. Most paraduodenal hernias do not present with acute hernia incarceration or strangulation and are often discovered incidentally during laparoscopy or laparotomy. It is, therefore, important to inspect the region surrounding the ligament of Treitz at exploration in cases of unexplained obstruction or gastrointestinal symptoms. Thus, a high index of suspicion and proper imaging can

be critical for early diagnosis of paraduodenal hernia [8]. Key step in operative management of a right paraduodenal hernia includes avoiding injury to the mesenteric vessels at the neck of the hernia while attempting to reduce the hernia contents without removing the sac itself. Operative treatment of hernia found incidentally at laparotomy has been debated [2, 4]. Paraduodenal hernias carry about a 50% lifetime risk of incarceration, which may lead to bowel obstruction and strangulation. Therefore, treatment has been recommended. The mortality rate is not clear but approximates 20-50%, due to the large proportion of patients with intestinal obstruction and ischemia requiring emergency surgery. There is a poorer prognosis if strangulation occurs and a long segment of small bowel is rendered ischemic. Moreover, this may result from delay in intervention, as signs of peritonitis may be masked by the retroperitoneal position of the hernia [9,10].

## Conclusion

---

This rare anatomical anomaly should be considered as part of the differential diagnosis for any younger patient presenting with a small bowel obstruction without history of previous abdominal surgery. Confirmation of a paraduodenal hernia with signs of obstruction or strangulation mandates urgent operative exploration. Having a high index of suspicion for this disease entity is important because the rate of bowel necrosis can be as high as 20%. The contrast-enhanced CT scan was very helpful in the case reported since it allowed an early laparotomy which avoided intestinal resection in a patient who shown non specific symptoms.

## Competing interests

The authors declare no competing interests.

## Authors' contributions

---

All authors have read and agreed to the final version of this manuscript and have equally contributed to its content and to the management of the case.

## Figures

---

**Figure 1:** CT showing the right upper cluster of bowel inside the hernia sac with a deficit of contrast captation and mesenteric oedema

**Figure 2:** Small bowel recovery with still lymph and venous ecstacy

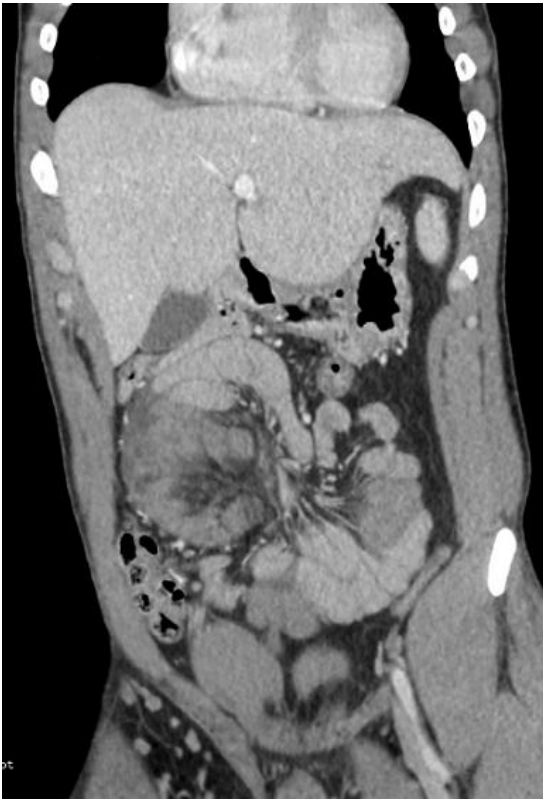
**Figure 3:** Intraoperative photograph of Treitz's angle, lax and baggy

## References

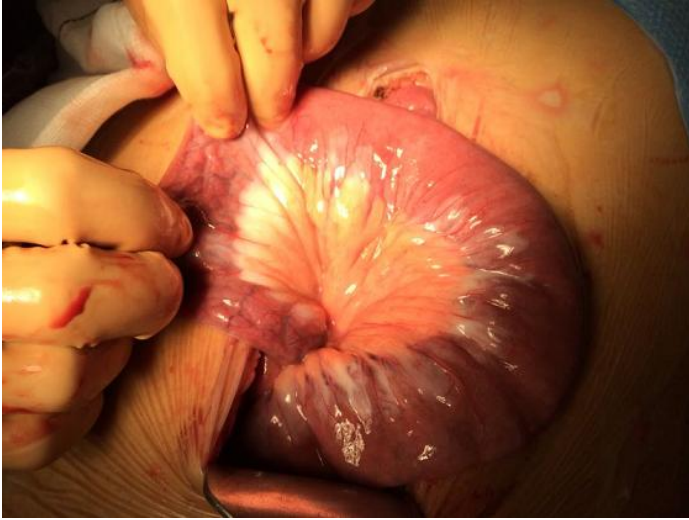
---

1. Lahey FH, Trevor W. Right paraduodenal hernia. *Ann Surg.* 1945;122(3):436-43. **PubMed | Google Scholar**
2. Bartlett MK, Wang C, Williams WH. The surgical management of paraduodenal hernia. *Ann Surg.* 1968;168(2):249-254. **PubMed | Google Scholar**
3. Ghahremani GG. Internal abdominal hernias. *Surg Clin North Am.* 1984;64(2):393-406. **PubMed | Google Scholar**
4. Khan MA, Lo AY, Vande Maele DM. Paraduodenal hernia. *Am Surg.* 1998;64(12):1218-1222. **PubMed | Google Scholar**
5. Murray HOL. Left paraduodenal hernia. *Can Med Assoc J.* 1955;72(4):263-267. **PubMed | Google Scholar**
6. Hansmann GH, Morton SA. Intra-abdominal hernia: report of a case and review of the literature. *Arch Surg.* 1939;39(6):973-986. **PubMed | Google Scholar**
7. Wachsberg RH, Helinek TG, Merton DA. Internal abdominal hernia: diagnosis with ultrasonography. *Can Assoc Radiol J.* 1994;45(3):223-4. **PubMed | Google Scholar**
8. Lam G, Clifton MS, Bhatia AM. Right paraduodenal hernia leading to bowel strangulation. *J Pediatr Surg.* 2011;46(10):2032-2034. **PubMed | Google Scholar**
9. McDonagh T, Jelinek GA. Two cases of paraduodenal hernia, a rare internal hernia. *J Accid Emerg Med.* 1996;13(1):64-68. **PubMed | Google Scholar**

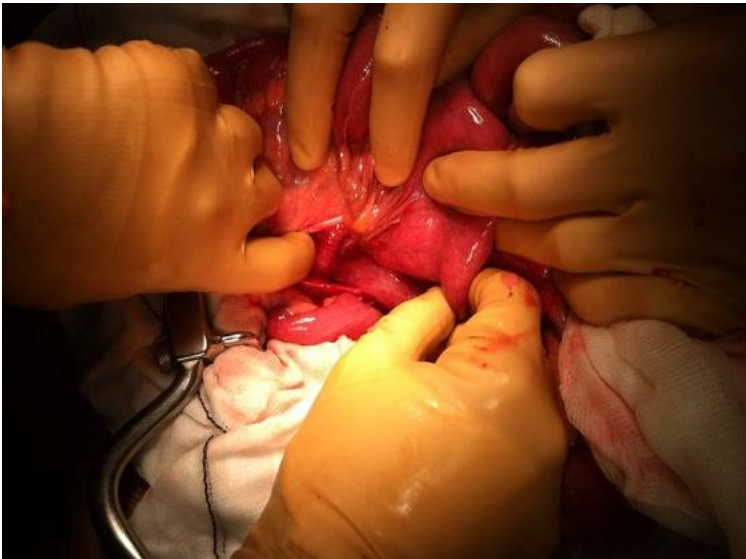
10. Tong RSK, Sengupta S, Tjandra JJ. Left paraduodenal hernia: a case report and review of the literature. ANZ J Surg. 2002;72(1):69-71. **PubMed** | **Google Scholar**



**Figure 1:** CT showing the right upper cluster of bowel inside the hernia sac with a deficit of contrast captation and mesenteric oedema



**Figure 2:** Small bowel recovery with still lymph and venous ecstasy



**Figure 3:** Intraoperative photograph of Treitz's angle, lax and baggy