

Case report

A giant right atrial myxoma with pulmonary arterial hypertension

Ihsen Zairi^{1, &}, Khadija Mzoughi¹, Zouhayer Jnifene¹, Sana Fennira¹, Fathia Ben Moussa¹, Sofiene Kammoun¹, Mohamed Mounir Dhiab¹, Sondos Kraiem¹

¹Department of Cardiology, Habib Thameur Public Hospital, Bab El Fallah, Tunis, Tunisia, ²Departement of Cardio Vascular Surgery, La Rabta Hospital, Tunis, Tunisia

[&]Corresponding author: Ihsen Zairi, Department of Cardiology, Habib Thameur Public Hospital, Bab El Fallah, Tunis, Tunisia

Key words: Atrial myxoma, surgery, cardiac tumors

Received: 13/05/2015 - Accepted: 21/05/2015 - Published: 05/06/2015

Abstract

Here we report a case of a right atrial mass that morphology mimicking myxoma, in a young patient with no past medical history. The mass was pathologically confirmed to be symptomatic and surgical removal was successfully done.

Pan African Medical Journal. 2015; 21:96 doi:10.11604/pamj.2015.21.96.7055

This article is available online at: <http://www.panafrican-med-journal.com/content/article/21/96/full/>

© Zairi Ihsen et al. The Pan African Medical Journal - ISSN 1937-8688. This is an Open Access article distributed under the terms of the Creative Commons Attribution License (<http://creativecommons.org/licenses/by/2.0>), which permits unrestricted use, distribution, and reproduction in any medium, provided the original work is properly cited.

Introduction

Atrial myxomas are the most common primary heart tumors. Because of nonspecific symptoms, early diagnosis may be a challenge. The majority of myxomas are located in the left atrium and have variable clinical presentation. We report a case of a large myxoma in the right atrium, which is an uncommon location for this type of tumor.

Patient and observation

A 44-year-old woman was admitted to Habib Thameur Hospital because of progressive dyspnea and asthenia. No past medical history of cardiovascular risk factors. Clinical examination showed a well-looking woman with a facial pigmentation. No signs of congestion was noticed. Cardiac auscultation revealed normal heart sounds and a systolic murmur in Tricuspid Valve Area. Trans thoracic echocardiogram exam demonstrated a mobile right atrial mass enclosed in the right ventricle and measures 7 cm of diameter (**Figure 1**). There was an important pulmonary arterial hypertension. Magnetic Resonance Imaging reveals an intracardiac tumor between right atrium and ventricle (**Figure 2**). The diagnosis of right atrial myxoma was made and the tumor resection surgery was indicated. Median sternotomy was performed. A dilated right atrium was opened after cardio pulmonary bypass was initiated. When the right atrium was dissected, it was found a cardiac mass in the right atrium measuring 7 cm of maximal diameter, appended to the interatrial septum that looks like a typical cardiac myxoma (**Figure 3, Figure 4**), which is enclosing and occupying almost the whole right ventricle. The tumor was resected and then the residual septal defect was repaired with a Dacron patch. A tricuspid annuloplasty was done because the tricuspid annulus was dilated. After the operation, the patient was transferred to the intensive care unit and was extubated. Trans thoracic echocardiogram exam reveals regression of pulmonary arterial hypertension. The postoperative course was uneventful and he was discharged six days later. This patient was viewed three months later and she was totally asymptomatic.

Discussion

Primary cardiac neoplasms are rare and occur with an estimated incidence of 0.0017% to 0.19%, representing less than 5% of all heart tumors [1]. Myxoma is the most prevalent primary heart tumor and are the most common benign tumours of the heart [2]. Cardiac myxomas usually develop in the atria. About 75% of myxomas arise in the left atrium. Right atrial myxomas are rare as myxomas are estimated to occur in the right atrium in only 15-20% of the cases [3]. Only 3 to 4 percent of myxomas are detected in the left ventricle, and only 3 to 4 percent in the right [4]. Myxomas occur in all age groups but are particularly frequent between the third and sixth decades of life [5]. Clinical presentation is varied and may mimic arterial embolism or symptoms of cardiac, infectious, malignant and immune diseases, therefore making their diagnosis challenging [2]. RA myxomas may remain asymptomatic [6] or eventually cause constitutional signs and symptoms, including fever, weight loss, arthralgias, Raynaud phenomenon, anemia, hypergammaglobulinemia, and an increased erythrocyte sedimentation rate due to the production of interleukin-6 [7]. These symptoms disappear after the tumor is removed. In this report, our patient denied arthralgias, and anemia but complained of facial pigmentation as the only constitutional sign. However, the most common

manifestation is dyspnea (in 80% of patients), and right heart failure has been reported. Dyspnea on exertion was found in this case [7]. Echocardiography, including the transesophageal approach, is the most important means of diagnosis (sensitivity of up to 100%); CT and MRI may also be helpful. Resonance imaging and CT provide information regarding tissue characteristics and allow an excellent overview of cardiac and paracardiac morphology. MRI, in this case, showed an enlarged cardiac silhouette with an expansive ovoid mass in the RA with a density greater than that in the heart muscle [8]. The treatment is complete resection of the tumor and its implantation [9].

Conclusion

The RA should always be considered in the differential diagnosis of a right-sided heart mass, especially when the patient shows signs and symptoms of heart failure with uncertain etiology.

Competing interests

The authors declare no competing interests.

Authors' contributions

I.Z. analyzed and interpreted the patient data regarding the cardiac mass and performed the final review of the manuscript. J.Z. helped to conduct the review of the literature and made a major contribution to the writing of the manuscript. M.K. and J.Z. prescribed treatment and follow up the patient. D.M. described the surgical aspects of the procedure. K.S. analyzed and interpreted the patient imaging data. J.Z. translated and reviewed the manuscript. All authors read and approved the final manuscript.

Acknowledgements

We thank the colleagues and the personnel of Habib Thameur Hospital at who have been of invaluable assistance.

Figures

Figure 1: transthoracic echocardiogram: the four chambers and parasternal TM view showing the hyperechoic mass in the right atrium which was wide based and appended to the interatrial septum and prolapsing through the tricuspid valve

Figure 2: magnetic resonance imaging: showing the mass in the right atrium

Figure 3: intraoperative photograph of the tumor projecting from the right atrium and attached to the interatrial septum

Figure 4: explanted tumor, a lobulated mass

References

1. Azevedo O et al. Massive right atrial myxoma presenting as syncope and exertional dyspnea: case report. *Cardiovascular Ultrasound*. 2010; 8(1): 23. [PubMed](#) | [Google Scholar](#)

2. Diaz A et al. Left atrial and right ventricular myxoma: an uncommon presentation of a rare tumour. *Interact Cardiovasc Thorac Surg.* 2011; 12(4): 622-3. [PubMed](#) | [Google Scholar](#)
3. Reynen K. Cardiac myxomas. *N Engl J Med.* 1995; 333(24): 1610-7. [PubMed](#) | [Google Scholar](#)
4. Silverman NA. Primary cardiac tumors. *Ann Surg.*1980; 191(2): 127-38. [PubMed](#) | [Google Scholar](#)
5. Griffiths GC. A review of primary tumors of the heart. *Progress in Cardiovascular Diseases.* 1965; 7(5): 465-479. [PubMed](#) | [Google Scholar](#)
6. Yuce M et al. A huge obstructive myxoma located in the right heart without causing any symptom. *Int J Cardiol.* 2007; 114(3): 405-6. [PubMed](#) | [Google Scholar](#)
7. Guhathakurta S, Riordan JP. Surgical treatment of right atrial myxoma. *Tex Heart Inst J.* 2000; 27(1): 61-3. [PubMed](#) | [Google Scholar](#)
8. Oliveira R et al. Cardiac myxoma: a 13-year experience in echocardiographic diagnosis. *Rev Port Cardiol.* 2010; 29(7-8): 1087-100. [PubMed](#) | [Google Scholar](#)
9. Arruda MV et al. Resection of left ventricular myxoma after embolic stroke. *Rev Bras Cir Cardiovasc.* 2008; 23(4): 578-80. [PubMed](#) | [Google Scholar](#)

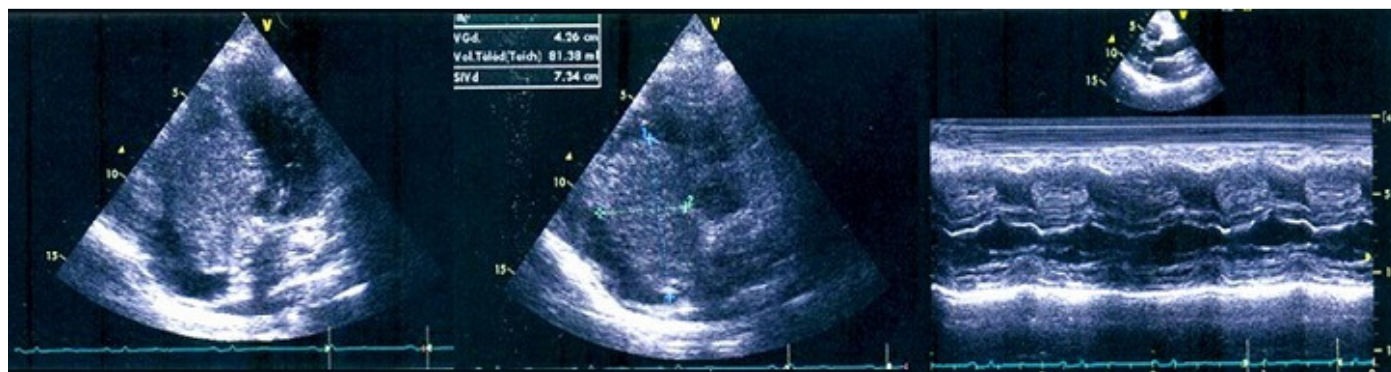


Figure 1: transthoracic echocardiogram: the four chambers and parasternal TM view showing the hyperechoic mass in the right atrium which was wide based and appended to the interatrial septum and prolapsing through the tricuspid valve

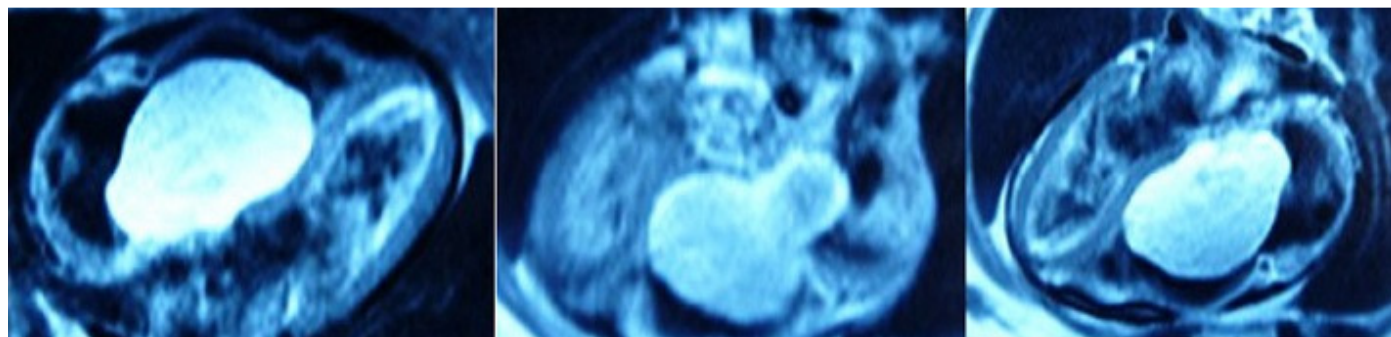


Figure 2: magnetic resonance imaging: showing the mass in the right atrium

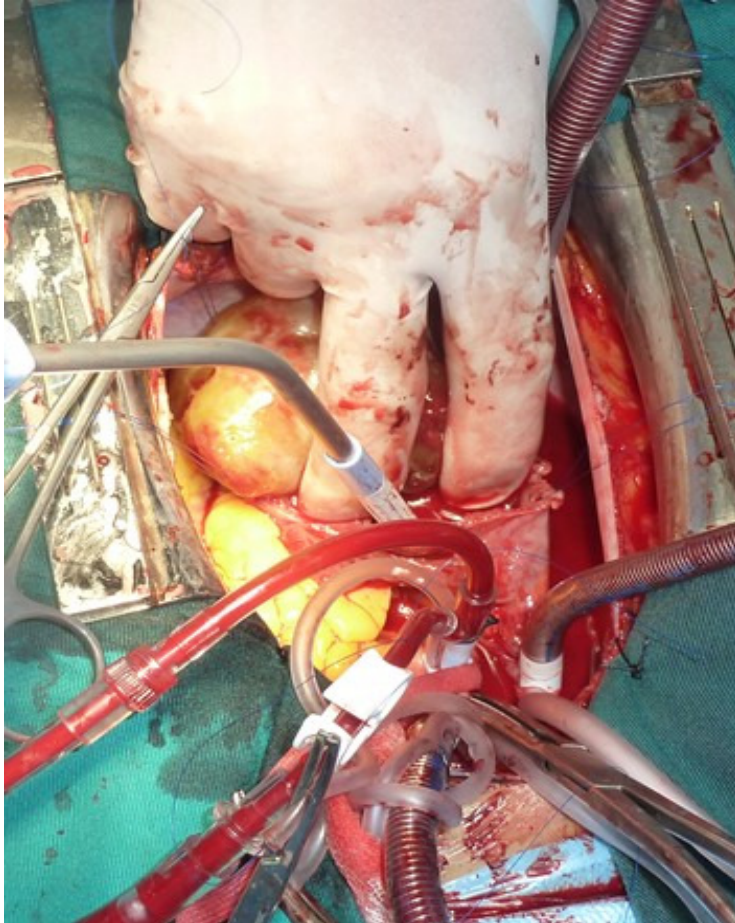


Figure 3: intraoperative photograph of the tumor projecting from the right atrium and attached to the interatrial septum

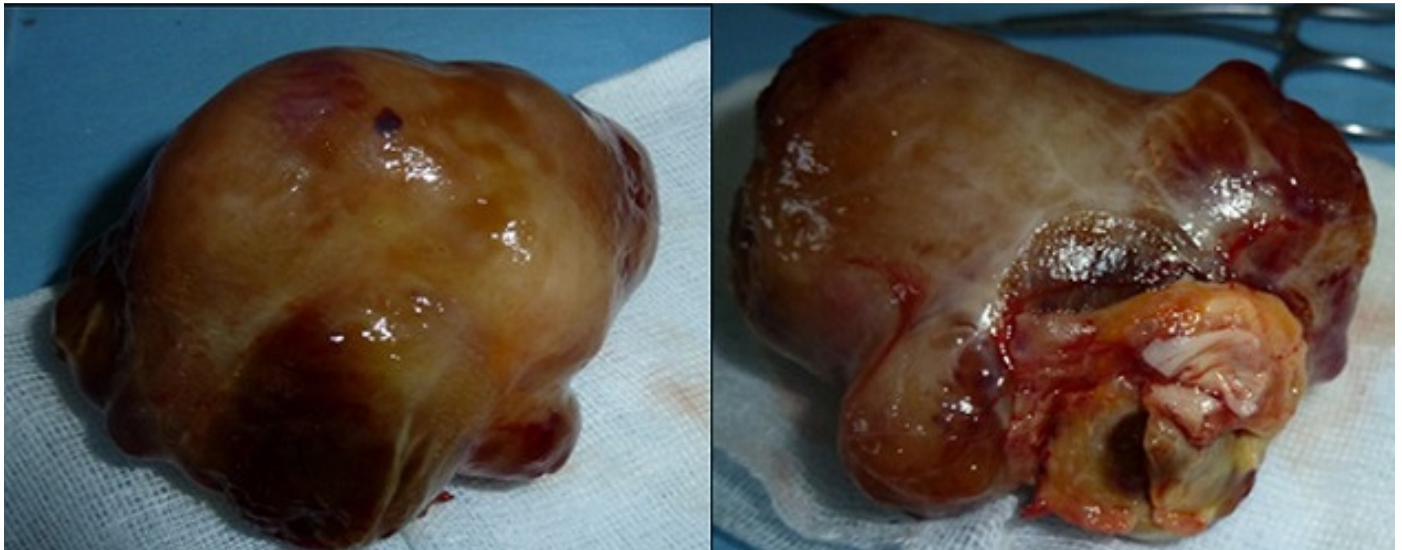

Figure 4: explanted tumor, a lobulated mass