

STABILISATION OF POSTERIOR STERNOCLAVICULAR JOINT DISLOCATION USING PALMARIS LONGUS TENDON AUTOGRAFT: A CASE REPORT

V.M. Mutiso*, MBChB(UON), MMed(Surg) (UON), Fellow (arthroscopy and arthroplasty) (UK), Fellow AO-International (Ger), FCS (ecsa), Department of Orthopaedic Surgery, College of Health Sciences, University of Nairobi, P.O. Box 19681 - 00202, Nairobi, Kenya and **J. Chigumbura**, MBChB (UK), GPST1 (UK) - University Hospital of North Staffordshire, UK

Correspondence to: Dr. V.M. Mutiso, P.O. Box 19681 - 00202, Nairobi, Kenya. Email: mutisovm@doctors.org.uk

*At the time of writing Dr. Mutiso was a Clinical Fellow (Arthroplasty and Arthroscopy) in the Musculoskeletal Directorate of the University Hospital of North Staffordshire, UK.

ABSTRACT

Posterior sternoclavicular joint dislocation is a rare injury. It is usually sustained acutely in activities such as contact sports eg. rugby and motorcycle accidents. Plain radiography of the chest will often miss the diagnosis and confirmation is by CT scans. However CT scans are often reported to miss epiphyseal injuries. Management is by closed reduction and if the injury is unstable, by open reduction and stabilisation. A case is reported where palmaris longus tendon was used to stabilise the joint following open reduction.

INTRODUCTION

Posterior sternoclavicular joint dislocation is a relatively rare injury and is reported to have been first documented by Sir Astley Cooper in 1824 (1,2). It is a potentially life threatening injury due to the anatomical structures that lie immediately behind the joint in the thoracic cavity. These include the great retrosternal vascular structures as well as the trachea, oesophagus and neural structures. Complications include respiratory compromise, haemothorax, pneumothorax, dysphagia, brachial plexopathy and even death (3-5).

The capsule surrounding the joint is weakest inferiorly with the other surfaces reinforced by the interclavicular, anterior and posterior sternoclavicular and costoclavicular ligaments. The posterior sternoclavicular joint capsule is the most important structure for preventing both anterior and posterior translation of the sternoclavicular joint with the anterior capsule acting as an important secondary stabiliser (4). The interclavicular ligament is a continuation of the deep cervical fascia and connects the medial ends of the two clavicles. The costoclavicular ligament or rhomboid ligament consists of anterior and posterior laminae connecting the clavicle to the first rib and the first costal cartilage (6).

CASE REPORT

A 19 year old female was admitted with a history of injury whilst playing with her friend. During the course of the game she reportedly pulled on her right the arm at approximately 90 degrees of elevation and 45 degrees of adduction. She was upright at the time. She weighed approximately nine stone and her friend was of approximately the same weight. She felt rather than heard a ripping sound closely followed by intense pain in the region of her right sternoclavicular joint of her chest wall. She went to the accident and emergency department of the hospital where chest X-rays were done and some oral analgesics administered. She was subsequently referred to the fracture clinic for review and follow up.

On review at the clinic there was no obvious chest bruising or deformity at the sternoclavicular joint. It was however tender on palpation. The arm had good circulation and was neurologically intact. Active movement of the limb was however restricted due to pain. Thus other than the tenderness and the reluctance to use the right upper limb the clinical findings were relatively unremarkable.

Plain X-rays of the chest were also unremarkable. The mechanism of injury and the history raised suspicion of a sternoclavicular joint injury and thus CT scans were requested. These showed a posterior dislocation of her right sternoclavicular joint.

Once the diagnosis had been made, it was recommended that the best course of action was reduction of the dislocation. This was discussed with

the patient and her mother who was present. The plan was to do a closed reduction and assess stability and if unstable progress to open reduction and stabilization. In view of the potential risk to intrathoracic structures interdisciplinary consultation was undertaken and the cardiothoracic surgeons were involved. Thus consent was taken for closed manipulation under general anaesthesia, to progress to open reduction and stabilisation of the right sternoclavicular joint and also for cardiothoracic surgical intervention should the need arise.

Pre operative history confirmed the mechanism of injury. She was noted to be a 19 year old female of good general health. There was no history of chronic illnesses and there was no clinical evidence of generalized joint laxity. She was well orientated in time, place and person. There were no other symptoms or physical signs specifically related to compression of intrathoracic structures.

The patient was understandably a little bit anxious about surgery especially when during consent taking the discussion centred on the potential to damage to the great vessels.

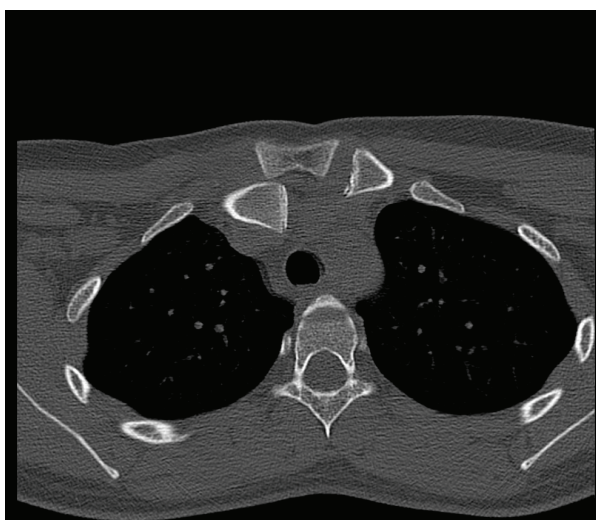
Figure 1

Plain AP radiograph of chest showing sternoclavicular joints

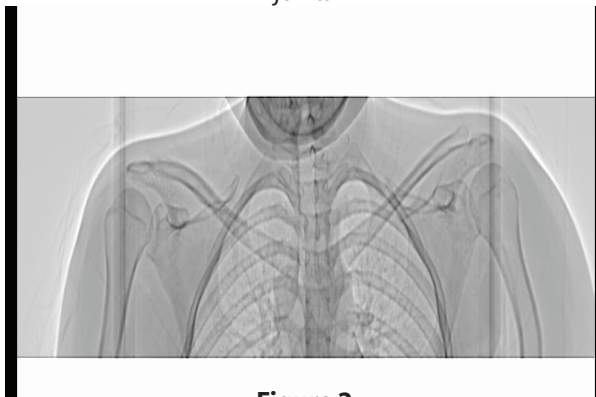

Figure 2

CT scan of chest showing sternoclavicular joint



Procedure: Under general anaesthesia the patient was placed supine on the operating table. Attempts were made to reduce the right sternoclavicular joint. The medial end of the clavicle was gripped by the pointed ends of a surgical towel clamp and an anterior force applied reducing the joint, however the joint repeatedly re-dislocated posteriorly and was thus found to be unstable. Having confirmed that the joint was unstable the team open reduction and internal fixation was indicated and the team proceeded to undertake the procedure.

Palmaris longus was harvested subcutaneously from the forearm of the same side using three small longitudinal incisions to allow for cosmetically aesthetic scars. This was deemed important as the patient was a 19 year old female. The sternoclavicular joint was exposed using an L shape incision over it. The dislocation was reduced and two burr holes made at the medial end of the right clavicle antero-superiorly and antero-inferiorly. Similar burr holes were made in the adjacent manubrium sternum.

Palmaris longus tendon was threaded through the holes in a figure of eight manner and stitched on itself using fibrewire type sutures. The construct was stable on testing and the skin was closed in layers from periosteum outwards. The skin was closed with subcuticular absorbable sutures.

Post operatively the arm was supported in a sling. Post operative follow up was uneventful. The skin healed well and she was commenced on physiotherapy with good functional and cosmetic result.

DISCUSSION

The sternoclavicular joint is the only synovial joint linking the upper limb with the appendicular skeleton. It has an intra-articular disc and is classified as a sliding joint. It tends to be mobile in younger individuals. This injury is most common following acute trauma and is often associated with contact sports such as rugby, martial arts and with motorcycle accidents.

All ligaments must be torn from the sternoclavicular joint for it to dislocate posteriorly (6). Pain over the sternoclavicular joint is an invariable symptom. There may be bruising and deformity over the region and variable loss of active movement of the upper limb.

Standard AP views of the chest are often difficult to interpret and may not show the dislocation. Other views such as Serendipity views (Rockwood), Hobb, Kattan and Heinig may help (5). One should have a high index of suspicion.

CT scanning will often clinch the diagnosis and gives an indication of the severity as well as the involvement of the mediastinal structures. As major vessels of the thoracic cavity may be involved some authors recommend angiography both pre and post reduction. However this has to be balanced against the

invasive nature of these investigations. MRI angiography is ideal.

The treatment of posterior sternoclavicular joint dislocation is varied owing to the rarity of the condition and the difficulty in diagnosis. Although a CT scan will often confirm the diagnosis epiphyseal injury may be missed. At the time of writing Lafosse *et al* (5) had the largest series comprising 30 cases of posterior sternoclavicular joint dislocation. In his retrospective study five of eight medial clavicle epiphyseal injuries were missed by CT scan in his series and only diagnosed at open surgery (5).

Singh *et al* (7) reports a case of posterior dislocation in an 11 year old child whilst playing rugby with successful treatment by closed reduction. A biomechanical study by Spencer *et al* (8) favours repair by semitendinosus tendon grafts with figure of eight stabilisation threaded through burr holes at the medial end of the clavicle and adjacent manubrium sternum. He reports that these have higher tensile strength than intramedullary ligaments as well as subclavius tendon repairs. Repairs can also be undertaken using costo-clavicular cerclage with non-absorbable sutures. Tendons of subclavius and use of medial head of sternocleidomastoid muscle has been advocated by some authors.

Complications: These are related to the intrathoracic structures that may be affected by the posterior translation of the medial clavicle in cases of posterior dislocation of the sternoclavicular joint. These include dyspnoea, respiratory obstruction, haemopneumothorax, truncal damage, great vessel injury, laryngeal damage, vocal cord palsy, and dysphagia. Possible late complications include possible oesophageal rupture, respiratory compromise, pneumothorax, dysphagia, brachial plexopathy and even death.

Management: Reduction is advised in all cases and should be closed where possible. Open reduction is recommended if the joint is unstable or the reduction fails. Stability can be achieved by various methods of fixation such as palmaris longus tendon as in this case, various suture types and if all else fails resection of the proximal clavicle (9). There may be a problem with reduction of the dislocated joint in patients seen 48 hours after injury (3, 10). Use of wire fixation is discouraged because of a potential for the wire to

migrate (5). There is good long term expectation. In a paper by Nathan *et al* (3), a farmer with a similar injury is reported to have regained full factory related activity within 6 months and at two years was problem free. Mirza *et al* (1) reports stability at 8 months.

ACKNOWLEDGEMENT

The following two consultant orthopaedic surgeons are acknowledged, Mr. D. Griffiths, hip and knee surgeon and Mr. D. McClelland, a shoulder surgeon both at the University Hospital of North Staffordshire.

REFERENCES

1. Mirza, A.H., Alan, K. and Ali, A. Posterior sternoclavicular dislocation in a rugby player as a cause of silent vascular compromise. A case report. *Br. J. Sports Med.* 2005;**39**: e28.
2. Wirth, M.A. and Rockwood, C.A. Acute and chronic traumatic injury of the sternoclavicular joint. *J. AM. Acad. Orthop. Surg.* 1996; **4**: 268-278.
3. Nathan, H., Michael, T., Mark, A., Stephen, D. and Cassivi, M.D. MSc Posterior sternoclavicular joint dislocation. *Can J. Surg.* 2008; **51**(1): e19-e20.
4. Gunther, W. A. Posterior dislocation of the sternoclavicular joint: Report of a case. *J. Bone Joint Surg.* 1949; **31**: 878-879.
5. Lafosse, J.M., Espie, A., Bonneville, N., *et al* posterior dislocation of the sternoclavicular joint and epiphyseal disruption of the medial clavicle with posterior displacement in sports participants. *J. Bone Joint (BR)*. 2010
6. Rajanathan, S., Kering, M. and Apthup, L. Posterior dislocation of the sternoclavicular joint: A case report and review of the clinical anatomy of the region. *Clinical Anatomy*. 2002; **15**: 108-111.
7. Singh, V. K., Singh, P. K., Mishra, A., and Tomar, J. Asymptomatic traumatic posterior dislocation of sternoclavicular joint in a child: A case report. *J. Orthopaed.* 2007; **4** (3): e14.
8. Spencer, Jnr, E. E., and Kuhn, J. E. Biomechanical analysis of reconstructions for sternoclavicular joint instability. *J. Bone Joint Surg. AM.* 2004; **86**: 98-105.
9. Samba, G.H. and Sidoffi, E. Stenoclavicular dislocation (letter). *J. Cardiothoracic Surg.* 1990; **99** (6): 1114-1115.
10. Bicos, J. and Nicholson, J. P. Treatment and results of sternoclavicular joint injury. *Clin. Sports Med.* 2003;**22**: 359-370.