

# Perforated Appendix in a Neonate: A Review of Literature and a Case Report from Northern Tanzania

Lodhia Jay,<sup>1,2</sup> Philemon Rune,<sup>2,4</sup> Wapalila Daudi,<sup>1</sup> Sadiq Adnan,<sup>2,3</sup> Amsi Patrick,<sup>2,5</sup> Msuya David,<sup>1,2</sup> Herman Ayesiga,<sup>1,2</sup>

<sup>1</sup>Department of General Surgery, Kilimanjaro Christian Medical Center

<sup>2</sup>Kilimanjaro Christian Medical University College

<sup>3</sup>Department of Radiology, Kilimanjaro Christian Medical Center

<sup>4</sup>Department of Pediatrics, Kilimanjaro Christian Medical Center

<sup>5</sup>Department of Pathology, Kilimanjaro Christian Medical Center

**Correspondence to:** Dr Lodhia Jay; email: jlodhia2002@yahoo.com

Received: 27 January 2020; Revised: 08 May 2020; Accepted: 09 June 2020; Available online: 20 July 2020

## Summary

Acute perforated appendicitis is rare in neonates and is associated with high morbidity and mortality. This is mainly because the rarity of the pathology and the abnormal clinical features cause delays in diagnosis and definitive management. We report a case of a premature neonate who presented with sudden onset of abdominal distension associated with an inability to pass stools. The initial abdominal X-ray showed free air under the right hemi-diaphragm. An emergency laparotomy was performed revealing a perforation at the appendicular tip. An appendectomy was done, and the neonate recovered well with a mild surgical site infection during the course of recovery. Neonatal perforated appendicitis is rare, and clinicians need to

consider it as a differential diagnosis due to the atypical presentations. This preterm neonate presented with clinical features of intestinal obstruction and was found at laparotomy to have a perforated appendix at the tip due to neonatal appendicitis.

**Keywords:** Neonate, Neonatal appendicitis, Neonatal perforated appendicitis

Ann Afr Surg. 2021; 18(2): 115–118

DOI: <http://dx.doi.org/10.4314/aas.v18i2.10>

**Conflicts of Interest:** None

**Funding:** None

© 2021 Author. This work is licensed under the Creative Commons Attribution 4.0 International License.

## Introduction

Acute appendicitis is the commonest surgical condition among children, and the cause remains elusive (1). The appendix is a tubular structure at the caecum with an average length of 4.5 cm in neonates and 9.5 cm in adults (2). The base of the appendix is wider in neonates and infants; therefore, the chances of luminal obstruction are rare (2). We present an unusual case of a premature neonate with perforated appendicitis where diagnosis was made intraoperatively. This is an uncommon phenomenon with atypical presentations.

## Case report

Our patient was a premature male baby who was referred to us with presenting complaints of being born before term and had experienced difficulty in breathing since birth. This baby was a second twin, born vaginally and had an APGAR score of 8 and 10 in the 1st and 5th min, respectively. The mother reported that the pregnancy was uneventful. At admission, diagnosis of a preterm baby at 32 weeks of gestation age by Fin storm was made as well as a diagnosis of idiopathic respiratory distress syndrome. The patient was started on intravenous ampicillin and gentamycin to prevent

infections, started on oxygen therapy, and given intramuscular vitamin K to prevent hemolysis.

On the 5th day it was reported that the baby was breastfeeding poorly, had started to develop jaundice, had gradual abdominal distension and failure to pass stools. The patient was started on phototherapy for jaundice. An urgent plain erect abdominal X-ray was done which revealed free air under the right hemidiaphragm (Fig. 1).

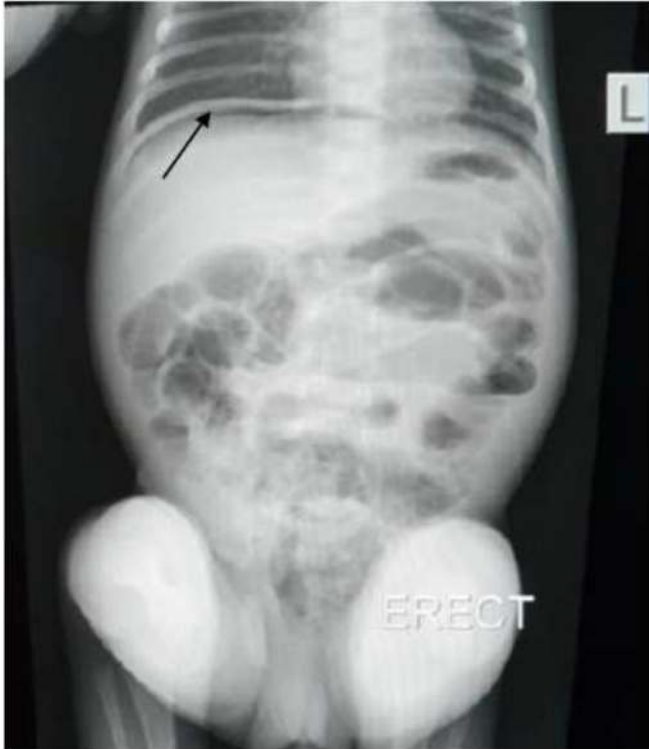

Figure 1. Plain abdominal X-ray showing free air (arrow) under right hemidiaphragm

The baby was then taken for an emergency laparotomy where intraoperatively approximately 25 mL of ascitic fluid contaminated with fecal matter and a hyperemic appendix with a perforation at its tip were found (Fig. 2). Other viscera were normal. An appendectomy was done and a biopsy taken for histopathology (which later confirmed appendicitis, Fig. 3). A thorough lavage of the abdominal cavity was done and an abdominal drain inserted. Postoperatively the baby developed surgical site infection on the 8th day that was dressed daily and

the patient recovered. On day 18 the patient was discharged from hospital. The baby was then seen at the neonatal outpatient clinic 2 weeks after discharge with good recovery and growth.

Written informed consent was obtained from the patient's mother for publication for this case report and accompanying images. A copy of the consent is available for review by the editor-in-chief of this journal.

## Discussion

Acute neonatal appendicitis is rare and the rate of perforation is higher in premature infants, resulting in peritonitis (2,3). The incidence of neonatal appendicitis has been reported to be 0.04–0.2% by El-Gohary (3); this is infrequent because of the wide appendix at the base, soft liquid diet, recumbent posture, and infrequent viral infections (3,4). El-Gohary also observes that of all reported cases, 25–50% occur in premature infants and this is due to their underdeveloped immunity, thin appendiceal wall, and indistensible caecum (3,5). Similar to our case, the diagnosis of perforation of the appendix is usually made operatively (3).

Primary neonatal appendicitis may present as an isolated entity where the etiology remains unclear, but secondary causes include Hirschsprung's disease, necrotizing enterocolitis, meconium plug syndrome, or cystic fibrosis (2,4–6). Complications such as perforation are due to the thin-walled appendix, and the infection spreads to the whole abdomen due to the small omentum and small capacity of the abdominal cavity; therefore, early diagnosis and management are important to reduce morbidity and mortality (4). Complications are also partly because of the atypical clinical presentations of acute appendicitis (and perforation) compared with what would be elicited in older children and adults (4–6). As reported by Gupta (4), different symptoms include vomiting and abdominal distension (as was present in our case). Pneumoperitoneum due to a perforated appendix was also present in our case (Fig. 1);

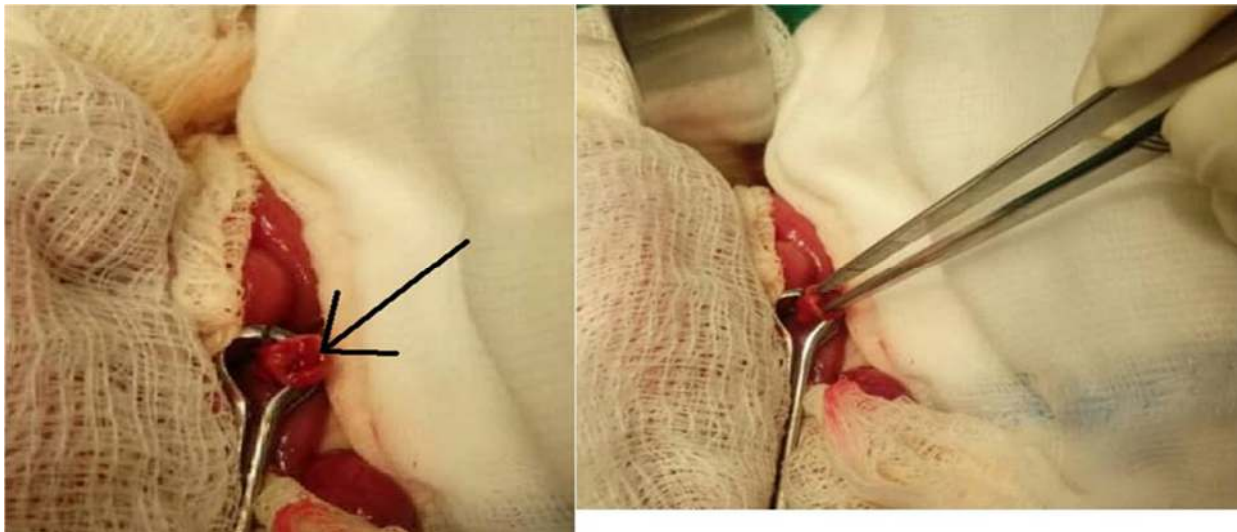


Figure 2. Photographs showing perforation at tip of appendix (arrow)

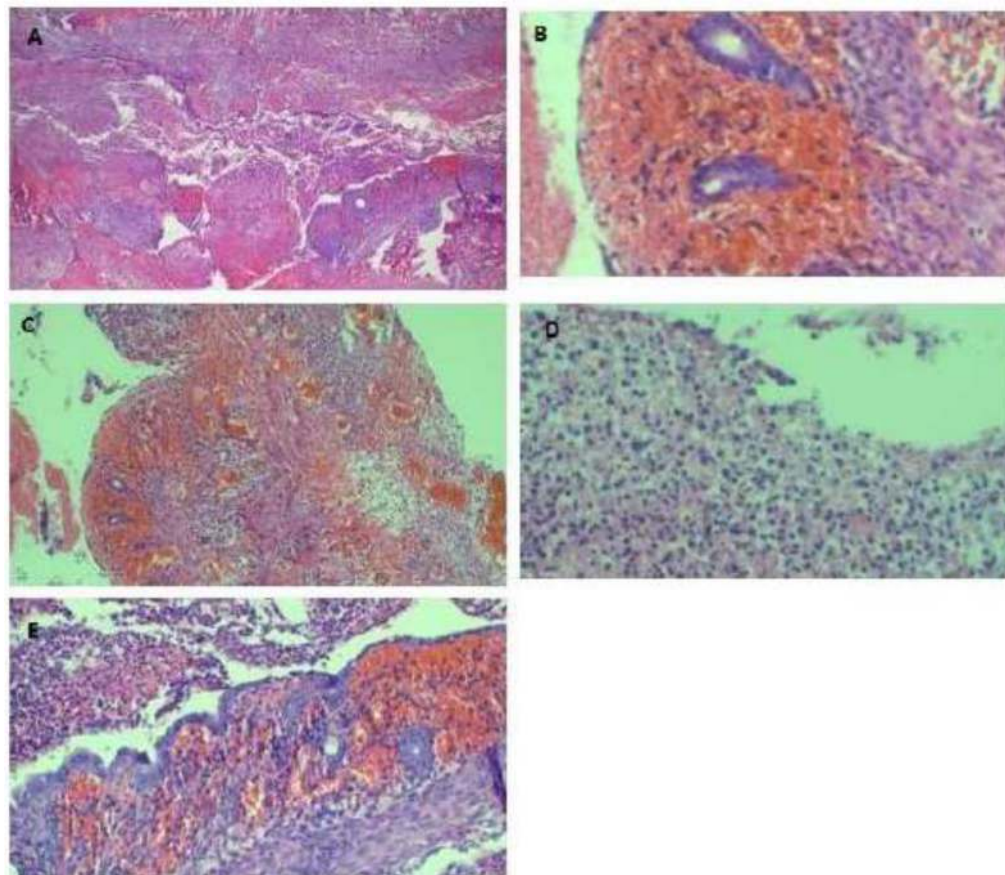


Figure 3. Histology showing inflammation of the appendix

A low magnification micrograph showing appendicular fibrinous necrotic mucosa. B. Section showing hemorrhage in a lamina propria and loss of the lining epithelium. C. This section shows congested submucosal blood vessels, edema, and atrophic glands. D. Higher magnification of the mucosa with neutrophil infiltrates within the lumen and the appendicular wall. E. The section demonstrates accumulation of inflammatory exudates (upper left) in the lumen consisting of neutrophil aggregates.

however, this is reported to be a rare finding by Ali et al. (7). The features of intestinal obstruction in our patient area result of peritoneal contamination causing intestinal ileus.

Surgery remains the preferred management for a perforated appendix, as was done in our case (6). Surgery includes appendectomy with an abdominal wash out, and the appendix taken for histological analysis to rule out other causes of perforation (2,6). Generally, the management outline of appendicitis is by clinically evaluating the signs and symptoms, with laboratory and radiological adjuncts; with the use of the Alvarado and pediatric appendicitis score scoring system, low-risk patients can be discharged with watchful waiting (2). C-reactive protein and computed tomography are considered gold standards with relatively high sensitivity and specificity to confirm clinical suspicion of appendicitis (1,8). Currently, laparoscopic surgery has become increasingly popular among pediatric surgeons along with other means such as percutaneous drainage of appendicular abscesses (2).

### Conclusion

Acute appendicitis is a rare entity in neonates and due to the uncommon presentation, diagnosis is difficult to make, delaying management, which may lead to high morbidity and mortality.

### Authors' contributions

JL came up with the idea, drafted and prepared the manuscript. AH, DW and JL performed the operation and reviewed patient's medical records. AS prepared and reported the radiological films. PA prepared the histology slides and the histopathology results, and RP and DM provided the technical input. All authors read and approved the final manuscript.

### Acknowledgment

The authors would like to thank the mother of the child for permission to share the information for further learning.

### References

1. Kumar J, Shepherd G, Abubacker M, et al. Trends in incidence of acute appendicitis in children. *Acad J Pediatr and Neonatol.* 2017;3(5):27–29.
2. Almaramhy HH. Acute appendicitis in young children less than 5 years. *Ital J Pediatr.* 2017;43(1):15.
3. El-Gohary MA. Neonatal appendicitis with perforation: A case report. *J PediatrSurg Case Rep.* 2014;2(7):353–354.
4. Gupta V, Sharma SB. Neonatal appendicitis with perforation: A case report and review of literature. *J Indian AssocPediatr Surgeons.* 2005;10(3):179.
5. Tumen A, Chotai PN, Williams JM, et al. Neonatal perforated appendicitis attributed to localized necrotizing enterocolitis of the appendix: A review. *J Neonatal Surg.* 2017;6(3):60.
6. Sabrina JD, Tan CW, Nallusamy M. Neonatal perforated appendicitis. *J PediatrSurg Case Rep.* 2018; 38:66–68.
7. Ali R. Perforated appendicitis with massive intraperitoneal free air in a two-month-old baby. *J Surg Pakistan (International).* 2015; 20:38–39.
8. Marzulli P, Germany C, Krauss BS, et al. Appendicitis in children less than five years old: A challenge for the general practitioner. *World J Limpidity.* 2015;4(2):19.