

Clinical Assessment of the Palmaris Longus – Accuracy of common tests

Authors: Kigera JWM¹ MBChB, MMed (Ortho), Mukwaya S² **Affiliation:** 1-Department of Orthopaedics, Makerere University, Kampala, Uganda/ 2- Mulago Paramedical Schools, Kampala, Uganda **Correspondence:** Dr. James Kigera, Orthopedic rehabilitation unit, PCEA Kikuyu Hospital, Kenya Email jameskigera@yahoo.co.uk

Abstract

Background: The Palmaris longus is a small vestigial muscle that is used as a tendon graft by surgeons. There are several tests described to detect the presence of the muscle clinically and there are variable opinions about which test is better. We set out to determine which of ten common tests brings out the tendon better.

Methods: We conducted a prospective study and subjected all participants to 10 tests to detect the presence of the Palmaris Longus. A negative test on all tests was judged to mean absence of the tendon while a positive result on any test was judged to be positive. Participants provided written informed consent and assent was sought from the next of kin in the case of those aged below 18 years. The study

was approved by the hospital ethics board and permission was granted by the school authorities.

Results; The Standard test described by Schaeffer was the most accurate while the open hand sign described by Bhattacharya was the least accurate.

Conclusion: Tests that incorporate wrist flexion, thumb abduction, opposition and finger flexion are best at bringing out the Palmaris tendon. Clinicians should be aware of this as they counsel patients who need tendon grafts. Studies aiming at detecting the presence of the Palmaris longus would be more accurate were they to use these tests

Introduction

The Palmaris longus (PL) is a vestigial muscle that has been shown to vary in occurrence in various populations. Numerous tests have been described to detect the presence of the Palmaris Longus in the living patient. The first such test was described by Schaeffer in 1909(1). Other tests were later described by Thompson, Mishra, Pushpakumar, Gangata and many others(2-5). The numerous tests rely on different wrist, hand and thumb motions and hence should have different accuracies in detecting the presence of the tendon. With numerous tests available for the surgeon it is important that it is clear to the clinician which tests bring out the tendon better. We thus set out to determine which of ten common tests used to detect the Palmaris Longus is better at demonstrating this tendon at the wrist.

Materials And Methods

We conducted a prospective study of students of the paramedical and nursing schools and of patients attending the orthopaedic surgical outpatient clinic. The subjects were recruited consecutively and subjected to 10 tests to detect the presence of the Palmaris Longus. The patients were examined by a resident in orthopaedics assisted by two students of clinical medicine (equivalent of physician assistant) who had all been trained on how

to identify the tendon in a sample of volunteers prior to the commencement of the study. A negative test on all tests was judged to mean absence of the tendon while a positive result on any test was judged to be positive. The prevalence of the PL and its relationship to handedness and sex in this population has previously been published (6). These tests have been previously described. In Schaeffer's test, volunteers were made to steady their forearm at 90° before opposing the thumb to the little finger with the wrist partially flexed(1) (Figure 1). Mishra's 1st test involved passive hyperextension of the metacarpophalangeal joints along with mild active flexion of the wrist(4) (Figure 2). In Thompson's test, a fist was made followed by flexing the wrist against resistance with the thumb flexed over the fingers(2) (Figure 3). In Pushpakumar's "two-finger sign" method, the subjects were made to fully extend the index and middle finger while the wrist and other fingers were fully flexed with the thumb opposed and flexed(5) (Figure 4). The Gangata test involves the subject resisting both thumb abduction and wrist flexion, with the thumb in an abducted position(3) (Figure 5). In Mishra's 2nd test, the subjects were asked to abduct the thumb against resistance with the wrist partially flexed(4) (Figure 6). The four finger sign is a combination of forced anteduction and pronation of the thumb at the first metacarpophalangeal joint with full extension of the second to fifth

Clinical Assessment of the Palmaris Longus – Accuracy of common tests

Kigera JWM, Mukwaya S

Table 1 Accuracy of the various tests

Test	Number Detected (Hands)	%
Schaeffer's (Standard) (1)	1526	98.1
Bhattacharya's Flexion(7)	1519	97.6
Pushpakumar(5)	1483	95.3
Lotus(7)	1480	95.1
Mishra's 2nd(4)	1470	94.6
Gangata(3)	1466	94.3
Four Finger(6)	1459	93.8
Mishra's 1st (4)	1428	91.8
Thompson(2)	1411	90.7
Open Hand(7)	1391	89.5

Table 2 Wrist and Finger Actions for the different tests

Test	Wrist	Thumb Abduction	Finger
	Flexion	/ Opposition	Flexion
Schaefer's (Standard) (1)	√	√	√
Mishra's 1st(4)	√		
Thompson(2)	√	√	√
Pushpakumar(5)	√	√	√
Gangata(3)	√	√	√
Mishra's 2nd(4)		√	
Four Finger(7)	√	√	
Lotus(8)	√	√	√
Open Hand(8)	√		
Bhattacharya's Flexion(8)	√		

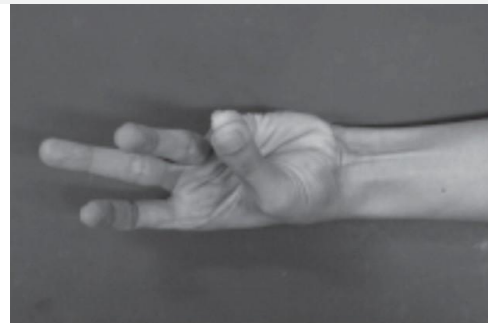


Figure 1 Scheaffer's Standard Test

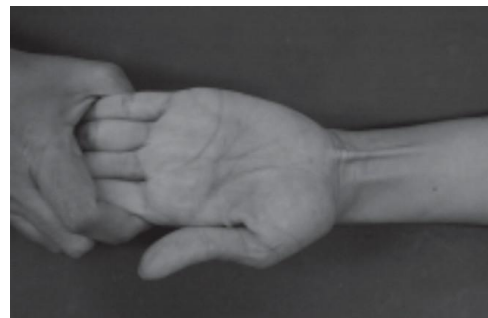


Figure 2 Mishra's 1st Test

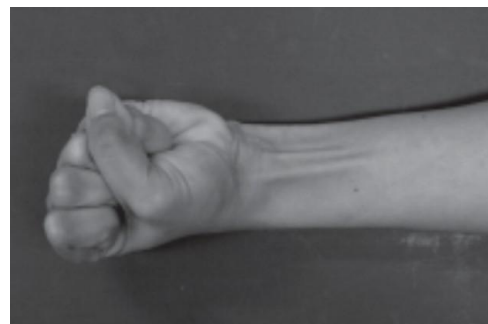

Figure 3 Thompson's Test

digits(7) (Figure 7). The Lotus sign is done by bringing the fingers and thumb together to form a cone (Figure 8) while in the open hand method, the patient is asked to fan out all the fingers and slightly flex the wrist (Figure 9). The Bhattacharya test is done wrist flexion against resistance(8)(Figure 10).

Patients with obvious hand and wrist deformities, previous hand and wrist injuries and previous surgery to the hand and/or wrist were excluded. Participants provided written informed consent and assent was sought from the next of kin in the case of those aged below 18 years. The study was approved by the hospital ethics board and

permission was granted by the school authorities.

Data was collected by a questionnaire and entered into Epidata program and exported to SPSS v 11.5 (SPSS Inc., Chicago, Illinois)

Results

We examined 800 subjects (1600 hands), the majority (76.1%) of whom were students and right handed (94.4%). There were 391 (48.9%) males and 409 (51.1%) females. The subjects' ages ranged from 12 to 70 years with a mean age of 25 years.

The overall prevalence of the Palmaris longus was 95.6%

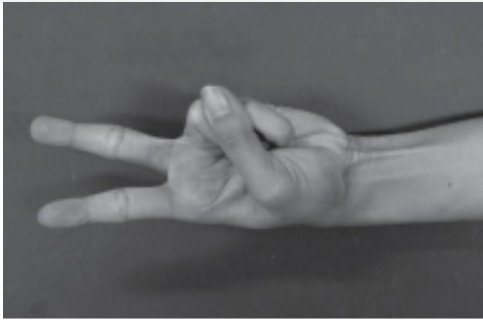


Figure 4 Pushpakumar's Test

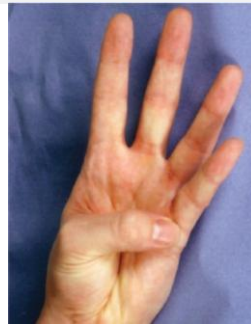

Figure 7 Oudit's Four Finger Test

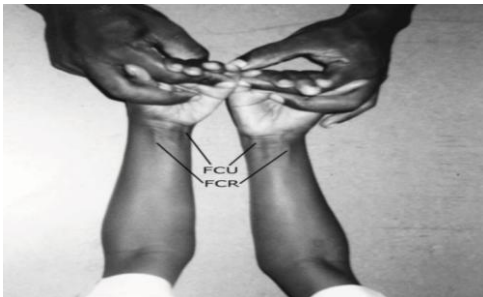


Figure 5 Gangata's Test

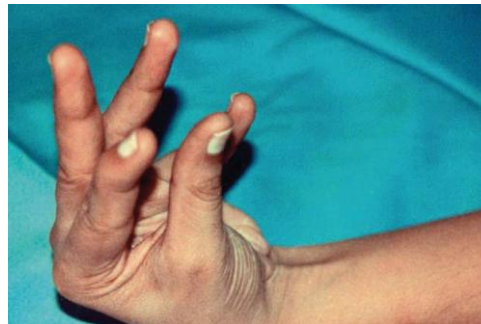

Figure 8 Lotus Sign (Bhattacharya)

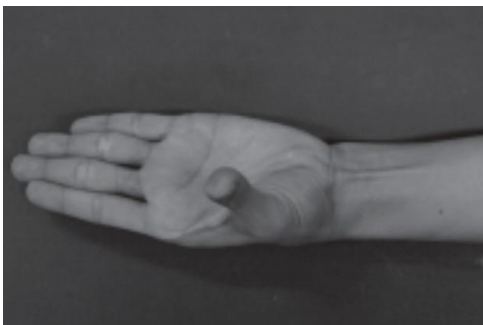

Figure 6 Mishra's 2nd Test

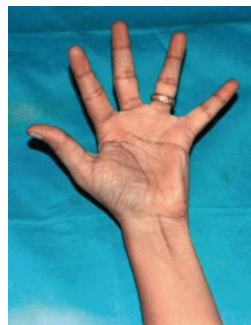

Figure 9 Open Hand Sign (Bhattacharya)

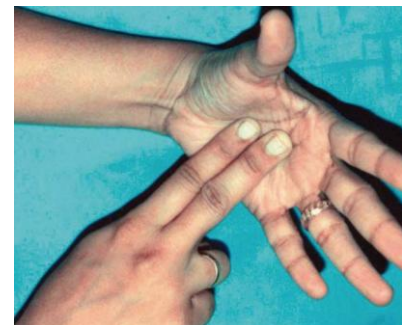

Figure 10 Wrist Flexion against resistance (Bhattacharya)

giving an absence rate of 4.4%. The Standard test described by Schaeffer was the most accurate while the open hand sign described by Bhattacharya was the least accurate (Table 1). The different tests use various wrist and finger movements to make the Palmaris longus tendon prominent (Table 2).

Discussion

The Standard test was able to detect 98.1% of all patients who had the tendon. This test works by wrist flexion, thumb abduction, opposition and finger flexion. The Open Hand test detected the least number of partici-

pants with the tendon. The test works by wrist flexion. The Palmaris Longus inserts into the palmar aponeurosis and is hence able to act as a wrist flexor and a tensor of the palmar aponeurosis. It is also reported to send a slip to the abductor pollicis brevis and hence plays a role in thumb abduction(9).

The tests with higher accuracies would be expected to be more useful in the clinical setting to detect the presence of the PL. Though all tests have accuracies of over 89%, our study has shown that tests that incorporate wrist flexion, thumb abduction, opposition and finger flexion are best at bringing out the Palmaris tendon.

Clinical Assessment of the Palmaris Longus – Accuracy of common tests

Kigera JWM, Mukwaya S

The limitation of the standard test is that it is difficult to demonstrate to the patient and difficult for the patient to perform. Clinicians should be aware of this as they counsel patients who need tendon grafts. Studies aiming at detecting the presence of the Palmaris longus would be more accurate were they to use these tests.

Conclusion

The Standard test best demonstrates the Palmaris longus and is recommended for clinical testing of the muscle.

Acknowledgments

We are greatly indebted to the authorities of Mulago Paramedical School for allowing us to conduct the study. We also acknowledge all study participants without who the study would not have come to fruition.

The Authors declare that they have no conflicts of interest, commercial associations, or intent of financial gain regarding this research

References

1. Schaeffer JP. On the variations of the palmaris longus muscle. *Anat Rec.* 1909;3:275–8.
2. Thompson JW, McBatts J, Danforth CH. Hereditary and racial variations in the musculus palmaris longus. *Am J Phys Anthropol* 1921;4:205–20.
3. Gangata H. The clinical surface anatomy anomalies of the palmaris longus muscle in the Black African population of Zimbabwe and a proposed new testing technique. *Clin Anat.* 2009 ;22(2):230-5.
4. Mishra S. Alternative tests in demonstrating the presence of palmaris longus. *Indian J Plast Surg.* 2001;34:12–4.
5. Pushpakumar SB, Hanson RP, Carroll S. The ‘two finger’ sign. Clinical examination of palmaris longus (PL) tendon. *Br J Plast Surg.* 2004;57:184–5.
6. Kigera JWM, Mukwaya S. Frequency of Agenesis of Palmaris Longus Through Clinical Examination - An East African Study. *PLoS ONE.* Dec 2011; 6(12):e28997.
7. Oudit D, Crawford L, Juma A, Howcroft A. The four-finger sign to demonstrate the palmaris longus tendon. *Plast Reconstr Surg.* 2005;116:691–2.
8. Bhattacharya V, Reddy GR. The palmaris longus tendon - rationality of the finger manoeuvres. *Br J Plast Surg.* 2005;58:419–21.
9. Gangata H, Ndou R, Louw G. The contribution of the palmaris longus muscle to the strength of thumb abduction. *Clin Anat.* May;23(4):431-6.