

Dismal salvage of testicular torsion: A call to action!

Authors: Maranya GA^{1,2} MBChB, MMed, Cert.Urol. (E.A.) FCS(ECSA), FCS-Urol, Mweru BJ² MBChB, MMed, Dip. Hosp. Manag. (Israel), Kinyanjui GM¹ MBChB, Al-Ammary AY¹ MBChB, MMed, Cert.Urol. (E.A.), FCS(ECSA) and Maganga HM¹ MBChB, MMed. **Affiliations:** 1- Coast Provincial Hospital, 2- Voi district hospital **Correspondence:** Dr. Maranya GA, P.O. Box 91066-80103, Mombasa, Kenya. Email: maranya@wananchi.com

Abstract

Background: Testicular ischaemia and infarction in cases of torsion depend on the duration and degree of twisting. Early evaluation and treatment are associated with high salvage reports.

Objective: To determine the salvage rates of testicular torsion in selected hospitals at the Coast Province of Kenya

Design: A retrospective study of patients managed for testicular torsion and related conditions between 1999 and 2011.

Setting: Coast Province General Hospital, Mombasa (1999 - 2008) and Moi District Hospital, Voi (2009 - 2011).

Patients and Methods: Case records of 44 patients were reviewed. Forty two underwent scrotal explorations while two patients with bilateral testicular loss due to torsion had no surgery. Patients were reviewed for age,

operative diagnoses, testicular salvage, surgical procedures performed and recurrence of symptoms.

Results: Of 29 patients operated for acute testicular torsion, four had viable testes (salvage rate of 14%). Seven patients had bilateral orchidopexy for intermittent testicular torsion. Three patients who had missed torsions with resultant total testicular atrophy, had orchidopexy of the contralateral testes. At scrotal exploration 2 patients with epididymorchitis and one patient with a torsion of appendix testis that was excised, were not subjected to orchidopexy. There was no occurrence of torsion after orchidopexy.

Conclusion: Testicular torsions were associated with low salvage rates. Increased public awareness coupled with clinician, parental, teacher, teenage and adult male education with respect to the consequences of acute scrotal pain is warranted.

Introduction

Testicular ischaemia and infarction in cases of torsion depend on the duration and degree of twisting (1-4). Irreversible ischaemia usually starts after 6 hours. In 10 hours, 80% of the testes are infarcted, while after 24 hours nearly 100% are necrotic (3). Early evaluation and treatment of acute hemiscrotal pain is important for salvage. In intermittent torsion, the presentation is with recurrent episodes of acute unilateral scrotal pain which usually resolves spontaneously within a few hours (5-7). Missed testicular torsion with a totally atrophied testis is a late sequel of acute torsion. Although other causes of acute scrotal pain including epididymorchitis, strangulated inguinal hernia, torsion of testicular appendages, testicular trauma and idiopathic scrotal oedema (3, 5) are important, a clinical suspicion of torsion must lead to immediate surgical scrotal exploration (5, 8-11). This study describes testicular torsion at two coastal hospitals in Kenya and the associated salvage level.

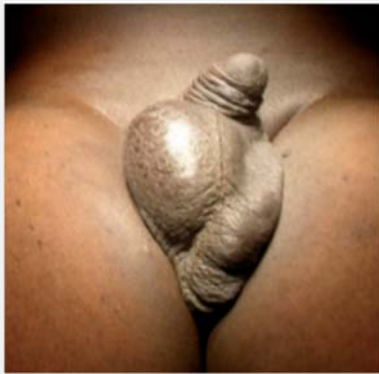Patients and Methods

This retrospective study was carried out at two hospitals at

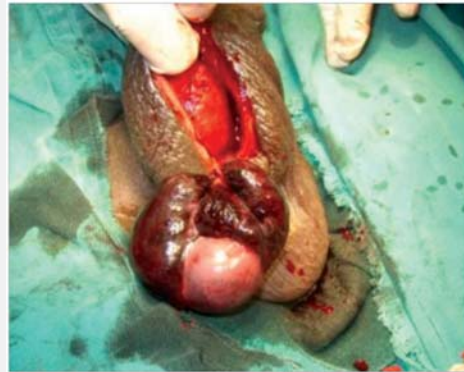the Coast Province of Kenya over a 12 year period - Coast Province General Hospital, Mombasa (1999 - 2008) and Moi District Hospital, Voi (2009 - 2011). Case notes of all patients managed for testicular torsion at the two hospitals and a few patients followed up privately by the first author were reviewed. Data abstracted included patient demographics, clinical presentation, operative diagnoses, procedures performed and outcome. In all cases where orchidopexy was required, the scrota were explored through the median raphe incision and 3 point fixation (through the upper pole, body and lower pole tunica albuginea) to the median septum performed. (Figure 1).

Results

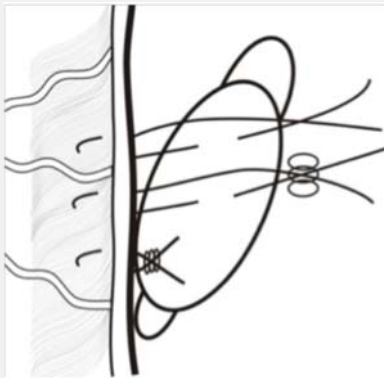
Evaluation of the patients was mostly clinical. A 20 year old man with sequential acute scrotal pain 3 years apart, from 7 years previously, only sought herbal therapy resulting in loss of both testes. A 70 year old man who had lost the right testis in association with a sports injury many years earlier, presented with left scrotal swelling a month after an episode of acute pain. He had Doppler ultrasonography that



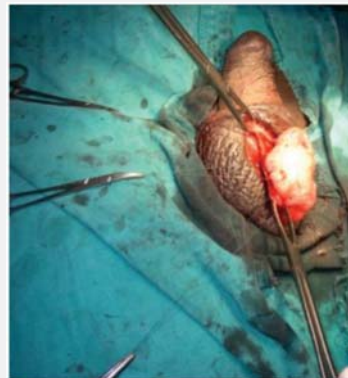a)



b)



c)



d)

Figure 1: A 47 year old man, a week after acute right scrotal pain. (a) Swollen, elevated right testicle. (b) Gangrenous right testis. (c) Illustration of the 3 point fixation technique. (d) Orchidopexy sutures in place.

showed no circulation to the testis. There was no surgical intervention in these 2 patients.

Forty two patients were operated for testicular torsion or torsion related pathology (table 1). Their ages ranged between 3 months and 47 years with a mean of 23 years. At surgical exploration two patients aged 12 and 17 years had epididymorchitis. One patient had excision of a twisted infarcted appendix testis. Orchidopexy was not done in these patients. Of the 29 patients with acute testicular torsion (mean age 17 years), 25 (86%) had an infarcted testis. Orchiectomy and contralateral orchidopexy was performed (Figure 1). Torsion with infarction in a three month old infant was in a left undescended testis located in the groin. In four patients (14%) the testes were viable; so detorsion and bilateral orchidopexy was done (Fig. 1).

Seven patients with intermittent testicular torsion had elective bilateral orchidopexy. In three patients with missed testicular torsion, contralateral orchidopexy was done (Table 1).

There was no recurrence or occurrence of torsion after orchidopexy.

Discussion

In this study, patients with acute scrotal pain suggestive of testicular torsion presented late. The evaluation was mainly clinical and only 14% of testes were deemed viable at exploration. The mean age of patients with confirmed acute testicular torsion at operation, was 17 years, in tandem with many authors who report the teens; 12-18 years as the commonest age, peaking around 13 years (2-4, 11). As in previous reports (8-10), clinical assessment alone was the tool used to diagnose acute testicular torsion. Although adjunct imaging may be used in this condition, this may delay treatment (8-10). Some disregard Doppler ultrasonography for being operator dependent and sometimes demonstrating blood flow in the initial phase of torsion, leading to delay in diagnosis (5). These viewpoints maximize salvage. Doppler ultrasonography may be used if this does not delay treatment and in equivocal cases (1, 12, 13). The low salvage rate of 14% contrasts with reports from the West. Tajchner et al. have reported a salvage rate of 98% for acute testicular torsion from a district hospital in Ireland (8). Murphy et al (9) reported 71% salvage, while Cummings had salvage of 70% in patients under 21 years and

Dismal salvage of testicular torsion: A call to action!

Maranya GA, Mweru BJ, Kinyanjui GM, Al-Ammary AY, Maganga HM

Age	Diagnosis	Surgical procedure	Number
Range: 3 months – 47 years	Acute testicular torsion: infarcted testis	Ipsilateral orchidectomy and contralateral orchidopexy	25
Mean: 23 years	Acute testicular torsion: viable testis	Detorsion and bilateral orchidopexy	4
	Intermittent testicular torsion	Bilateral orchidopexy	7
	Missed testicular torsion	Contralateral orchidopexy	3
	Epididymorchitis	Scrotal exploration alone	2
	Torsion appendix testis	Excision of appendage	1
	Total		42

Table 1: Operations performed for testicular torsion and acute scrotal conditions mimicking torsion.

41% above 21 years (14). Our results are however consistent with others from the region (3) where pre-hospital delays are the major factor.

When infarction or viability of the torsed testis is not certain, testicular tissue bleeding is assessed (15). This will determine whether orchidectomy or orchidopexy of the respective testis will be done. Marginal testes that are saved can theoretically lead to infertility (4). Breakdown of the blood-testis barrier in such testes may lead to production of antisperm antibodies, damaging both testes, resulting in atrophy. In the patients with epididymorchitis and torsion of appendix testis, orchidopexy was not done as there is no proven benefit (16). The patients presenting with intermittent acute scrotal pains had fixation to prevent acute testicular torsion or progressive atrophy that may lead to impaired fertility (6). Patients with missed torsion had contralateral orchidopexy which is the standard procedure for solitary testes (3).

There was no recurrence or incident of testicular torsion on follow up after orchidopexy, an attribute of the procedure used. We prefer fixation with non-absorbable monofilament suture (1, 3, 11,16). Use of absorbable suture material is associated with increased recurrent torsion (3, 17).

In conclusion, this study reveals a high rate of testicular loss in acute testicular torsion, missed torsion and sequential torsion and significant testicular atrophy in intermittent testicular torsion. These sequelae can be mitigated by enhanced public awareness regarding the potential consequences of acute scrotal pain in addition to clinician, parental, teacher, teenage and adult male education.

Acknowledgement

I sincerely thank Jason Mwawana for the computer work and drawings and the Provincial Director of Medical Services, Coast Province, Kenya for authority to publish this article.

References

1. Kapoor S. Testicular torsion: a race against time. *Int. J. Clin. Pract.* 2008; 62: 821-827.
2. Pentylala S, Lee J, Yalamanchili BA, et al. Testicular torsion: a review. *J. of Lower Genit. Tract Dis.* 2001; 5: 38-47.
3. Visser AJ, Heyns CF. Torsion of the testis and its appendages: diagnosis and management. *Afr. J. Urol.* 2004; 10: 85-91.
4. Lavallee ME, Cash J. Testicular torsion: evaluation and management. *Curr. Sports Med. Reports.* 2005; 4: 102-104.
5. Molokwu CN, Somani BK, Goodman CN. Outcomes of scrotal exploration for acute scrotal pain suspicious of testicular torsion: a consecutive case series of 173 patients. *BJU Int.* 2010; 107: 990-993.
6. Eaton HS, Cendron MA, Estrada CR, et al. Intermittent testicular torsion: diagnostic features and management outcomes. *J. Urol.* 2005; 174: 1532- 1535.
7. Kamaledeen S, Surana R. Intermittent testicular pain: fix the testes. *BJU. Int.* 2003; 91: 406-407.
8. Tajchner L, Larkin JO, Bourke MG, et al. Management of the acute scrotum in a district general hospital: 10 year experience. *Scient. Worl. J.* 2009; 9: 281-286.
9. Murphy FL, Fletcher L, Pearse P. Early Scrotal exploration in all cases is the investigation and intervention of choice in the acute paediatric scrotum. *Paediatr. Surg. Int.* 2006; 22: 413-416.
10. Soccorso G, Ninan GK, Rajimwale A, et al. Acute scrotum: is scrotal exploration the best management? *Eur. J. Paed. Surg.* 2010; 20: 312-315.
11. Mongiat-Artus P. Torsion of the spermatic cord and testicular annexes. *Annales d' urologie.* 2004; 38: 25-34.
12. Gunther P, Schenk JP, Wunsch R, et al. Acute testicular torsion in children: the role of sonography in the diagnostic workup. *Eur. Radiol.* 2006; 16: 2527-2532.
13. Waldert M, Klatt T, Schindbauer J, et al. Colour Doppler sonography reliably identifies testicular torsion in boys. *Urology.*

- 2010; 75: 1170-1174.
14. Cummings JM, Boullier JA, Sekhon D, et al. Adult testicular torsion. *J. Urol.* 2002; 167: 2109- 2110.
 15. Arda IS, Ozyalali F. Testicular tissue bleeding as an indicator of gonadal salvageability in testicular torsion surgery. *BJU. Int.* 2001; 87: 89-92.
 16. Pearce T, Islam S, O' Flynn KJ. Suspected testicular torsion: a survey of clinical practice in North West England. *J. Roy. Soc. Med.* 2002; 95: 247.
 17. Sells H, Moretti KL, Burfield GD. Recurrent torsion after previous testicular fixation. *ANZ. J. Surg.* 2002; 72: 46-48.