

**ORIGINAL ARTICLE**

Egypt. J. Med. Hum. Genet. Vol. 10, No. 1, May, 2009

**Prenatal diagnosis of aneuploidy among a sample of Egyptian high risk pregnancies**Rabah M. Shawky<sup>1</sup>, Eman A. Zaky<sup>1</sup>, Ezzat S. El-Sobky<sup>1</sup>, Ahmad R. Ramy<sup>2</sup> and Sherif Y. Omer<sup>3</sup>.<sup>1</sup>Pediatric Department, <sup>2</sup>Obstetric and Gynecology Department, Ain Shams University, <sup>3</sup>Medical Genetics Center**ABSTRACT**

**Background:** A number of studies have shown that aneuploidies of only 5 chromosomes (13, 18, 21, X and Y) account for about 65% of all chromosomal abnormalities and 95% of chromosomal aberrations cause live-born birth defects. Fluorescent in-situ Hybridization (FISH) has been found to be highly effective for rapidly determining the number of specified chromosomes in interphase cells.

**Patients and Methods:** Prenatal diagnosis was performed on 40 high risk pregnancies chosen from mothers attending the Antenatal Clinic of Ain Shams University Medical genetics Center (ASUMGC). Early amniocentesis for conventional karyotype analysis of cultured amniocytes and interphase FISH studies of uncultured amniocytes for rapid detection of aneuploidies of chromosomes (13, 18, 21, X and Y) was performed.

**Results:** Normal karyotype was detected in 35 cases (87.5%) and in 4 cases (10%) chromosomal abnormalities were detected by conventional karyotype. However, culture failed in one case (2.5%) due to culture contamination. FISH assay confirmed the cytogenetic findings, for the probes used, on interphase nuclei in all cases analysed, except three cases of structural chromosomal abnormalities: [46,XX, add 21(q22); 46,XX, t(5;20) mat, 46,XY, inv(9) (p11;q13)] paternal. In one case of culture contamination, FISH analysis was useful in excluding the aberrations of specific chromosomes 13, 18, 21, X and Y on the uncultured/interphase nuclei.

**Conclusion:** Molecular cytogenetic technique of FISH is very useful in urgent cases of prenatal diagnosis where it can be used on uncultured amniocytes for rapid and accurate detection of common aneuploidies.

**Key Words:**

Aneuploidy, prenatal diagnosis, chromosomal aberrations, amniocentesis, FISH.

**Corresponding Author:**Rabah M. Shawky  
E-mail: shawkyrabah@yahoo.com**INTRODUCTION**

Aneuploidy is defined as numerical abnormalities that involve gain or loss of one or more

chromosomes. Loss of a single chromosome results in monosomy while gain of one or two homologous chromosomes

is referred to as trisomy and tetrasomy, respectively.<sup>1</sup>

A number of studies have shown that aneuploidies of only 5 chromosomes (13, 18, 21, X and Y) account for about 65% of all chromosomal abnormalities and 95% of chromosomal aberrations causing live-born birth defects.<sup>2</sup>

In another study the incidence of all chromosomal abnormalities in very high risk pregnancies is relatively high with aneuploidies 13, 18, 21, X and Y being the most common finding (76%).<sup>3</sup>

Prenatal diagnosis of chromosomal anomalies employs a variety of techniques either as a screening procedure for relatively prevalent disorders or as a diagnostic procedure for known familial conditions. The former identifies an increased likelihood of a fetal abnormality in an apparently normal pregnancy, whereas the latter confirms or refutes the existence of an actual anomaly in a fetus believed to be at increased risk.<sup>4</sup>

Currently available prenatal non-invasive screening tests include ultrasonography and various biochemical tests (maternal marker screening), while chorionic villus sampling, amniocentesis and fetal blood sampling are invasive diagnostic procedures. At present, these invasive procedures are considered as gold standards for the diagnosis of chromosomal anomalies or other genetic diseases.<sup>5</sup>

Fluorescent in-situ Hybridization (FISH) relies on the unique ability of a portion of single stranded DNA, known as a probe to anneal or hybridize with its complementary target sequence wherever it is located in the genome.

Probes can be prepared for a whole chromosome. When such probes are applied to a metaphase spread they will hybridize to or paint all material originating from a particular chromosome<sup>1</sup>. FISH has been found to be highly effective for rapidly determining the number of specified chromosomes in interphase cells.<sup>6</sup>

### **AIM OF THE STUDY**

---

The study aimed at determining the percentage of aneuploidy in a sample of high risk pregnancies for prenatal diagnosis and comparing the results of conventional karyotype analysis and FISH as two different modalities of prenatal diagnosis as regards rapidness of obtaining the results and their effectiveness in diagnosis of aneuploidy.

### **SUBJECTS AND METHODS**

---

Prenatal diagnosis was performed in 40 high risk pregnancies chosen randomly from mothers attending the Antenatal Clinic of Ain Shams University Medical Genetics Center (ASUMGC), selection criteria were as follows: advanced maternal age (maternal age above 35 years), previous child with chromosomal abnormality, fetal abnormality suggestive of aneuploidy detected through ultrasound examination, parental chromosomal abnormality and previous recurrent abortions.

For all enrolled cases the following were done: Detailed history taking, family pedigree construction, first and second-trimester ultrasound assessment, early amniocentesis for conventional karyotype analysis of cultured amniocytes and interphase FISH studies of uncultured amniocytes.

The amniotic fluid was divided into two parts, one part was used for interphase FISH and the other was used to establish two primary cultures for conventional cytogenetic analysis. Standard culture and harvest methods, described by Rooney and Czepulkowski<sup>7</sup> were used to obtain chromosome preparations. G-banding on all the samples was performed using the method of Seabright.<sup>8</sup>

The FISH analyses were performed on uncultured amniocytes, using DNA probes specific for chromosome 13,18, 21, X, Y (Aneuvision, Vysis, Downers Grove, Ill., USA).

## RESULTS

The results of present study could be summarized in the following points:

### - Age distribution among the enrolled mothers:

In 34 cases maternal ages were less than 35 years (85%) and in 6 cases maternal age was above 35 years (15%) for whom age distribution were as follows: 3 cases were from 36 to 37 years (7.5%) and 2 cases were from 38 to 39 years (5%) and one case was above 39 years (2.5%).

### - Indications of amniocentesis for the enrolled mothers:

From all 40 enrolled mothers, 31 mothers (77.5%) had a previous child with a chromosomal abnormality of which 28 mothers (70%) had a pervious Down syndrome (Non-disjunction type) and one mother (2.5%) had a pervious child with trisomy 18 and 2 mothers (5%) had a pervious child with structural chromosomal abnormalities [46, XX, der

(15)t(15; 21) mat, 46,XX, t(5;20) mat]. Advanced maternal age (above 35years) was indication for aminocentesis in 6 mothers (15%) and in 2 cases (5%) indication was abnormal ultrasound scan suggestive of aneuploidy [increased nucheal transleucency (3mm) in one case and huge cystic hygroma in the other] and in one case (2.5%) indication for aminocentesis was paternal chromosomal abnormality [46, XY, inv (9) (p11;q13)].

### - Timing of amniocentesis:

Amniocentesis was performed between 14 to 18 weeks of gestation, (Table 1).

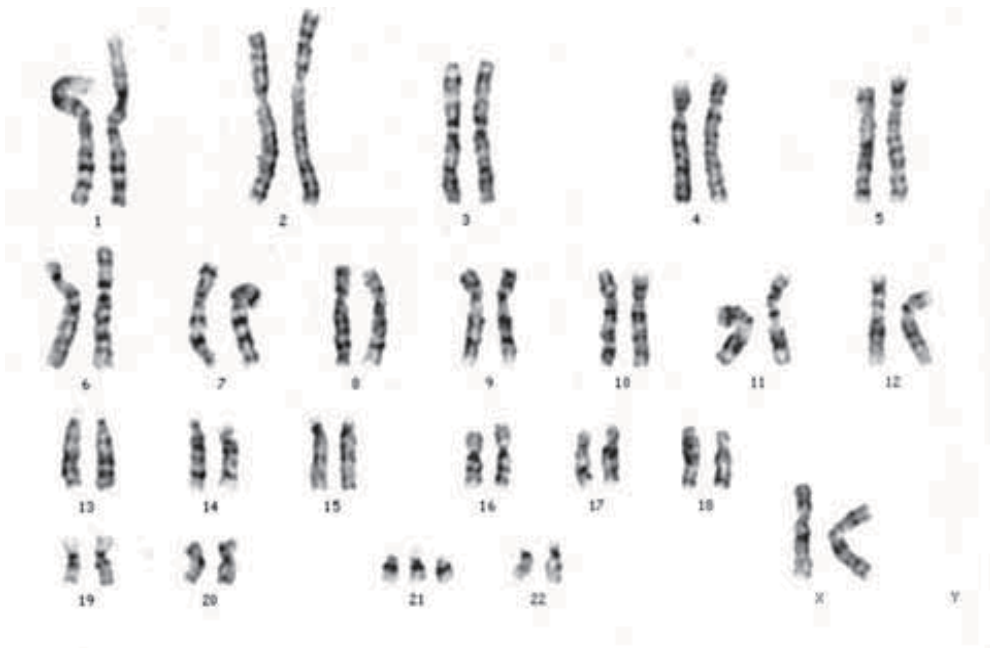
**Table 1:** Timing of amniocentesis.

Timing of amniocentesis	No.	%
14-15 weeks	33	82.5
16-17 weeks	6	15
18 weeks	1	2.5

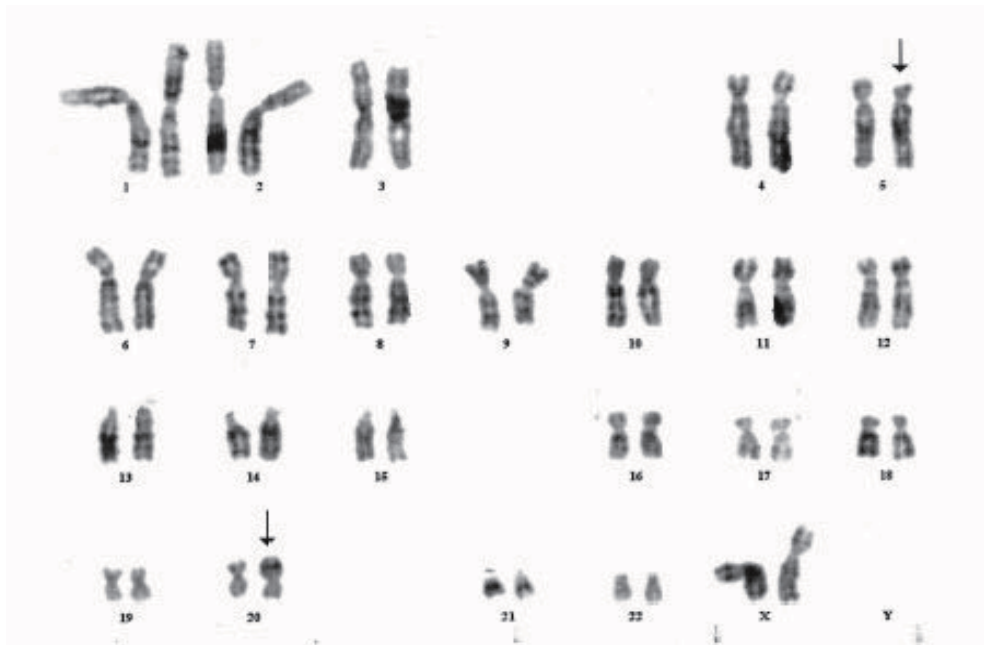
### Results:

#### - Results of conventional karyotyping of cultured aminocytes for the enrolled mothers:

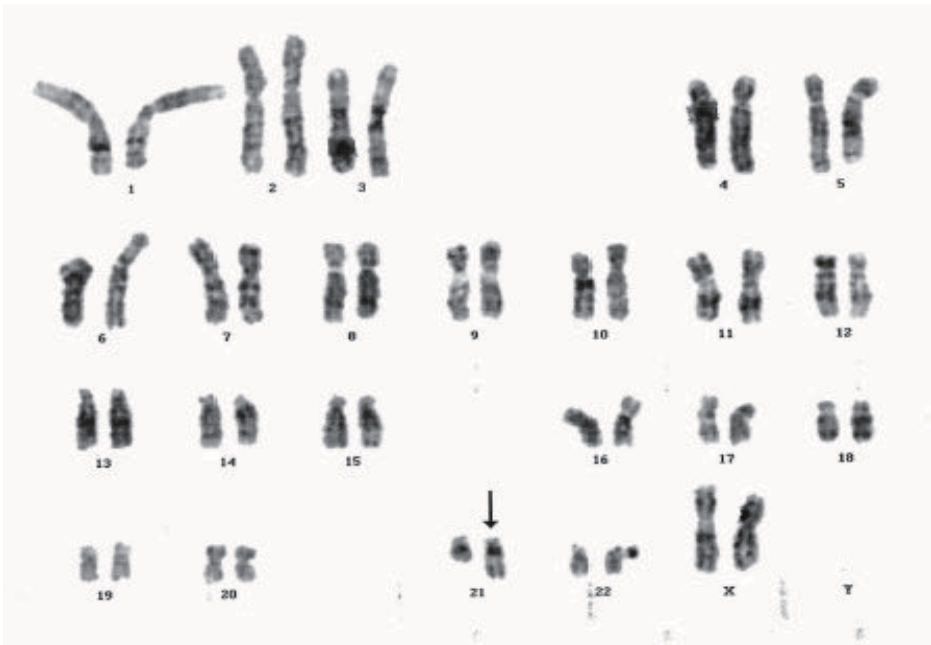Normal karyotype was detected in 35 cases (87.5%) and in 4 cases (10%) the following abnormalities were detected: One case (2.5%) [47, XX, +21] (Figure. 1) and one case (2.5%) [46, XX, t (5;20) mat] (Figure. 2), one case (2.5%) [46, XX add 21 (q22)] (Figure. 3) and one case (2.5%) [46, XY, inv (9) (q11;q13)] (Figure. 4). The culture failed in one case (2.5%), (Table 2).



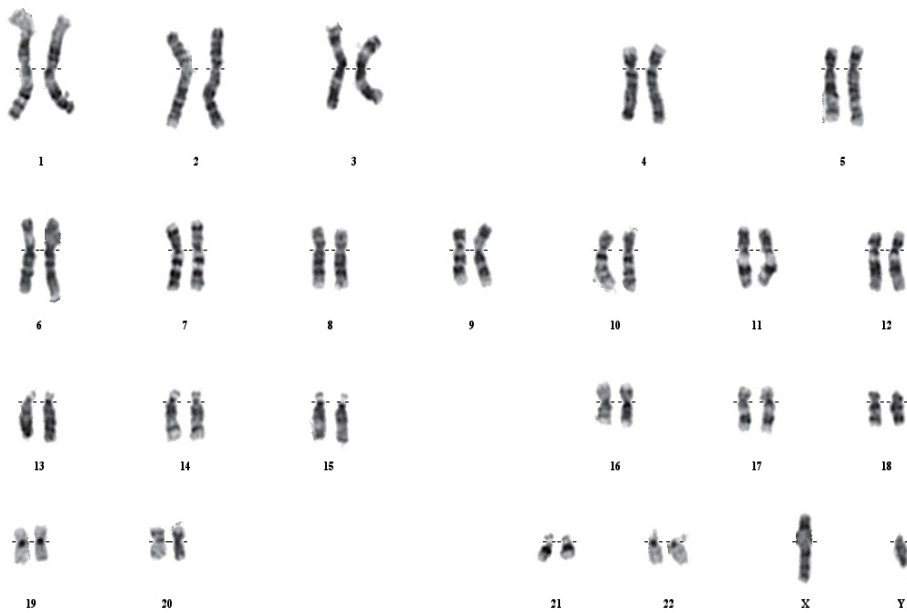
**Fig. 1:** Conventional karyotype of cultured amniocytes showing 47, XX, + 21 (Down syndrome).



**Fig. 2:** Conventional karyotype of cultured amniocytes Showing 46, XX, t(5;20)(p13;p13).



**Fig. 3:** Conventional karyotype of cultured amniocytes showing 46, XX, add (21) (q22).



**Fig. 4:** Conventional karyotype of cultured amniocytes showing 46, XY, inv(9) (p11;q13).

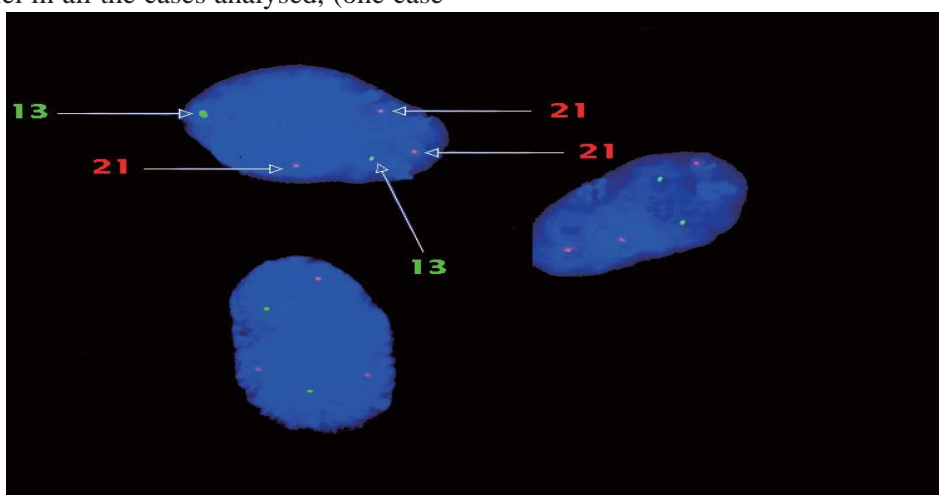
**Table 2:** Results of conventional karyotyping of cultured amniocytes for enrolled mothers.

Indication of amniocentesis	The results of conventional karyotype			
	No.	Failure	Normal	Abnormal
				No. Type of abnormality
<b>Previous child with chromosomal abnormalities</b>	<b>31</b>	<b>1</b>	<b>27</b>	<b>3</b>
• Previous child with Trisomy 21	28	1	26	1 47, XX, +21
• Previous child with Trisomy 18	1	-	1	-
• Previous child with der(5)t(5;20)mat.	1	-	-	1 46,XX, t(5;20)mat.
• Previous child with der (15)t(15; 21)mat.	1	-	-	1 46,XX,add 21 (q22)
<b>Advanced maternal age</b>	<b>6</b>	<b>-</b>	<b>6</b>	<b>-</b>
<b>Abnormal US scan suggestive of aneuploidy</b>	<b>2</b>	<b>-</b>	<b>2</b>	<b>-</b>
• Increased nuchal translucency	1	-	1	-
• Huge cystic hygroma	1	-	1	-
<b>Parental chromosomal abnormality</b>	<b>1</b>	<b>-</b>	<b>-</b>	<b>1</b>
• Paternal inv (9) (p11;q13)	1	-	-	1 46,XY, inv (9)
<b>Total</b>	<b>40</b>	<b>1</b>	<b>35</b>	<b>4</b>

**- Results of FISH for the enrolled mothers:**

Results of FISH confirmed cytogenetic findings of conventional karyotyping, for the probes used, on interphase nuclei in all the cases analysed, (one case

with trisomy 21) (Figure. 5) except three cases of structural chromosomal abnormalities [46,XY, inv(9p11;q13)-46, XX, t(5;20) (q13;p13) - 46,XX, add (21) (q22)] where this FISH protocol was not designed to detect them.



**Fig. 5:** FISH analysis of uncultured amniocytes showing trisomy 21 and normal number for chromosome 13.

## DISCUSSION

Prenatal diagnosis using amniotic fluid for analyzing chromosomal disorders has become a standardized approach for certain indications in highly developed countries worldwide. The amniotic fluid contains fetal cells, which have to be cultivated. After culture times of 1–3 weeks, a cytogenetic analysis can be performed. This time-consuming procedure may be quite distressful in many situations, not only for the pregnant woman but also for the gynecologist. Because cell cultivation is time consumptive, many attempts have been made to analyse chromosomes without prior cell culture. As a first step in this direction, a rapid partial karyotype analysis can be performed by using fluorescence in situ hybridisation (FISH) with chromosome specific DNA probes on uncultured amniotic cells. Hereby up to 90% of all chromosomal disorders expected in the second trimester can be discovered theoretically within 24 h if DNA probes specific for chromosomes 21, 18, 13, X and Y are used.<sup>9</sup>

Rapid detection of prenatal aneuploidy using interphase FISH on a large scale were successfully initiated by Klinger et al.<sup>10</sup> and Ward et al.<sup>11</sup>. Their studies constituted the basis of the clinical protocols for the application of FISH for prenatal diagnosis. However, the foregoing two and most of the other studies<sup>11–17</sup> had several obstacles that delayed wide acceptance of FISH as a highly reliable method for routine prenatal diagnosis. Some authors used probes prepared by their own laboratories.<sup>10,11</sup>

Most cytogenetic laboratories are not qualified and equipped to synthesize DNA probes and to perform necessary quality control studies. Furthermore,

the assay conditions should be modified for each set of probes because the quality and characteristics of the probes are the key factors for successful FISH analysis.<sup>18</sup>

In the current study, indications for prenatal diagnosis in a sample of Egyptian high risk pregnant woman for aneuploidy were as follow: Pervious child with chromosomal abnormalities in 31 cases (77.5%), of them 28 cases (70%) had pervious child with Down syndrome, one case (2.4%) had pervious child with trisomy 18 and 2 cases (4.7%) with history of pervious child with structural chromosomal abnormalities [one with t (5; 20), balanced] and the other with der (15), t (15; 21) (unbalanced)] in both cases peripheral blood lymphocytic culture were done for both parents. In both cases the mother was found to be a balanced carrier for the same translocation. Other indications was advanced maternal age in 6 cases (15%), abnormal US suggestive of aneuploidy in 2 cases (5%) and paternal chromosomal abnormality in one case (2.5%).

The criteria for abnormal ultrasound scan included 1<sup>st</sup> and 2<sup>nd</sup> trimester abnormalities. During the 1<sup>st</sup> trimester, cystic hygroma and hydrops were considered as major markers of fetal aneuploidy<sup>19</sup>. Other structural abnormalities considered as potential markers of fetal aneuploidy during the 1<sup>st</sup> trimester were also searched for including increased nuchal translucency, anomalies of the central nervous system as holoprosencephaly, omphalocele, extremity abnormalities and major cardiac defects. During the 2<sup>nd</sup> trimester, cystic hygroma and hydrops were also considered as major markers of fetal aneuploidy. Other structural abnormalities including

nuchal thickening, echogenic bowel, short extremities, pyelectasis, intracardiac echogenic focus, ventricular dilatation, choroid plexus cyst, clinodactyly, wide pelvic angle were considered as potential markers of fetal aneuploidy during the second trimester.<sup>20</sup>

Out of the 40 studied cases, there were only two cases that showed U/S abnormalities. The 1<sup>st</sup> trimester ultrasonography of one of them revealed increased nuchal translucency (3mm), for which the result of conventional karyotype and FISH were normal. In the other case, huge cystic hygroma was detected by 2<sup>nd</sup> trimester ultrasonography and referred for possible prenatal diagnosis of aneuploidy but the result of conventional karyotype and FISH were normal for both of them.

As regards increased nuchal translucency, a series of screening studies in high-risk pregnancies were carried out; these involved measurement of nuchal translucency thickness immediately before fetal karyotyping, mainly for advanced maternal age. Pandya et al.<sup>21</sup> examined a total of 1273 pregnancies and reported that the nuchal translucency thickness was above the 95<sup>th</sup> centile of the normal range in about 80% of trisomy 21 fetuses. Similar findings were obtained in an additional four studies of pregnancies undergoing first-trimester fetal karyotyping<sup>22-25</sup>. However, in another study involving 1819 pregnancies, nuchal translucency thickness of equal to or greater than 3mm identified only 30% of the chromosomally abnormal fetuses and the false-positive rate was 3.2%.<sup>26</sup>

As regards cystic hygroma, Bronshtein et al.<sup>27</sup> found that in comparison with non-septated cystic spaces (nuchal

thickness), septated cystic hygromas were much more likely to be persistent (56% versus 2%) and associated with aneuploidy (72% versus 5.6%). Nadel et al.<sup>28</sup> found that Cystic hygromas were associated with fetal aneuploidy in approximately 75% of cases, of which Turner's syndrome (45, X) was most common and that fetuses with Turner's syndrome had larger cystic hygromas than those with trisomy 18, trisomy 21, or normal karyotype.

In the current study, the FISH assay confirmed the cytogenetic findings, for the probes used, on interphase nuclei and in metaphase spreads in all the cases analysed, except three cases of structural chromosomal abnormalities [46, XX, add (21)q (22), 46, XX, t(5;20) mat, 46, XY, inv (9) (p11;q13)] paternal for which this FISH protocol was not designed to detect. In one case of culture contamination, FISH analysis was useful in excluding the aberrations of specific chromosomes 13, 18, 21, X and Y on the uncultured/interphase nuclei. One case of Down syndrome was identified by interphase FISH and also confirmed by cytogenetic analysis. The study was also designed to compare the FISH assay with conventional cytogenetic analysis and on this basis to evaluate the clinical utility of the assay for prenatal diagnosis of aneuploidies.

Several studies demonstrated an extremely high concordance rate between results of FISH and standard cytogenetics (99.8%) for prenatal diagnosis of aneuploidy for chromosomes 13, 18, 21, X and Y that the AneuVysion assay is designed to detect.<sup>29</sup>

In a study conducted by Jobanputra et al.<sup>30</sup> prenatal diagnosis was carried out in 88 high-risk pregnancies using FISH



and cytogenetic analysis. Multicolour commercially available FISH probes specific for chromosomes 13, 18, 21, X and Y were used. The results of FISH were in conformity with the results of cytogenetic analysis in all the normal and aneuploid cases except in one case of structural chromosomal abnormality. The hybridization efficiency of the 5 probes used for the detection of aneuploidies was 100%.<sup>30</sup>

In another study conducted by Ha-Jung et al.<sup>31</sup> using amniotic fluid interphase fluorescence in situ hybridization (FISH) for detection of aneuploidy in 130 prenatal cases using DNA probes specific for chromosome 13, 18, 21, X, Y. The overall detection rate for aneuploidies was 100% and in comparison to conventional cytogenetic results, the rates of both sensitivity and specificity were 100%.<sup>31</sup>

A Quantitative fluorescence-PCR (QF-PCR) approach is a more recent addition to aneuploidy diagnosis. The technique involves the relative quantification of microsatellite alleles to determine sequence copy number; amplification using fluorescence-labelled primers is followed by size separation and allele peak measurement on a semi-automated genetic analyser. Several assays have been developed and applied to prenatal diagnosis.<sup>32</sup>

## **CONCLUSION AND RECOMMENDATIONS**

FISH provides rapid, sensitive, specific and reliable, cost-effective method of prenatal diagnosis of numerical abnormalities of chromosomes 13, 18, 21, X and Y in conjunction with other methods currently used in prenatal diagnosis of

high risk pregnancies for aneuploidy.

## **REFERENCES**

1. Mueller RF, Young ID. Chromosomes. In: Mueller RF, Young ID, Emery AEH, Durbin A, editors. *Emery's elements of medical genetics*. 9<sup>th</sup> ed.: Churchill Livingstone; 1995. p. 23-45.
2. Edwards and Beard: FISH studies of pre-implantation embryos and PGD. *Human Reprod*: 1999 14 (1): 1-6.
3. Munne S, Weier HU. Simultaneous enumeration of chromosomes 13, 18, 21, X and Y in interphase cells for preimplantation genetic diagnosis of aneuploidy. *Cytogenet. Cell Genet*. 1996; 75 (4): 263-70.
4. Agarwal SS, Singh U, Singh PS, Singh SS, Das V, Sharma A, et al. Prevalence & spectrum of congenital malformations in a prospective study at a teaching hospital. *Indian J. Med. Res*. 1991; 94: 413-9.
5. Snijders RJ, Sherrod C, Gosden CM, Nicolaides KH. Fetal growth retardation: Associated malformations and chromosomal abnormalities. *Am. J. Obstet. Gynecol*. 1993; 168 (2): 547-55.
6. Lichter P, Cremer T, Tang CJ, Watkins PC, Manuelidis L, Ward DC. Rapid detection of human chromosome 21 aberrations by in situ hybridization. *Proc. Natl. Acad. Sci. U.S.A.* 1988; 85 (24): 9664-8.
7. Rooney DE, Czepulkowski BH. *Human cytogenetics: A practical approach: Malignancy and acquired abnormalities* vol. 2. 2<sup>nd</sup> ed.: Oxford University Press; 1992.

8. Seabright M. A rapid banding technique for human chromosomes. *Lancet* 1971 30; 2(7731): 971-2.
9. Eiben B, Trawicki W, Hammans W, Goebel R, Pruggmayer M, Epplen JT. Rapid prenatal diagnosis of aneuploidies in uncultured amniocytes by fluorescence in situ hybridization. Evaluation of >3,000 cases. *Fetal. Diagn. Ther.* 1999; 14 (4): 193-7.
10. Klinger K, Landes G, Shook D, Harvey R, Lopez L, Locke P, et al. Rapid detection of chromosome aneuploidies in uncultured amniocytes by using fluorescence in situ hybridization (FISH). *Am. J. Hum. Genet.* 1992; 51(1): 55-65.
11. Ward BE, Gersen SL, Carelli MP, McGuire NM, Dackowski WR, Weinstein M, et al. Rapid prenatal diagnosis of chromosomal aneuploidies by fluorescence in situ hybridization: Clinical experience with 4,500 specimens. *Am. J. Hum. Genet.* 1993; 52 (5): 854-65.
12. Cacheux V, Tachdjian G, Druart L, Oury JF, Serero S, Blot P, et al. Evaluation of X, Y, 18 and 13/21 alpha satellite DNA probes for interphase cytogenetic analysis of uncultured amniocytes by fluorescence in situ hybridization. *Prenat. Diagn.* 1994; 14 (2): 79-86.
13. Mercier S, Bresson JL. Prenatal diagnosis of chromosomal aneuploidies by fluorescence in situ hybridization on uncultured amniotic cells: Experience with 630 samples. *Ann. Genet.* 1995; 38 (3): 151-7.
14. Bryndorf T, Christensen B, Vad M, Parner J, Carelli MP, Ward BE, et al. Prenatal detection of chromosome aneuploidies in uncultured chorionic villus samples by FISH. *Am. J. Hum. Genet.* 1996; 59 (4): 918-26.
15. Bryndorf T, Christensen B, Vad M, Parner J, Brocks V, Philip J. Prenatal detection of chromosome aneuploidies by fluorescence in situ hybridization: Experience with 2000 uncultured amniotic fluid samples in a prospective preclinical trial. *Prenat. Diagn.* 1997; 17 (4): 333-41.
16. Cooper ML, Redman JB, Mensing DE, Cheung SW. Prenatal detection of chromosome aneuploidies in uncultured amniocytes by FISH: Advantages and limitations. *Am. J. Hum. Genet.* 1998; 63:A161.
17. Jalal SM, Law ME, Carlson RO, Dewald GW. Prenatal detection of aneuploidy by directly labeled multicolored probes and interphase fluorescence in situ hybridization. *Mayo Clin. Proc.* 1998; 73 (2): 132-7.
18. Verlinsky Y, Ginsberg N, Chmura M, White M, Strom C, Kuliev A. Detection of translocations involving the Y-chromosome in prospective prenatal screening of common chromosomal aneuploidies by FISH. *Prenat. Diagn.* 1998; 18 (4): 390-2.
19. Rotmensch S, Liberati M, Bronshtein M, Schoenfeld Dimaio M, Shalev J, Ben Rafael Z, et al. Prenatal sonographic findings in 187 fetuses with Down syndrome. *Prenat. Diagn.* 1997; 17(11): 1001-9.
20. Whitlow BJ, Chatzipapas IK, Lazanakis ML, Kadir RA, Economides DL. The value of sonography in early pregnancy for the detection of fetal abnormalities in an unselected population. *Br. J. Obstet. Gynaecol.*

- 
- 1999; 106 (9): 929-36.
21. Pandya PP, Brizot ML, Kuhn P, Snijders RJ, Nicolaides KH. First-trimester fetal nuchal translucency thickness and risk for trisomies. *Obstet. Gynecol.* 1994; 84 (3): 420-3.
  22. Van Zalen Sprock RM, van Vugt JM, van Geijn HP. First-trimester diagnosis of cystic hygroma--course and outcome. *Am. J. Obstet. Gynecol.* 1992; 167 (1): 94-8.
  23. Savoldelli G, Binkert F, Achermann J, Schmid W. Ultrasound screening for chromosomal anomalies in the first trimester of pregnancy. *Prenat. Diagn.* 1993; 13 (6): 513-8.
  24. Comas C, Martinez JM, Ojuel J, Casals E, Puerto B, Borrell A, et al. First-trimester nuchal edema as a marker of aneuploidy. *Ultrasound Obstet. Gynecol.* 1995; 5 (1): 26-9.
  25. Szabo J, Gellen J, Szemere G. First-trimester ultrasound screening for fetal aneuploidies in women over 35 and under 35 years of age. *Ultrasound Obstet. Gynecol.* 1995; 5 (3): 161-3.
  26. Brambati B, Cislighi C, Tului L, Alberti E, Amidani M, Colombo U, et al. First-trimester Down's syndrome screening using nuchal translucency: A prospective study in patients undergoing chorionic villus sampling. *Ultrasound Obstet. Gynecol.* 1995; 5 (1): 9-14.
  27. Bronshtein M, Bar Hava I, Blumenfeld I, Bejar J, Toder V, Blumenfeld Z. The difference between septated and non-septated nuchal cystic hygroma in the early second trimester. *Obstet. Gynecol.* 1993; 81 (5(Pt 1): 683-7.
  28. Nadel A, Bromley B, Benacerraf BR. Nuchal thickening or cystic hygromas in first- and early second-trimester fetuses: Prognosis and outcome. *Obstet. Gynecol.* 1993; 82 (1): 43-8.
  29. Tepperberg J, Pattenati MJ, Rao PN, Lese CM, Rita D, Wyandt H, et al. Prenatal diagnosis using interphase fluorescence in situ hybridization (FISH): 2-year multi-center retrospective study and review of the literature. *Prenat. Diagn.* 2001; 21 (4): 293-301.
  30. Jobanputra V, Roy KK, Kucheria K. Prenatal detection of aneuploidies using fluorescence in situ hybridization: A preliminary experience in an Indian set up. *J. Biosci.* 2002; 27 (2): 155-63.
  31. Lim HJ, Kim YJ, Yang JH, Kim EJ, Choi JS, Jung SH, et al. Amniotic fluid interphase fluorescence in situ hybridization (FISH) for detection of aneuploidy; Experiences in 130 prenatal cases. *J. Korean Med. Sci.* 2002; 17(5): 589-92.
  32. Mann K, Donaghue C, Fox SP, Docherty Z, Ogilvie CM. Strategies for the rapid prenatal diagnosis of chromosome aneuploidy. *Eur. J. Hum. Genet.* 2004; 12 (11): 907-15.
-