

## Original Article

### Role of Ultrasound Guided Biopsy of Thoracic Lesions

Elameen M<sup>1\*</sup>, Gabir A<sup>2</sup>, Mohammad M<sup>3</sup>, Ahmed A<sup>4</sup>, Ashkoub K<sup>5</sup>, Bashir A<sup>6</sup>

#### Abstract

**Objective:** This prospective study is to evaluate and enhance the role of ultrasound in biopsy guidance of thoracic lesions.

**Methods:** 55 patients were subjected for fine needle aspiration (FNA) and/or core needle biopsy (CNB) from peripheral chest lesions in Ribat University Hospital during the period from April 2011 and October 2012. Samples were analyzed and results were processed by the pathologist.

**Results:** 81 biopsies were successfully taken from 51 (92.7%) patients, while failed in 4 (7.3%). 41 (50.6%) of the biopsies were taken using FNA and 26 (32.1%) by CNB, while 14 (17.3%) of the samples were aspirations from loculated pleural effusions. The diagnostic yield was 96.2% for CNB, 92.7% for FNA and 95.7% when both of them were taken. The mean duration of the procedures was 20.6 minutes. Immediate complications occurred in three patients, mild hemoptysis in two and chest pain in one.

**Conclusion:** The results showed that US guided biopsies of intrathoracic lesions is safe, quick and the least expensive imaging guided biopsy. The procedure accuracy in obtaining sample is very high. Training chest physician on US will enable them to take active part in patient management and hence cut short waiting time for the procedure and the result, which will free the radiologist for more complex interventional procedures.

**Key words:** fine needle aspiration, core needle biopsies, Ribat University Hospital, Sudan.

**T**ransthoracic needle biopsy of malignant pulmonary lesions was first reported in 1886 when Leyden performed the first transthoracic needle lung biopsy to confirm pulmonary infections<sup>1</sup>.<sup>2</sup> During the first half of the twentieth century, surgical procedures such as open thoracotomy were commonly used to get these lung biopsies mainly to establish the microbiological diagnosis of extensive infectious lobar consolidation, which was easy to localize<sup>2</sup>.

There are several imaging modalities to obtain biopsy for intrathoracic lesions. The decision on the most appropriate imaging modality used for biopsy is made on reviewing the pre-biopsy CT scan of the chest. Fluoroscopy, CT and ultrasound may all be used for imaging guidance, and familiarity of the operator with all three modalities is helpful in choosing the appropriate technique<sup>3,4</sup>. The imaging technique chosen is dependent on the size of the lesion, its visibility on plain CXR, its relation to other structures, equipment's availability and operator preference<sup>3-6</sup>.

Fluoroscopy was the first technique used as guidance of percutaneous trans-thoracic needle biopsy (TNB) and drainage of fluid collections. It is quick and easy to perform and has no major disadvantages. Nevertheless, not all kinds of pulmonary lesions are amenable to this method. For example, extremely peripheral and very small lesions may not be detectable on lateral fluoroscopy; juxta-diaphragmatic and small apical lesions often are not

1.National Ribat University – Ribat university Hospital, medical department, respiratory unit interventional pulmonologist (Sudan)

2.Royal Care Hospital, department of Radiology (Sudan)

3.Ribat university Hospital, Radiology department.consultant radiologist

4.Ribat university Hospital, pathology department Pathologist

5.Ribat university Hospital, medical department, respiratory unit. Nurse technologists

6.Ribat university Hospital, medical department, respiratory unit.research fellow

\*Correspondent: Dr Mohammed Elbagir Ali Elameen

visible on lateral images because of overlying structures; with paracardiac, mediastinal, and apical lesions it is dangerous to perform needle insertion under fluoroscopic guidance alone, and a preliminary CT scan may be necessary to map adjacent cardiovascular structures. In such cases, CT-guided or sonographically guided biopsy may be useful<sup>7</sup>.

CT offers exquisite anatomical display of all the thoracic structures and allows percutaneous access to all spaces with equal ease. CT-guided biopsy is helpful in some cases, but lacks real-time monitoring of the needle position<sup>7</sup>.

Magnetic resonance (MR) is a promising modality for percutaneous interventions, but little clinical experience is gained so far in thoracic interventions<sup>2</sup>.

Sonography is an extremely flexible modality that can expeditiously guide many biopsy procedures in the thorax. Peripheral pulmonary nodules can be successfully biopsied with success rates exceeding 90% and complications rates of less than 5%. Orienting the probe parallel to the intercostal space facilitates biopsies of peripheral pulmonary nodules. Anterior mediastinal masses that extend to the parasternal region are often easily approachable provided the internal mammary vessels, costal cartilage, and deep great vessels are identified and avoided. Superior mediastinal masses can be sampled from a suprasternal or supraclavicular approach. Posterior mediastinal masses are more difficult to biopsy with ultrasound guidance because of the overlying paraspinal muscles<sup>8</sup>. Sonographic guidance has many advantages<sup>2,7</sup>, nevertheless it is not without problems<sup>7</sup>. Sonographically assisted fluoroscopically guided biopsy sometime is needed.

The two transthoracic biopsy techniques currently being used are fine-needle aspiration biopsy (FNAB) and core-needle biopsy (CNB). The sensitivity and specificity of both techniques for diagnosing lung cancer have been reported

to be high, with acceptable complication rates<sup>9</sup>.

FNAB was significantly better than CNB in lung carcinoma (95 versus 81%) but CNB was superior in non-carcinomatous tumors and in benign lesions. On-site cytology was 90% sensitive and 100% specific for predicting a positive FNAB. One patient required drainage for pneumothorax (0.6%)<sup>10</sup>.

#### **Material and methods:**

After we obtained an approval from our institutional review board and written informed consents from all patients, our study was carried out to assess the diagnostic value of ultrasound guided percutaneous biopsy from a peripheral pulmonary lesion. Between April 2011 and October 2012, 55 patients were subjected to fine needle aspiration (FNA) and /or core needle biopsy (CNB) under ultrasound guidance, at The National Ribat University Hospital Khartoum Sudan. The coagulation parameters platelet count and haemoglobin, viral screen for HBsAg, HCV, and HIV (after formal consent) were obtained from all patients. All patients have had chest X-Ray and non-enhanced CT chest.

The skin was prepared in sterile fashion and 1% lidocaine hydrochloride was administered with a 25 gauge hypodermic needle to anaesthetize the skin and subcutaneous tissue. Five persons were involved in the procedure (respiratory physician, radiologist, radiographer, laboratory consultant and two nurses). The patient's position was supine or prone. For FNA the needle size used was 18 gauges while for CNB it was 14 gauges.

#### **Results:**

Fifty five patients were included in the study; mean age was 52.8 years, and 36(65.5%) were males. The most common indication for the procedure according to their appearance in the computed tomographic images, was pleural effusion in 18 (32.7%) and lung mass in 13 (23.6%) (table 1).

Table1: indication of procedures

Procedure	Frequency	Percent (%)
Pleural effusion	18	32.7
Lung mass	13	23.6
Mediastinal masses	5	9.1
Nodularity	3	5.4
Fibrosis	2	3.6
Peripheral lung Nodule	1	1.8
Focal infiltrate	1	1.8
Other indications	6	10.9
Missed	6	10.7
Total	55	100.0

Cough was by far the most common symptom 41(74.6%), followed by chest pain 32 (58.2%), weight loss 25(45.5%) and shortness of breath 24 (43.6%). 16 (29%) patients had comorbidities, 7 were hypertensive and 5 were diabetic.

Thirteen (23.6%) patients had undergone previous procedures without reaching a diagnosis; these included 6 pleural aspirations, 3 bronchoscopic and one FNA, true cut US guided biopsies, CT guided FNA and pleuroscopy.

Eighty one samples were successfully taken from 51 (92.7%) patients. 41 (50.6%) of the samples were taken using fine needle aspiration, 26 (32.1%) by trucut biopsy (figure 1) and 14 (17.3%) of the samples were aspirations from loculated pleural effusions.

Both CNB and FNA samples were taken from 23 patients, the results of only 11 of them were available. Out of these 11 cases the concordance of the results was 7 (63.3%).

The range of the procedure duration was 5-45 minutes and the mean was 20.6 minutes. Immediate complications were hemoptysis in two and chest pain in one, and no delayed complications were reported. Most of the patients tolerated the

procedure fairly well. 32 (52.8%) of the patient were done as a day case.

Eighteen (35.3%) of the 51 cases were malignant, of those 9 (50%) were non-small cell carcinoma, 2 (11.1%) were small cell carcinoma, 1 (5.6%) were metastatic carcinomas and 6 (33.3%) were not categorized (table 2).

Table2: Type of malignancy

Type of malignancy	No. of patients	Percent (%)
Non-small cell carcinoma	9	50.0
Small cell carcinoma	2	11.1
Metastatic carcinoma	1	5.6
Not categorized	6	33.3
Total	18	100.0

### Discussion

Our results showed that US is the safest, quickest and the least expensive procedure for obtaining biopsy from suitable intrathoracic lesions. This is evident from our result as only 3 (5.9%) of our patients encountered complications (2 mild hemoptysis and one chest pain). Sheth safely performed ultrasound guided biopsy in 40% of his patients<sup>11</sup>. The safety of this kind of procedures was also a conclusion reached by other authors like Ikezoe et al and Arakawa et al who used ultrasound for guidance of intrathoracic biopsies in 124 and 40 patients, respectively, and both agreed on its usefulness and safety<sup>7, 12</sup>. The mean duration of our procedures was 20.6 minutes; this is shorter than the average duration stated by Sheth et al which was 31.4 min<sup>11</sup>. In our study we have seven patients with hypertension and five with diabetes on which US guided biopsy was successful and without complications which indicates that co-morbidity is not a limiting factor. Chih – Yen Tu et al 2004<sup>13</sup> undertook ultrasound guided aspiration in 1640 febrile patients in the medical intensive care unit with

Table 3: Diagnostic yields of Trucut and FNA

Procedure	Diagnostic samples	Inadequate samples	Total	Diagnostic yield
Trucut	25	1	26	96.2%
FNA	38	3	41	92.7%
Trucut + FNA	22	1	23	95.7%

hemothorax in two patients only with favorable outcome. US is cheaper than CT as it costs one fifth of the cost of CT in Ribat University Hospital. We were able to obtain successful biopsies in 76 of the 81 procedures (93.8% accuracy). This result is comparable to other similar studies. Yang et al in 1985, Yang et al in 1992 and Gulati et al in 1996 obtained 96%, 93% and 86.9% diagnostic yield respectively in their ultra sound guided biopsy studies<sup>14-16</sup>. 13 (23.6%) of our patients have had pervious diagnostic procedures that include bronchoscopy, pleural aspirate, pleuroscopy and US guided biopsy. This indicates that US guided biopsy can be a useful alternative or complimentary for other procedures and also can be repeated

as it is easy, feasible and cheap. US guided biopsy requires the involvement of a team to ensure patient comfort and safety and the technical success of the procedure<sup>17</sup>. The radiologist who routinely does this procedure should have sufficient expertise to perform the procedure safely and to deal with any complications that may arise<sup>17</sup>. In our study the team involves a radiologist and an interventional chest physician and a pathologist, they all shared doing the procedure. This is because the radiologist who was experienced in US guided abdominal biopsies need somebody who is experienced in dealing with respiratory complication that may result from the procedure.

All the complications and the after the

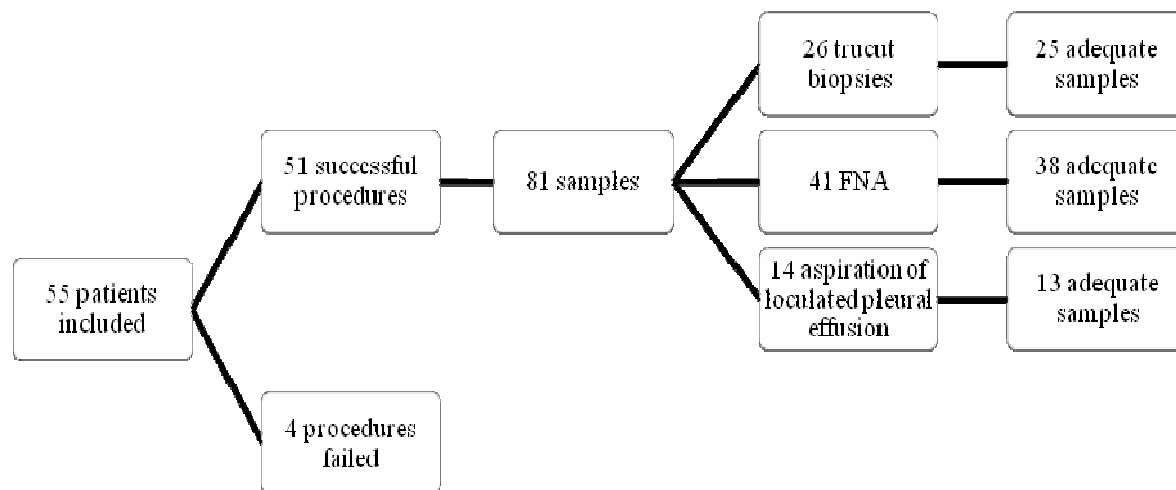


Figure1: samples taken using fine needle aspiration and by trucut biopsy

procedure observations were dealt with by the chest physician and the respiratory nurses. The equipment didn't involve on site microscope, this may explain the failed samples. The specimen for diagnosis by each procedure is comparable; in the CNB group 25 out of 26 specimens (96.2%) were containing adequate tissue for histology while the FNA specimen group 38 out of 41 specimens (92.7%)

were containing adequate material for cytology. Taking both FNA and CNB will not increase the diagnostic yield of the specimen (95.7%) (table3). However experience pathologists in cell cytology are not widely available. In the Cape Town, South Africa study the diagnostic yield of FNA, CNB and both combined were as follow 72%, 82% and 89% respectively<sup>10</sup>. One would expect that combined

procedures yield high results which is not the case in our study; this could be due to the small number in our combined group (23 cases).

US is now mastered by many clinicians (Urologists, Gynecologists and Emergency specialists) and it is now part and parcel of their training program. The usefulness of the percutaneous ultrasound guided lung biopsy in obtaining adequate sample from intra-thoracic lesions is now proved beyond doubt, this is why the related societies like the British Thoracic Society produces guideline for imaging guided procedures<sup>17</sup> and the European Respiratory Society included pleural US imaging mastering by respiratory physician in the Harmonized Education in Respiratory Medicine for European Specialists (HERMES) as a mandatory requirement<sup>18</sup>. Training Chest physician in US imaging will help them in obtaining biopsy from intra-thoracic lesions; this will shorten the patient and result waiting time and will free the radiologist to perform more interventional procedures. Most of the hospitals (central or rural) have US machines. Learning this skill by all clinician will improve patient's care; this is particularly so, as there are shortage in the number of the radiologist in the district and rural hospitals. Training chest physician US skill is highly recommended; furthermore it is strongly recommended to be included in all the training program of the respiratory physicians.

#### References:

1. Taber RE, Lupovitch A, Kantzler PJ. Fine-needle aspiration biopsy of lung tumors. *Ann Thorac Surg*. 1986 Dec;42(6 Suppl):S44-7.
2. Ghaye, B. and Dondelinger, R.F. Imaging Guided Thoracic Interventions. *Liege : European Respiratory Journal*, 2001;17(3):507-28
3. Klein JS and Zarka MA. Transthoracic needle biopsy: an overview. *s.l. : J Thoracic Imaging* 1997; 12: 232-49.
4. Moore EH. Technical aspects of needle aspiration biopsy: a personal. *s.l. : Radiology* 1998; 208: 303-18.
5. Murphy JM, Gleeson FV, Flower CDR. Percutaneous needle biopsy of the lung and its impact on patient management. *s.l. : World J Surg* 2001; 25: 373-8.
6. Gleeson FV. Lung and pleural biopsy. RAL Brewis, B Currin and D M Geddes. *Respiratory medicine*. London : WB Saunders, 2000.
7. Ikezoe J, Morimoto S, Arisawa Jet al. Percutaneous Biopsy of Thoracic Lesions: Value of Sonography for Needle Guidance. *Osaka, Japan : American Journal of Roentgenology* 1990;154:1181-5.
8. Middleron WD, Teefey SA and Dahiya N. Ultrasound-Guided Chest Biopsies. *Washington : Ultrasound Q*, 2006;22(4):241-52.
9. You X, Gomes MM, Tsao M Set al. Fine-Needle Aspiration Biopsy Versus Core-Needle Biopsy in Diagnosing Lung Cancer: A Systematic Review. *s.l. : Current Oncology*, 2012;19(1):e16-27.
10. Diacon AH, Theron J and Schubert P. Ultrasound-Assisted Transthoracic Biopsy: Fine-Needle Aspiration or Cutting-Needle. *Cape Town : European Respiratory Journal*, 2007;29:357-362.
11. Sheth S, Hamper UM, Stanley DB et al. US Guidance for Thoracic Biopsy: A Valuable Alternative to CT. *s.l. : Radiology* 1999; 210: 721-6.
12. Arakawa A, Matsukawa T, Kira M et al. Value of ultrasound-guided core-needle biopsy for peripheral intrathoracic and mediastinal lesions. *Kumamoto City, Japan : Computerized Medical Imaging and Graphics* 1997;21(1):23-8.
13. Tu CY, Hsu WH, Hsia TC et al. Pleural Effusions in Febrile Medical ICU Patients. *s.l. : Chest* 2004; 126(4): 1274-80.
14. Yang PC, Luh KT, Sheu JC et al. Peripheral pulmonary lesions: Ultrasonography and ultrasonically guided aspiration biopsy. *s.l. : Radiology* 1985; 155: 451-6.
15. Yang PC, Chang DB, Lee YC et al. Mediastinal malignancy: ultrasound guided biopsy through the supraclavicular approach. *s.l. : Thorax* 1992; 47: 377-80.

16. Gulati M, Kumar S, Suman Ket al. Ultrasound guided aspiration biopsy of peripheral pulmonary lesions. s.l. : Indian J Chest Dis Allied Sci 1996; 38(1): 19-23.
17. Manhire A, Charig M, Clelland Cet al.Guidelines for Radiologically Guided Lung Biopsy*Thorax* 2003;58:920-936.
18. Loddenkemper R, Séverin T, Eiselé JLet al. HERMES: a European Core Syllabus in Respiratory Medicine. *Breathe* 2006;3:59–70.