

## Case Article

### Intra-abdominal lymphangioma with ascariasis as diagnostic predicament

Ibrahim Salih Elkheir, and MAM Ibnouf.

#### Background:

Lymphangiomas are rare tumours. About 90% of lymphangiomas manifest in children at the age of three years<sup>1</sup>. The sex ratio is roughly equal in childhood<sup>2</sup>. In young patients lymphangiomas are preferentially located in head, neck and axilla, but they also occur sporadically in various parenchymal organs e.g. spleen, liver and bones. When it is diffuse as multifocal disease [lymphangiomatosis] during adulthood, it develops as superficial cutaneous lymphangioma or as intra-abdominal lymphangiomas. The male to female ratio for intra-abdominal lymphangiomas<sup>3</sup> is 3:1. Here we present a case of intra-abdominal lymphangioma in a 14- year old boy who presented as a diagnostic dilemma.

**Key words:** Intra-abdominal lymphangioma

**A** 14-years old male presented with a recurrent episodes of sub-acute intestinal obstruction. Clinical examination revealed vague abdominal mass in the left side of the abdomen. Exploration laparotomy showed an extensive mass in the mesentery of the small bowel, causing narrowing of the lumen Fig 1 and 2.

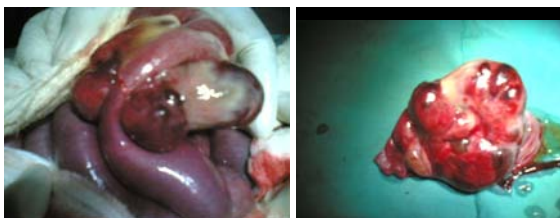
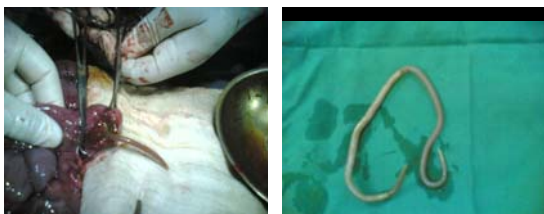
Fig 1 and 2 showing the tumour before and after excision

The mass infiltrated the bowel. Extensive resection of the mass and part of engulfed ileum was done. After resection was complete and immediately before the anastomosis we saw a worm of ascaris coming from distal part of ileal lumen as shown in fig 3 and 4.



Figures 3 and 4 showing ascaris worm emerging from the small bowel.

Post-operative was uneventful without any lymphatic discharge. Histopathology confirmed lymphangioma showing multicystic spaces lined by flat low lying epithelium with surrounding tissue of scattered lymphoid cells as seen in fig 6. Two years follow up, till the patient lastly seen abdomen shown no recurrence.

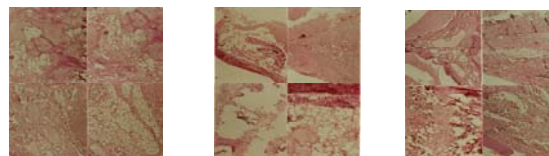


Fig 6,7 and 8 showing the histopathology of lymphangioma.

#### Discussion

Intra-abdominal cystic lymphangioma of mesentery is a rare congenital lesion with relatively low growth potential. It is typically found in young adult and presents with chronic features in younger children. Malformations are aggressive<sup>2</sup> lymphangiomas prone to recurrence and infiltrating growth. Our patient presented with abdominal mass infiltrating the bowel. However, these lesions usually present as painless abdominal distention or with complications like volvulus, infections, intracyclical haemorrhage and intestinal obstruction. It is difficult to be diagnosed without high index of suspicious. In our case

ultrasound was not done, however, most of the cases can be diagnosed using abdomen ultrasound<sup>3</sup>. In some cases confirmation of the diagnoses may require additional investigations like CT scan of the abdomen or magnetic resonance imaging<sup>4,5</sup>. Nevertheless, like in our case, the final diagnoses should be established by histopathological examination<sup>4</sup>. Cystic lymphangioma can be enucleated completely without compromising the bowel vascularity. However, in cases of infiltrative lymphangioma, like our case; resection of involved part of the mesentery along with the bowel is recommended. A common post-operative complication is persistence lymphatic leak with or without infection. Other modalities of treatment for unresectable intra abdominal lymphangimas include sclerotherapy with doxycycline or alcohol intra-lesional injection<sup>6-9</sup>. We recommend that abdominal ultrasound supplemented by CT scan with the high index of suspicion for lymphangioma. However, histo-pathological examination is the cornerstone to confirm the diagnosis. The association of intra-abdominal lymphangioma and asciasis in our case may be coincidental finding. Yet, the association of both conditions is a real diagnostic

predicament to the surgeon that merits reporting.

### References

- 1- Bill AH, Sumner DS. A unified concept of lymphangioma and cystic hygroma-Surg Gynecol Obstet. 1965; 120:79-80.
- 2- Kindblom IG, Angervall I. Tumour of lymph vessels. Contemp Issues Surg Pathol. 1991; 18:136-137.
- 3- Takiff H, Calabria R. Mesenteric cyst and intra-abdominal cystic lymphangiomas. Arch Surg 1985, 120:1266-69.
- 4- De Perrot M, Rosan O, Morel P et al. Abdominal lymphangioma adults and children. Br J Surg 1988; 85:395-7.
- 5- Merrot T, Chaumorite K, Simeoni-Alias J. et al. Abdominal cystic lymphangioma in children: clinical, diagnostic and therapeutic aspects: A props of 21 cases. Ann Chir 1999; 53:494-9.
- 6- Kably A, Mumen M, Raissouni N. et al. Cystic lymphangioma of the mesentery and the epiploon. about two cases. Gynecol Obstet Fertil 2003; 31: 136-8.
- 7- Huis M, Baliji M, Lez C et al. Mesenteric cyst. Acta Med Croatica 2002; 56: 119-24.
- 8- Mabrut JY, Grandjean JP, Henry I et al. mesenteric and meso-colic cystic lymphangiomas diagnostic and therapeutic management. Ann Chir 2002; 127: 343-9.
- 9- Stein M, Hus PK, Schneider PD et al. Alcohol ablation of mesenteric lymphangioma. J Internat. Radiol 2000; 11: 247-50.