

## Case Report

### Spontaneous Achilles tendon rupture in alkaptonuria

Osman Bakry Mohammed<sup>1</sup>, Saadeldin A. Idris<sup>2</sup>, and Mohammed H.F. Shalayer<sup>3\*</sup>

#### Abstract:

Spontaneous Achilles tendon ruptures are uncommon. We present a 46-year-old man with spontaneous Achilles tendon rupture due to ochronosis. To our knowledge, this has not been previously reported in Sudan literature. The tendon of the reported patient healed well after debridement and primary repairs.

**Keywords:** Alkaptonuria, Ochronosis, Homogentisic acid (HGA).

**T**raumatic tendon ruptures are common; however, spontaneous ruptures are not. Ochronosis is the musculoskeletal manifestation of alkaptonuria (AKU), a rare autosomal recessive disorder with an estimated prevalence of below 1:250 000.<sup>1</sup> AKU is a rare disease in which the body does not have enough of an enzyme called homogentisic acid oxidase<sup>2-4</sup>. AKU occupies a unique place in the history of human genetics because it was the first disease to be interpreted as a Mendelian recessive trait by Archibald Garrod in 1902<sup>5</sup>. The defect lies in the catabolic pathway of tyrosine (figure 1), which contains a parahydroxylated ring structure.

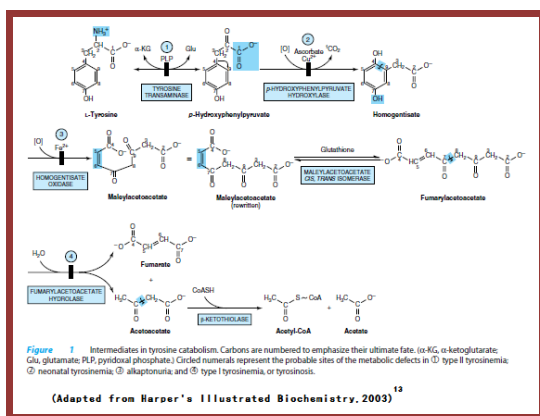
In a poorly understood complex reaction, the enzyme phenylpyruvic acid oxidase is thought simultaneously to move the pyruvic acid side chain, to decarboxylate it, and to add an additional hydroxyl group to the ring. The product, homogentisic acid, is actually *ortho-meta*-dihydroxyphenylacetic acid.

#### Case report:

A 46-year-old man had a spontaneous rupture of his left tendo Achilles when he felt a sudden pain in his ankle which gives way while attempting to stand from a crouching position at home. He continued to complain of a persistent dull aching pain and an alteration in his gait. Three years earlier he had had a spontaneous rupture of the right tendo Achilles while running downstairs. He was healthy, with no previous symptoms related to other parts of musculoskeletal system. There was swelling in the posterior aspect of the lower leg and around the ankle associated with tenderness.

There was a palpable defect of tendo Achilles close to its insertion. He had weakness of plantar flexion and restricted active and passive dorsiflexion. He was unable to stand on his toes on the affected side.

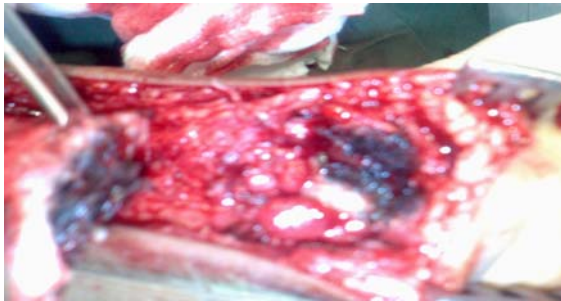Patient is known hypertensive for seven years and he is on regular antihypertensive drug (Amlodipine 5 mg/day). Investigations performed showed haemoglobin of 15 gm/dl, clear urine with normal colour that does not change on standing.



1. University of technical and medical sciences, Dept. of Orthopaedics, Khartoum, Sudan.
2. Western Kordufan University, Faculty of medicine, Depart. of Surgery, Elnihood, Sudan.
3. National College for Medical and Technical studies.

Operative repair of tendo-Achilles performed on the 3<sup>rd</sup> post event day.

At operation it was found that the entire tendon was stained dull yellow and the ruptured surface stained deep black (figure 2).



**Figure 2:** Dull yellow staining with deep black surface of the ruptured Achilles tendon.

The stump of the tendon appeared to be degenerated with multiple pigmented black nodules. The pigmentation was restricted to a few millimetres from the ruptured surface and the fibres of the tendon were fibrillated and degenerated in the area close to the rupture site. The restriction of the pigment to a few millimetres on either side of the ruptured surface indicated that the tendon had been weakened in this region. Ochronosis had been diagnosed because of the dark pigmentation at the ruptured ends of the tendons. Resection of the pigmented margins gave two healthy ends and the tendon was repaired using vicryl. The ankle was immobilised in 20° equinus for three weeks and later the patient was mobilised partially weight-bearing in a neutral position for three further weeks.

There was good healing and the patient remained asymptomatic. Vitamin C was prescribed for the patient as an antioxidant.

Histopathological examination of the resected portion of the tendon showed deposition of pigment within and outside the cells in the tissues. From the family history, his uncle was found to have the same metabolic disease affecting his cervical, thoracic, and lumbar spine.

#### Discussion:

A deficiency of the hepatic enzyme homogentisate 1,2-dioxygenase (HGO) forces the accumulation of homogentisic acid, which

is rapidly cleared in the kidney and excreted<sup>6</sup>. Production of large quantities of HGA daily in the urine, turns it dark on standing<sup>7,8</sup>. In urine, as in tissues, HGA oxidizes to benzoquinones, which in turn form melanin-like polymers. Accumulation of HGA and its metabolites in tissues causes ochronosis, with darkening of cartilaginous tissues and bone, arthritis and joint destruction, and deterioration of cardiac valves<sup>7-9</sup>. There is no effective therapy for this disorder, although nitisinone inhibits the enzyme that produces HGA<sup>10</sup>. Therapy could also be achieved with the use of antioxidants such as ascorbic acid since reducing HGA oxidation could increase urinary excretion of HGA<sup>11</sup>. Furthermore, ascorbic acid has been shown to inhibit HGA polyphenol oxidase, with a consequent decrease in benzoquinone acetic acid (BQA) synthesis, a product of the oxidation of homogentisic acid (HGA) that causes tissue injury<sup>12</sup>.

Tendons are sites of ochronotic pigment deposition because of their high collagen content<sup>14</sup>. Several cases of tendon and ligament ruptures in AKU have been reported<sup>1,8,10</sup>.

To our knowledge, this has not been previously reported in Sudan literature.

#### Conclusion:

The trivial nature of the injury leading to the ruptures and the incidence of bilateral rupture of tendo Achilles in one patient indicates that spontaneous rupture of tendons is an important clinical feature of ochronosis.

#### References:

1. Mannoni A, Selvi E, Lorenzini S, *et al.*. Alkaptonuria, ochronosis, and ochronotic arthropathy. *Semin Arthritis Rheum* 2004; 33: 239–48.
2. Zhao BH, Chen BC, Shao DC *et al.* Osteoarthritis? Ochronotic arthritis! : A case study and review of the literature. *Knee Surg Sports Traumatol Arthrosc* 2009;17(7):778-81..
3. Peker E, Yonden Z, and Sogut S. From darkening urine to early diagnosis of alkaptonuria. *Indian J Dermatol Venereol Leprol.* 2008; 74(6):700.

4. Araki K, Sudo A, and Hasegawa M, Uchida A . Devastating Ochronotic Arthropathy With Successful Bilateral Hip and Knee Arthroplasties. *J Clin Rheumatol* 2009 ;15(3):138-40.
5. Fernández-Cañón JM, Granadino B, Beltrán-Valero de Bernabé D et al. The molecular basis of alkaptonuria. *Nat Genet.* 1996; 14(1):19-24.
6. Garrod AE. The incidence of alkaptonuria: a study in chemical individuality. 1902 [classical article]. *Yale J Biol Med.* 2002;75(4):221-31.
7. La Du BN, Zannoni VG, Laster L et al. The nature of the defect in tyrosine metabolism in alcaptonuria. *J Biol Chem* 1958; 230: 251–60.
8. O'Brien WM, La Du BN, Bunim JJ. Biochemical, pathologic and clinical aspects of alcaptonuria, ochronosis and ochronotic arthropathy: review of world literature (1584-1962). *Am J Med* 1963;34: 813-838.
9. La Du BN. Alkaptonuria. In: Scriver CR, Beaudet AL, Sly WS, Valle D, eds. *The metabolic & molecular bases of inherited disease.* 8<sup>th</sup> ed., Vol. 2. New York: McGraw-Hill, 2001:2109-23.
10. Phornphutkul C, Introne WJ, Perry MB, et al. Natural history of alkaptonuria. *N Engl J Med* 2002; 347: 2111-2121.
11. Zannoni VG, Lomtevas N, Goldfinger S. Oxidation of homogentisic acid to ochronotic pigment in connective tissue. *Biochim Biophys Acta* 1969;177: 94-105
12. Lorenzini S., Mannoni A., Selvi E et al. Alkaptonuria. *N Engl J Med.* 2003; 348(14):1408.
13. Murray R K, Granner D K, Mayes P A et al (2003). *Harper's Illustrated Biochemistry.* 26<sup>th</sup> edition, Lange medical book. Section III (chapter 30). Pp 254.
14. Jozsa L, Kannus P. *Human tendons – anatomy, physiology and pathology* . Champaign, Illinois, USA: Human Kinetics Publishers, 1997.