

## Case Report

### Gastrointestinal Basidiobolomycosis Mimicking Colon Cancer In a Sudanese Patient

Sami.M.Taha, AbdAlMagid Masaad, Lamyaa A.ME.LHassan,  
Ahmed M. EL Hassan, Gamal Mustafa, DiaaEldeenYaseen

Basidiobolomycosis is a rare disease caused by the fungus *Basidiobolus ranarum*. The incidence Rate of Gastrointestinal Basidiobolomycosis is approximately 1 in 45,333,334 or 0.00% in every 5 people in USA), member of the class Zygomycetes found worldwide<sup>(1)</sup>. Basidiobolomycosis is usually a subcutaneous infection but rarely gastrointestinal<sup>1</sup>. This fungus is found mainly in the soil and on decaying vegetations<sup>2</sup>. It has been isolated from the banks of tropical rivers in West Africa, and has also been found in association with some insects<sup>2</sup>. The fungus is known to be present in the gastrointestinal tracts of reptiles, amphibians, and some bat species<sup>3</sup>. Definitive diagnosis requires culture and serological testing may be helpful. The fungal morphology and the Splendore-Hoeppli phenomenon are characteristic histological features. Basidiobolomycosis is treated with surgical resection and itraconazole 200mg BD for three months or Amphotericin B 5mg /kg iv/24 hrs<sup>4</sup>.

Keywords: Zygomycetes, vegetations, subcutaneous infection.

#### Case Report

A 24 years man from Khartoum, presented with: fever for one month, abdominal pain and right iliac fossa mass for two weeks. His condition started one month prior to his presentation with nocturnal low grade fever. The latter was not associated with sweating and was relieved by taking paracetamol. Two weeks later he developed localized right iliac fossa pain which was continuous, accentuated from time to time, and aggravated by movement. At the same time he started to feel a mass in the region of Right iliac fossa. There was no anorexia, vomiting, change in bowel habits, abdominal distension or loss of weight. Systemic review was unremarkable. He was a known case of duodenal ulcer since 1997 on ranitidine. On examination he was well, not pale or jaundiced. The vital signs were normal. The lymph nodes were not palpable. There was intra abdominal palpable mass in the Right iliac fossa which measured five cm in diameter; the mass was firm, fixed and was not tender. There was no organomegaly and no ascites. Digital rectal examination was normal.

The complete blood count showed eosinophilia with hemoglobin of 12.2 g/dl and total white blood cell count of 6000/cm<sup>3</sup>. The Erythrocyte Sedimentation rate was 20mm/hour.

Stool and Urine analysis was normal. Blood urea 19 mg /dl S.creatinine 0.8 mg/dl .S K+ 3.6 mmol/l Serum Na+ 140 mmol/l. Random Blood sugar: 130 mg/dl. CXR: Normal.

Colonoscopy: the whole ascending colon was full of sessile polyps with a tumour seen in the hepatic flexure (Figure 1).

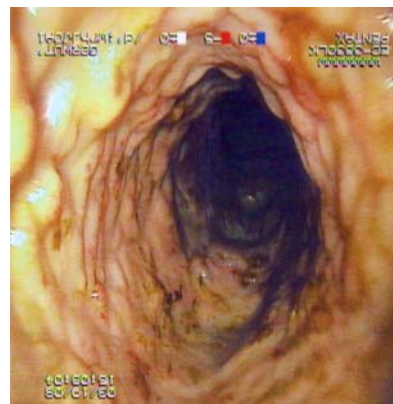

Figure1: sessile polyps.

Histopathological result of biopsy taken from these polyps was suspicious of schistosomiasis and eosinophilic colitis (another biopsy was advised. Figure2).

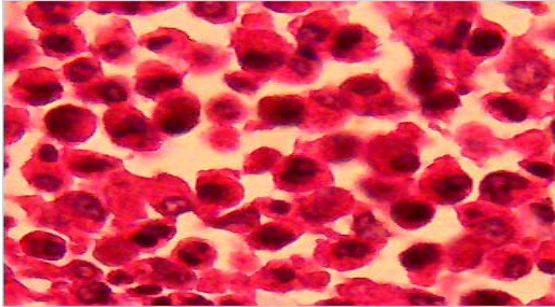


Figure2: Intense infiltration by eosinophils.

The patient was planned for surgery. Intraoperative findings showed tumors in the Rt hepatic flexure, transverse colon, caecum and terminal ileum. The right (Rt) colon showed narrowed lumen with submucosal swelling. Macroscopic features were similar to Crohn's disease (figure3&4).

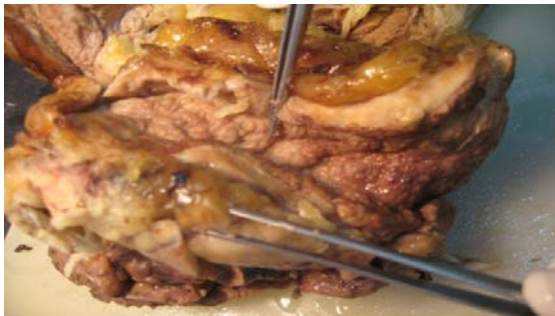

Figure 3: Colon specimen showing features similar to Crohn's disease mainly Cobblestone appearance and creeping fat.

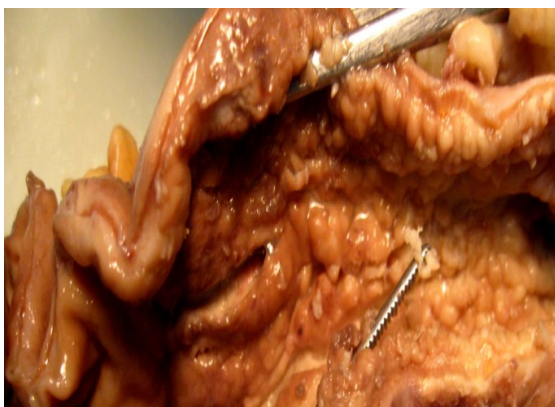

Figure4: Colonic mucosa showing cobblestone appearance.

Extended Rt hemicolectomy was done with end to end ilio-transverse anastomosis. The specimen was sent for histopathology. Recovery and postoperative period was uneventful. The result of histopathology was Basidiobolomycosis (figure5,6&7).

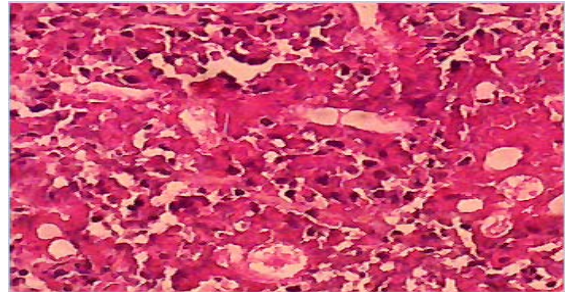


Figure5: Large septate hyphae with thin walls are characteristic of this zygomycete.

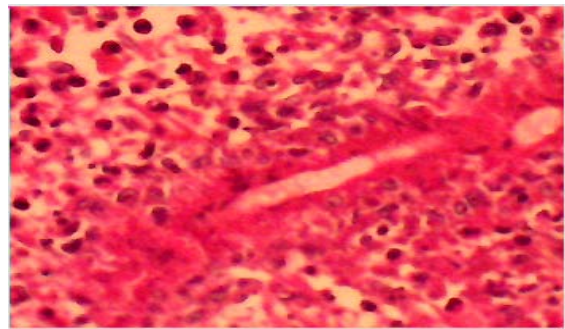


Figure6: Hypha surrounded by Splendore-Hoeppli phenomenon consisting of deeply eosinophilic granular material. This is due to Immune complexes.

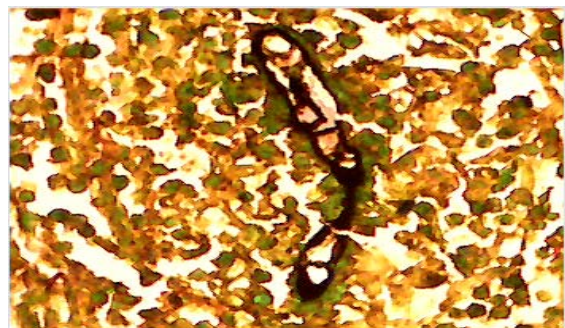


Figure7: Large septate hyphae.(Silver stain)

#### Discussion:-

Basidiobolomycosis is a fungal disease known for its dermatologic manifestations in tropical regions of Africa, South America and Asia. The visceral form of infection is rare<sup>5</sup>.

Up to the year 2000 fewer than 10 cases were reported in the literature, mainly from Brazil and the USA<sup>6</sup>. The small number of reported cases of abdominal basidiobolomycosis, was probably related to the limited awareness of this disease, and may not reflect its true incidence worldwide. Its diagnosis is usually delayed or overlooked if attention is not focused on the possibility of a fungal infection. In this case it was difficult to reach the diagnosis preoperatively. Apart from painless Right iliac fossa mass with eosinophilia there was no clinical finding that could make us think of basidiobolomycosis; although the diagnosis can be reached by a careful history that includes occupation, family history, recent travel and current medications<sup>7</sup>. Medical history should include previous hospital admissions; surgical procedures, family history of ulcers, colitis, or cancer. Basidiobolomycosis includes the four symptoms listed below; these are: abdominal pain, abdominal mass, painless nodule, and lump underneath the skin<sup>7</sup>. Patients are usually immunocompetent, despite the fact that there are many risk factors in the literature eg ketoacidosis, neutropenia, iron chelating drugs, long use of variconazole or patient with hematological malignancies<sup>8</sup>. In this case there was no obvious risk factor. Basidiobolomycosis is shown by culture, serologic immunodiffusion test, and histology with necrotizing granulomas and fungal hyphae surrounded by characteristic but non pathognomonic eosinophilic Splendore-Hoeppli phenomenon. Hyphae may be septated or non-septated<sup>4</sup>. All reported cases were due to *B. ranarum*. The mechanism of visceral infection may be by fungal ingestion and gastrointestinal mucosal penetration<sup>9</sup>. This case is very interesting; firstly because it is extremely rare, secondly the macroscopic appearance was indistinguishable from Crohn's disease which was also reported by

others and thirdly because the initial biopsy which was from the mucosa showed no fungal hyphae but many eosinophils, consequently the diagnosis of eosinophilic colitis or parasitic infection was suggested. Although enteric fungal infection is not uncommon, yet several cases of such an infection could be overlooked if never put in yard of diagnosis.

## References

1. Toro C, Del Palacio A, Alvarez C, et al. Cutaneous zygomycosis caused by *Rhizopus arrhizus* in a surgical wound. *Rev Iberoam Micol* 1998;15 (2): 94–6.
2. Ettinger, Stephen J.;Feldman, Edward C. (1995). *Textbook of Veterinary Internal Medicine*, 4th ed., W.B. Saunders Company. ISBN 0-7216-6795-3.
3. Spellberg B, Edwards J, Ibrahim A. Novel perspectives on mucormycosis: pathophysiology, presentation, and management. *Clin. Microbiol. Rev.* 2005;18 (3): 556–69.
4. Van den berk GEL, Noorduyt LA, van Ketel RJ, et al. (2006). A fatal pseudo-tumour: disseminated basidiobolomycosis. *BMC Infect Dis* 6: 140.
5. Mathew RM, Kumaravel S, Kuruvilla S, et al. "Successful treatment of extensive basidiobolomycosis with oral itraconazole in a child". *Int J Dermatol* 2005;44 (7): 572–75.
6. Wolf, Alice (2005). "Opportunistic fungal infections", in August, John R. (ed.): *Consultations in Feline Internal Medicine* Vol. 5. Elsevier Saunders. ISBN 0-7216-0423-4.
7. Yusuf NW, Assaf HM, Rotowa N. Invasive gastrointestinal *Basidiobolus ranarum* infection in an immunocompetent child (brief report). *Ped Infect Dis J* 2003;22 (3): 281–82.
8. Zavasky DM, Samowitz W, Loftus T et al. Gastrointestinal zygomycotic infection caused by *Basidiobolus ranarum*: case report and review. *Clin Infect Dis* 1999;28 (6): 1244–8.
9. Nazir Z, Hasan R, Pervaiz S et al. Invasive retroperitoneal infection due to *Basidiobolus ranarum* with response to potassium iodide—case report and review of the literature. *Ann Trop Paediatr* 1997; 17(2):161-4.