

Radiological changes and progress in patient with pulmonary Tuberculosis following treatment with daily versus intermittent short course regimens

Mutasim S. Mohammed Salih¹, Idris B Eltayeb², Abdullahi M Zaki³, Buder Eldein H Ahmed², Alla Eldin H.Ahmed² and Hassan M. Mohi Eldein²

Abstract

This is a prospective comparative randomized study carried out at Kosti teaching hospital 2006-2008.

Objectives: to determine the radiological findings and to evaluate the radiological progress in patient with pulmonary Tuberculosis treated with daily versus intermittent short course regimens.

Methodology: A total of 275 smear positive new cases of Tuberculosis were enrolled and randomized in to two groups, intermittent group (A) and daily regimen group (B). X-Ray film was done initially and at the end of treatment for each patient.

Results: It was found that 31% of the X-Ray films were normal. Concerning the progress of minimal lesion significantly high percentage improved to normal X-Ray 58% in group A and 53 % in group B, 42 % in group A and 40 % in group B stayed as minimal lesion. The results of far advanced lesion revealed that intermittent regimen improved 16.6% of the films to normal and minimal lesion, 8.3 % to moderate lesion, 33.3 % moderately advanced lesion and 25 % remained unchanged, while in the daily regimen, 21 % improved to normal and minimal lesion, 5.2 % to moderate lesion, 27 % to moderately advanced lesion and 27.6 %. Statistical analysis revealed a significant difference between the two groups.

Conclusion: Conversion of minimal lesions to normal X-Ray was significantly higher in the intermittent group and the conversion of far advanced lesions to normal was significantly higher in the daily regimen.

Keywords: chemotherapy, lymphadenopathy, Rifampicin, Isoniazid, Pyrazinamide

Randomized clinical trial addressing the intermittent chemotherapy has not been conducted yet in Sudan, according to¹, the intermittent regimens may be more suitable in Sudan, therefore, a study to assess the efficacy of the intermittent chemotherapy of Tuberculosis (T.B) is justifiable and highly needed, putting in mind the increasing incidence rate of T.B in the Sudan generally and specially in the White Nile area. Clinical factors that are associated with poor radiological outcome has not been adequately addressed in medical literature and

in Saudi Arabia near complete or complete clearance of chest X-Ray was detected in 43.5% of patients². WHO has been propagating the use of intermittent supervised treatment for all cases including children³. In the United States, chest radiography is often considered a reliable and an important investigation for diagnosis of Tuberculosis⁴ and lymphadenopathy may persist for several years after treatment^{5, 6}. In Abuja, Nigeria Chest X-rays were graded by two readers⁷. In USA chest radiographs help in the diagnosis of pulmonary TB, but may be normal and the rate of normal Chest X-rays among persons with culture-confirmed pulmonary TB was high⁸. This study aimed to determine the radiological findings and to evaluate the efficacy of intermittent TB therapy compared to the currently adopted daily short course

1. Department of Pharmacology Radiology and Medicine – Faculty of Medicine- University of Al Imam Al Mahdi.
2. Department of Pharmacology and Medicine – Faculty of Pharmacy and Medicine- University of Khartoum.
3. Department of chest – Faculty of Medicine- Omderman Islamic University

regimen in regards to: the radiological progress.

Material and Methods: New smear positive pulmonary Tuberculosis patients who attended the department of chest at Kosti Teaching Hospital during March 2006 to March 2008 were enrolled in this study.

The inclusion criteria for the sampled patients were as follows:

- Adult > 15 years old
- Three sample sputum smear positive pulmonary case.
- No associated debilitating diseases or advanced disseminated cases.

Because no reliable data addressing the incidence or prevalence of tuberculosis in the study area, and depending on the proper records available in TB programme in the White Nile State, sample size was calculated as follows:

- The average of smear positive tuberculous patient attending chest department at Kosti teaching hospital for the last 5 years (2001—2005) was calculated (550 patient) .
- A total of 275 patients were introduced to the study ..

The patients were randomized using lottery into two groups :

Group **(A)** the intermittent regimen group these patients were treated using Ethambutol(20mg/kg) , Rifampicin(10mg/kg)\ Isoniazid(6mg/kg) and Pyrazinamide (25mg/kg) for two months as an initial phase then were given the minimum intermittent dosage of Rifampicin 900mg(30mg/kg)\ Isoniazid 450mg(15mg/kg) twice weekly (about 12 tablets\ week)for four additional months . 128 patients were enrolled.

Group **(B)** the short course daily regimen group these patients were treated using Streptomycin (15mg) , Rifampicin (10mg/kg) \ Isoniazid (6mg/kg) and Pyrazinamide (25mg/kg) for two months as an initial phase then rifampicin (10mg/kg)\ Isoniazid (6mg/kg) once daily (about 21 tablets\ week) for four additional months , 147 patients were enrolled.

Directly Observed Therapy (DOT) and closed supervision was applied.

The patients were supplied with food supplied for the patient and his \ her family during the course of treatment. 71 patients (55.5%) were cured the treatment in group A (intermittent regimen group) and 67 patients (45.6%) in group B (daily regimen group).

Chest X-ray was done in a posteroanterior position for each patient initially before starting the treatment and another one by the end of the treatment (after six months).

X-Ray films were processed as follows:

- X-ray films were reported by an expert radiologist then the initial and the final X-ray films were compared for the patients who completed the course of therapy using the following scores according to TB :

- **Minimal:** For single lesion left, right, upper or lower.

- **moderate:** for two lesions in two lungs.

- **Moderately advanced lesions:** for more than two lesions in different zones (bilateral lesions).

- **Far advanced lesion:** involve two lungs in two different zones.

A written consent from the local health authority was already taken and each patient was informed and consented.

The raw data were introduced into SPSS program for the performance the descriptive and comparative analysis. The data comparison was carried out by Pearson Chi square and pair independent sample student T-test. The level of significance ($P < 0.05$).

The results:

Table (1) Initial radiological findings among the study group of tuberculous patients N = 275 patients

Lesion	No	%
Consolidation	152	55
Normal chest X-ray	85	31
Cavity	11	4
Pleural effusion	10	3.6
Nodular	12	4.4
Linear fibrosis	2	0.8
Adenopathy	1	0.4
Calcification	2	0.8
Bronchiectasis	0	0

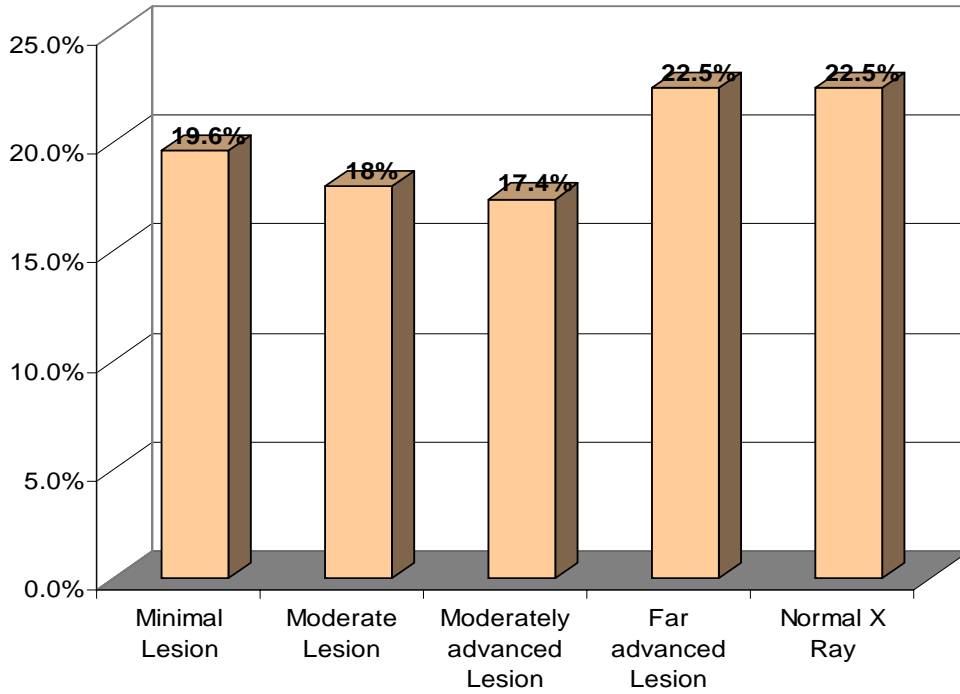


Figure (1) Severity of TB lesions in the initial X-Ray film among cured patients (group A and B)
N – 138 patients

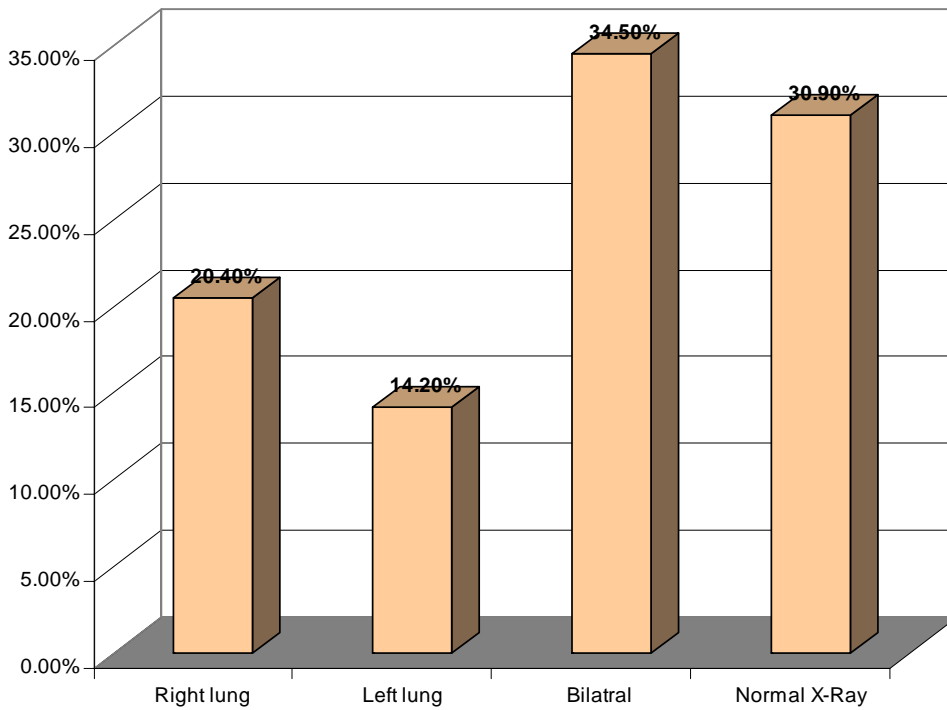


Figure (2) Distribution of TB lesions in the two lungs (left and right) N = 275 patients

Table 2: Distribution of TB lesions at different lungs zones among the study population (group A, B) N=98 films

	Right lung		Left lung	
	Number	%	Number	%
Upper zone	10	5.9%	8	20.5%
Middle zone	6	3.54%	5	12.82%
Lower zone	17	10.03%	12	30.76%
Upper and middle zone	9	5.31%	6	15.38%
Upper and lower zone	0	0	0	0
Middle and lower zone	7	4.13%	4	10.25%
Upper middle and lower	10	5.9%	3	7.69%
Total	59	100%	39	100%

Table (3) Bilateral distribution of TB lesions at different lung zones among the study population (group A,B). N = 95

Zones	No of films)	percentage
Upper \ upper zones	1	1%
Lower\lower zones	21	22.1%
Upper \upper and middle\middle zones	6	6.3%
Middle\middle and lower\lower zones	14	14.7%
Middle\middle zones	14	14.7%
Upper \upper , middle\middle and lower\lower zones	5	5.3%
Other s	27	28.4%
Total	95	100 %

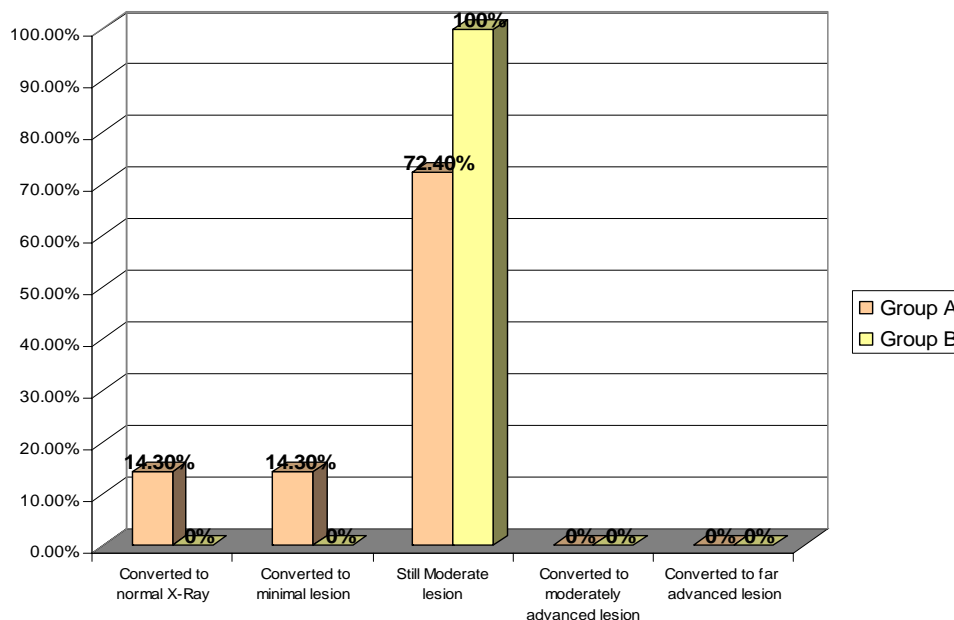


Figure (3) Radiological progress of moderate TB lesion in the initial and final X-Ray films N = 25 films.

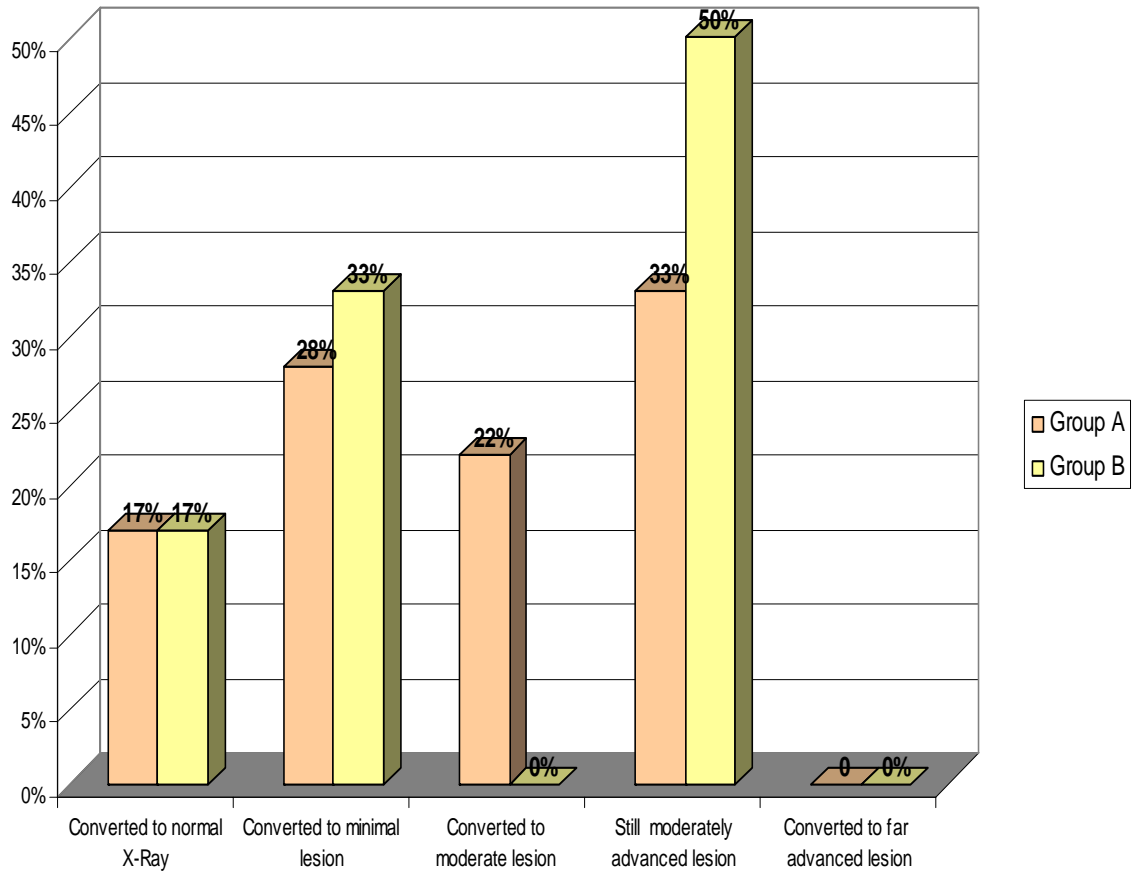


Figure (4) Radiological progress of moderately advanced TB lesion in the initial and final X-Ray films . N = 24 films

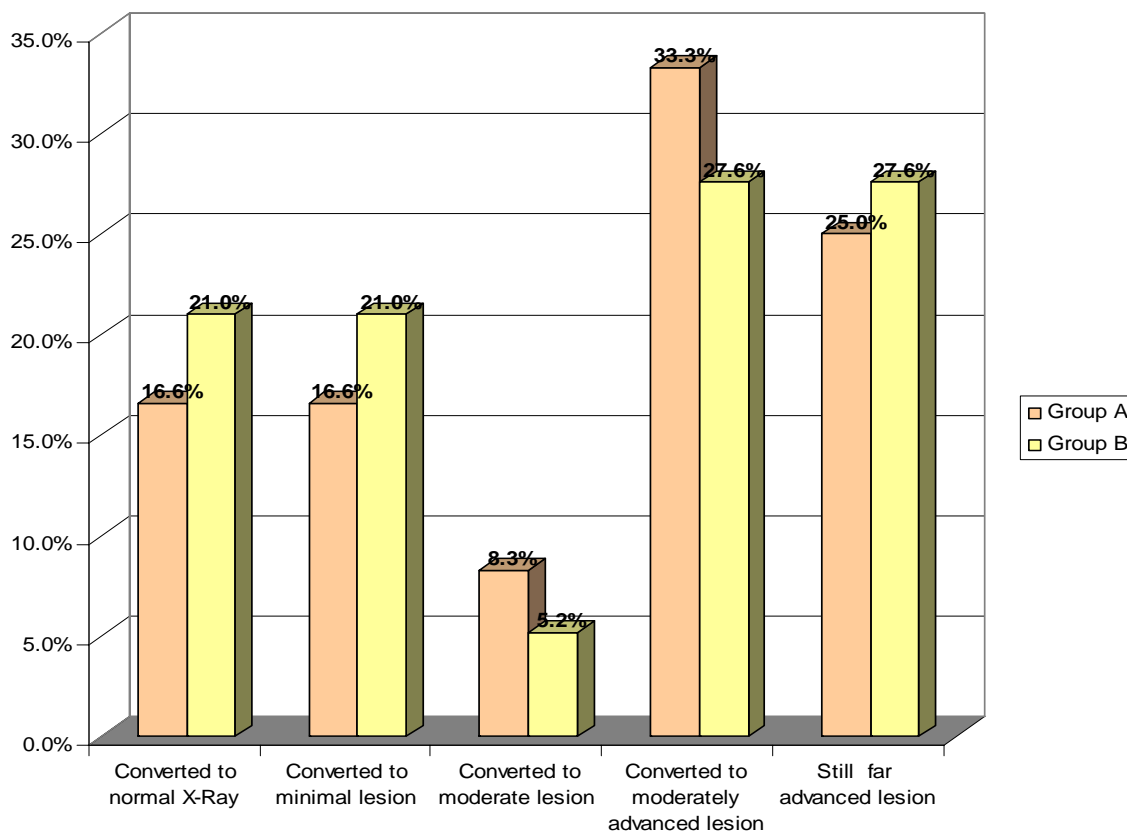


Figure (5): Radiological progress of far advanced TB lesion in the initial and final X-Ray films
N = 31 films

Concerning the progress of minimal lesion significantly high percentage was improved to normal 58% in group A and 53 % in group B, 42 % in group A and 40 % in group B stay as minimal lesion figure (3).

progress of moderate lesion result revealed that 14.3 % of the films been improved to normal in the intermittent group and 14.3 % of the films converted to minimal lesion and 72 % of the moderate lesion remained unchanged in intermittent group while in the daily group 100 % still moderate lesion figure (4).

The results of moderately advanced lesion revealed that both regimen cause an improvement of 17 % of this these types of lesion to normal, 28%, in the intermittent group and 33 % in the daily group were converted to minimal lesion, 22 % of the intermittent group were converted to

moderate lesion, 33% and 50 % of the intermittent and the daily group successively were not changed⁹.

The results of far advanced lesion revealed that intermittent regimen improved 16.6% of the X- Ray films to normal and minimal lesion , 8.3 % improved to moderate lesion , 33.3 % improved to moderately advanced lesion and 25 % remained unchanged , while in the daily regimen , 21 % were improved to normal and minimal lesion , 5.2 % to moderate lesion , 27 % to moderately advanced lesion and 27.6 % remained unchanged statistical analysis revealed significant difference between the two groups figure (6).

Discussion

Tuberculosis is now acknowledged to be one of the world's biggest and most pressing

health problem. The global burden of the disease based on data from 1990 showed that approximately 46.5 million disability adjusted life years were lost due to Tuberculosis. This study focused on chest radiographic changes as one of the cost effective tools to assess treatment outcome among the two study groups, and though it is seldom possible to make confident diagnosis or declare cure only on radiological grounds, however the extent and pattern of the disease among the intermittent chemotherapy group and the standard daily regimen group was assessed by double reading of CXR by two independent observers to reduce observer errors. It is important to note that radiological changes are not merely drugs related. According to the classification of the national TB Association of the USA, which has proved useful for clinical and research purposes, about 2/3 of our study population revealed moderate and far advanced radiological pattern (fig 1). High percentage of far advanced lesion was detected among X-Ray films compared to minimal lesion 22.5% to 16.6% respectively; this indicates that the patients in the study area are late comers. Delay in diagnosis may be attributed to patients delay or health institutions delay. It was found that 31% of the films showed normal X-Ray which is higher than the situation in USA stated by Pepper and coworker⁸ who mentioned that normal chest X-Ray among patients with culture-confirmed pulmonary TB was 13%. The inconsistency of these results and the situation in USA is due to the high sensitivity of culture and the difference of the culture-confirmed diagnostic facilities between Sudan and USA.

The high numbers of normal CXR (Fig1) found in this study may be due to localized postprimary endobronchial tuberculosis. Given positive sputum for AFB and normal CXR⁵ many investigators revealed that enlargement of hilar or paratracheal lymph nodes is unusual in European adults. In our study like other Asian and African countries lymphadenopathy is a usual finding reference. TB limited to lower zones of the lung though unusual, it was found in 30 % in this study.

Many studies from northern Africa, Asia and Poland have investigated and described intermittent regimens as satisfactory⁶.

Bronchiectasis was not detected in this study even in patients followed up for 18 months after completion of their regimen, which is different from 7% bronchiectasis found in Jordan¹⁰. Table (1).

Conclusion and recommendations

Radiologically the twice weekly 6 month intermittent is as effective as the daily regimen. Delay in case identification was observed and it may be due to patients faults in the study, the high percentage of normal X-Ray (30%) needs further investigation for those smear positive and normal X-Ray.

Adoption of intermittent chemotherapy in Sudan is cost effective and strongly recommended.

References

- 1- Elkheir H.K. Evaluation of six months regimen of Tuberculosis treatment at Khartoum state. 2005 : 84.
- 2- Al-Hajjaj M.S. and Johary I.A., Predictors of Radiological Sequelae of Pulmonary Tuberculosis, *Acta Radiologica* 2000;41(6): 533-537.
- 3- Singh V. TB in developing countries: diagnosis and treatment, *pediatric. respir. rev.*, 2006, 7 suppl 1: S132-5.
- 4-Manogna Maddineni and Mukta Panda , Pulmonary Tuberculosis in a Young Pregnant Female: Challenges in Diagnosis and Management , *Infect. Dis. Obstet. Gynecol.* 2008; 10 : 1155 .
- 5- Leung A.N, Muller N.I, Pineda P.R et al. Tuberculosis in childhood: radiologic manifestations, *Radiology.* 1992; 182-87.
- 6- Campell I.A. and Dyson A.J. Lymph node tuberculosis a comparison of various methods of treatment. *Tubercle* 1977; 58(4):171-9.
- 7-Lawson L, Yassin M.A, Thacher T.D et al. Clinical presentation of adults with pulmonary tuberculosis with and without HIV infection in Nigeria, *Scand. J. Infect. Dis* 2008; 40(1):30-5.
- 8-Pepper T, Joseph P, Mwenya C et al. Normal chest radiography in pulmonary tuberculosis: implications for obtaining respiratory specimen cultures , *Int. J. Tuberc Lung Dis* 2008 ; 12(4):397-403.
- 9-Centers for Disease Control and Prevention (CDC), Trends in tuberculosis—United States, *MMWR Morb Mortal Wkly Rep.* 2008;57(11):281-5.
- 10- El-Khushman H, Momani J.A, Sharara A.M et al. The pattern of active pulmonary tuberculosis in adults at King Hussein Medical Center, Jordan, *Saudi Med J.* 2006; 27(5):633-6.

