

## Original Article

### A Clinicopathological Study of Urinary Bladder Neoplasms in Patients at Three Centers in Khartoum, Sudan

Nazik Elmalaika O S Husain<sup>1</sup>, Ahmed I Shumo<sup>2</sup>, Salwa O Mekki<sup>3</sup>,  
Nadia I El Dawi<sup>4</sup>, Mohamed S A Kheir Elsid<sup>5</sup>

#### ABSTRACT

**OBJECTIVES:** To present the histopathological pattern of urinary bladder neoplasms using the WHO/ISUP classification system and relate it to the outcome.

**METHODS:** This study was conducted in the period from January 2004 through December 2005 at three centres in Khartoum, Sudan. One hundred and six patients with urinary bladder neoplasms were included in the study.

**RESULTS:** The commonest affected age group was 60-80 years with male to female ratio 4.6:1. Urothelial neoplasms were found in 72 (67.9%), Squamous cell carcinoma (SCC) in 26 (24.5%), urothelial neoplasms with Squamous differentiation in 3 (2.8%), and other types in 5 (4.7%) of the patients. There were 43.4% of the urothelial neoplasms graded as papillary carcinoma of high grade, 52.6% papillary carcinoma of low grade, 1.3% papillary neoplasm of low malignant potential, 1.3% papilloma, and 1.3% was graded as flat neoplasm. Of the SCCs, twelve (42.9%) were poorly differentiated SCCs, nine (32.1%) moderately differentiated, and seven (25%) cases were well differentiated SCCs. Follow-up information was available in 32 patients. At last follow-up, fifteen (46.9%) patients were dead of the disease, twelve (35.5%) were alive with no evidence of disease, four (12.5%) were alive with disease, and one (3.1%) was alive and terminally ill.

**CONCLUSION:** Histological grade (P: 0.006), and muscle invasion (P: 0.002) were significantly associated with survival. A subset of the cases could not be assessed for muscle invasion due to inadequate sampling; we thus recommend proper trans-urethral bladder biopsy (TUBP) sampling.

**Key words:** Urinary bladder neoplasm; Papillary carcinoma; Squamous cell carcinoma; WHO/ISUP classification system

**A**lthough there are improvements in detection and management of urinary bladder neoplasms (UBN), the death toll remains high.

The histopathological pattern and outcome of UBN have not been identified to date in Sudan. Such information would facilitate preoperative risk stratification and case-mix-adjusted outcome comparison, and lead to the

1. Department of Pathology, Faculty of Medicine, Omdurman Islamic University, Omdurman, Sudan

2. Faculty of medicine, International University of Africa, Khartoum, Sudan.

3. Department of Pathology, Faculty of Medicine, Elneelain University

4. Head Department of Histopathology and Cytology, National Health Laboratory, Khartoum Sudan  
Dean Faculty of Medical Laboratories, Omdurman Islamic University

**Corresponding:** E mail: [nazic2002sd@yahoo.com](mailto:nazic2002sd@yahoo.com)

development of processes of care directed at improving outcomes and ultimately the quality of care for bladder carcinoma patients. A number of classification systems have been used to grade papillary neoplasms of the urinary bladder<sup>1,2</sup>. Grading of the UBN depends on the histology of the urinary bladder which has a similar composition to the ureters and renal pelvis, with the innermost lining being transitional epithelium (urothelium) and, extending outward, as lamina propria, muscularis propria, and adventitia or serosa<sup>3</sup>. The muscularis propria is divided into inner and outer longitudinal layers and a central circular layer; these are best individualized in the bladder neck region<sup>4</sup>. These anatomic landmarks are important for evaluating the depth of invasion of a bladder neoplasm.

The most widely used grading system is the World Health Organization (WHO) classification, introduced in 1973<sup>5</sup>. In an attempt to achieve uniformity in reporting and to improve the terminology, in 1998 the World Health Organization/International Society of Urologic Pathologists (WHO/ISUP) has introduced a consensus classification for grading of urothelial neoplasm of the urinary bladder<sup>6,7</sup>. This system was also adopted in the most recent WHO system for classifying bladder tumor, which will hopefully lead to an even greater consensus<sup>8</sup>. It recognizes a rare benign papilloma, a group of papillary urothelial neoplasms of low malignant potential, and two grades of carcinoma (low and high grade). Its main features are the division of the neoplastic lesions into flat and papillary and the separate evaluation of the papillary neoplasms for grade (based on architecture and cytology) and invasiveness (divided into lamina propria and muscularis propria levels)<sup>2</sup>.

The presently recommended nomenclature by the WHO is similar to the WHO/ISUP classification of 1998, but the diagnostic criteria are further defined for practice. The terms non-invasive have been added to low and high grade papillary carcinoma to emphasize biologic differences between these tumors and infiltrating urothelial cancer<sup>8</sup>.

### Methods

This is a descriptive retrospective study conducted in three medical centres: Soba University Hospital, Ibn Sina Hospital and the National Health Laboratory at Khartoum, Sudan. Soba University Hospital is a teaching university hospital. Ibn Sina Hospital is a specialized hospital for renal and gastrointestinal diseases. The National Health Laboratory (NHL) stands as a national reference laboratory and receives samples from different parts of Sudan.

Patients diagnosed to have urinary bladder neoplasms in the period from January 2004 through December 2005, were studied. 164

patients were reviewed, of which 106 were included in the study.

Exclusion criteria:

Patients who were not diagnosed histopathologically at the three centres and those with no adequate information were excluded (n= 58).

Data were collected using patient's records, direct interviews and a pre-designed questionnaire. The questionnaire covers all the personal information, the presenting symptom, its duration and the biopsy technique. Cystoscopy findings, tumor size as well as type of surgery were also reviewed. The formalin-fixed, paraffin-embedded histopathology slides were reviewed and the urothelial tumors were re-graded using the 2004 (WHO/ISUP) grading system by a single experienced pathologist.

Follow-up information was obtained from reviewing the pathology and clinical files and from contacting the attending physician or the patient himself or his family. Survival time is defined as the time from the diagnostic surgical procedure to the date of the most recent method of follow-up. The relationships between overall survival and tumor grade as well as overall survival and muscle invasion were investigated using the log-rank test<sup>9</sup> for categorical variables and a score test based on the Cox proportional hazards model<sup>10</sup> for continuous variables.

Data were fed to Statistical Package of Social Sciences (SPSS), version 10. T-test (unpaired) was used for the difference of the means. Person's Correlation Coefficient was used and  $P < 0.05$  was considered as statistically significant.

### Results

From January 2004 through December 2005, 106 patients were included in this study. 87(82.1%) patients were men. The male to female ratio for TCC was 6.2:1 but for SCC was 2.3:1. Their mean ( $\pm$ SD) age was 59.49 ( $\pm$ 13.7) range (18-90) years. When the pathology was fractionated; the mean age for TCC was 60.92 and for SCC was 55.47. The peak frequency for all cases was at the age of 60-80 years.

The presenting symptom of UBN was gross hematuria in 75 (84.3%), painful micturition in 35 (39.3%), urgency in 14 (15.7%), palpable pelvic mass in 03 (03.4%), microscopic hematuria in 03 (03.4%), and others in 41 (46.1%) of the studied patients. Other symptoms include suprapubic pain, urine retention, and weight loss. The duration of symptoms varied from one week to 6 years. Among the total, 52.9% of the patients had symptoms <6 months duration, while 47.1% had symptoms of >6 months. In 80/106 studied patients, the location of UBN in the cystoscopy examination was as follows: lateral walls, 36 (45%); anterior wall, five (6.3%); posterior wall, four (5%); dome, three (3.8%); neck, 2 (2.5%); ureteric orifices, 2(2.5%); and multiple sites, 28 (35%). 39 out of 76 (51.3%) TCC cases were papillary, 19 (25%) were solid, and 18 (23.7%) showed both papillary and solid configuration.

Forty eight out of eighty two (58.5%) patients showed tumor size of >6cm at presentation, thirteen (15.9%) were 3-6cm, and 21 (25.6%) were of <3cm at presentation. Eighty two (77.4%) of the specimens were trans-urethral bladder biopsies (TUBPs), 18 (17%) were samples of trans-urethral resection of bladder tumors (TURBTs), four (3.8%) cystectomies, one (0.9%) was true-cut needle biopsy, and one (0.9%) specimen was obtained during laprotomy. Histopathologically, TCC with its different grades was seen in 72 (67.9%), SCCs in 26 (24.5%), TCC with squamous differentiation in three (2.8%) and others in five (4.7%) patients. The others include adenocarcinoma (2 patients), liposarcoma, leiomyosarcoma, and malignant fibrous histiocytoma. There were 43.4% of TCC patients graded as papillary carcinoma of high grade (Figure 1), 52.6% papillary carcinoma of low grade, 1.3% papillary neoplasm of low malignant potential, one papilloma, and another was graded as a flat neoplasm at presentation. 28/76(36.8%) of TCCs showed histologically signs of muscle invasion (infiltrative) at diagnosis and 21 (27.6%) with no muscle

invasion, whereas 27 (35.5%) contain no muscle to assess invasion in the specimen provided.

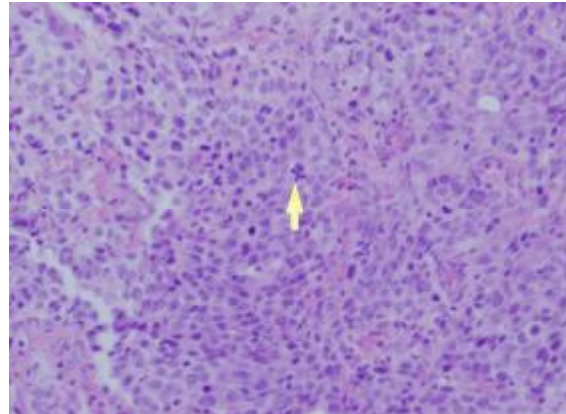


Figure (1): *Infiltrative urothelial carcinoma, high grade. The architecture is disordered and there is nuclear pleomorphism, hyperchromasia and abnormal mitosis (arrowed). (H&E. X40).*

In the current study, 12 (42.9%) of the SCCs were poorly differentiated (Figure 2), nine (32.1%) moderately differentiated, and seven (25%) were well differentiated SCCs. At last follow-up, 15 patients (46.9%) were dead of disease, 12 (35.5%) were alive with no evidence of disease, four (12.5%) were alive despite not being disease free, and one (3.1%) was alive and terminally ill.

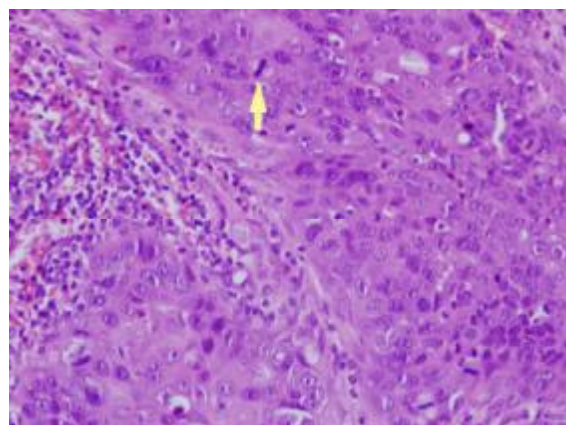


Figure (2): *Squamous cell carcinoma poorly differentiated. Large cells with pleomorphic nuclei, prominent nucleoli and mitosis (arrowed) (H&E. X40).*

Figure 3 shows the relationship between muscle invasion and outcome of UBN in the studied patients. Figure 4 shows the

relationship between grades and outcome of UBN among the studied patients.

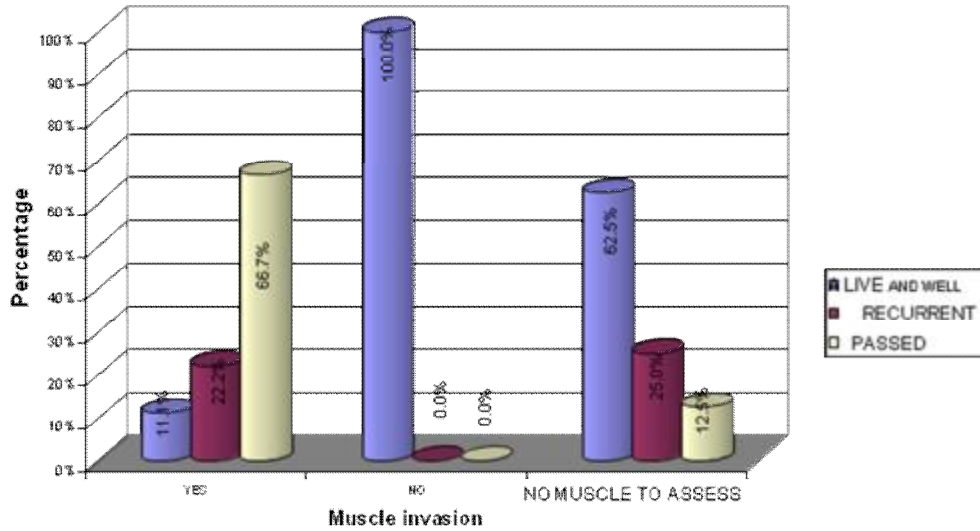


Figure (3): Relationship between muscle invasion and outcome of UBN in the studied patients (P=0.002).

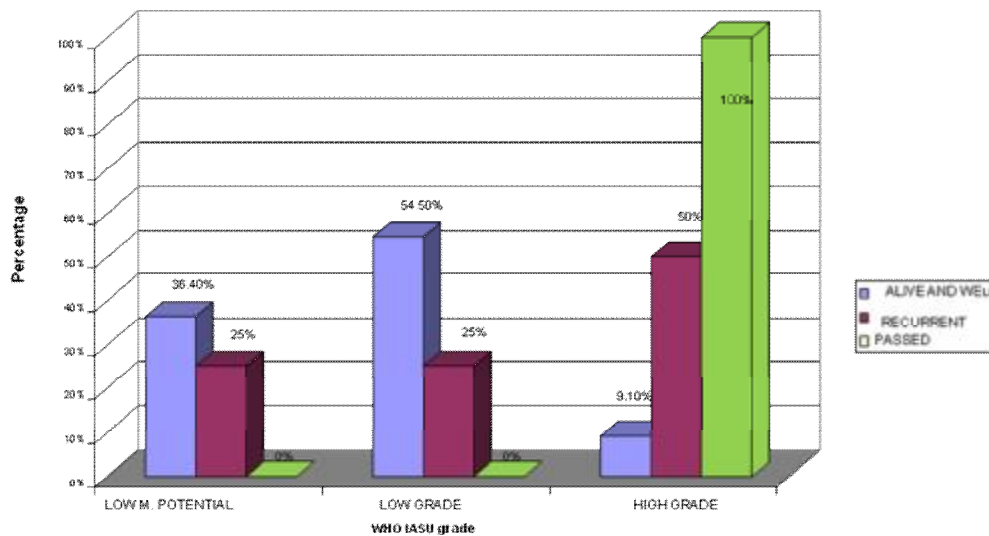


Figure (4): Relationship between histological grades and outcome of UBN among the studied patients (P=0.006).

## Discussion

Urinary bladder neoplasms are a heterogeneous group of tumors with different subtypes and behavioural patterns, therefore, the epidemiological and clinicopathological comparison is relatively difficult.

The demographic characteristics of the patients in the current study were relatively similar to a number of previous studies, which describe a peak incidence in the seventh decade and predominance in men with a male-to-female ratio of 4:1 to 4.4:1<sup>11,12</sup>.

Clinically, the commonest presenting symptom was haematuria occurring in 87.7% of the patients. This was described as gross and painless hematuria in 84.3% of cases. To complicate matters it can be the only clinical presentation of urinary schistosomiasis, which is relatively common in sub-Saharan Africa. Due to lack of health awareness, in the under-developed nations, patients who develop bladder neoplasm in conjunction with schistosomiasis present with advanced disease. This in part explains the large number of patients presenting with other symptoms (46.1%) including suprapubic mass, obstructive uropathy and weight loss on the first visit.

These results were similar to those of Sharfi *et al* who report that 82% of patients present with total painless haematuria<sup>13</sup>.

There is an increased inter-individual variation in the duration of symptoms. In this study, it varies from one week to six years.

Cystoscopically, the lateral walls were found to be the commonest site of occurrence of UBN (45%). This is nearly similar to what was reported in UK where the lateral walls were affected in 37% of patients<sup>14</sup>. It differs from Sharfi's study where the bladder bases were found to be the commonest site of occurrence of cancer (28%)<sup>13</sup>. It also differs from what was reported from Egypt where the base was affected in 44.6% of cases<sup>15</sup>.

Although 58.5% of the studied patients presented with large tumour size (>6 cm), tumor size did not show a significant effect on the outcome (P=0.761).

Since cystoscopy and biopsy are the main diagnostic measures, most of the specimens in

this study were transurethral bladder biopsies (77.4%).

A common feature in this study to non-bilharzial bladder neoplasms is that histologically many were TCC (67.9%), while SCC accounted for 24.5%. This is relatively high when compared to a frequency of less than 5% in UK and USA<sup>8</sup>, and a relatively low when compared to the figures reported from Egypt and Iraq where SCC forms the bulk of cases (66.7% and 65%), and TCC forms only 23.4% and 28% respectively<sup>15, 16</sup>. This may suggest that schistosomiasis is not the main predisposing factor to urinary bladder neoplasms among Sudanese patients. Thorough search for the etiological factors is pending.

Surprisingly, in the USA - a non-bilharzia affected country- there are racial differences in histological findings, with Caucasians having 95% urothelial and 1.3% SCC, while the proportions in African Americans are 87.8% SCC and 3.2% urothelial neoplasms<sup>8</sup>. In South Africa, there are marked differences in histology between African Americans (36% SCC, 41% urothelial) and Caucasians (2% SCC, 94% urothelial)<sup>8</sup>. The association between race and the prevalence of SCC remains to be answered.

Different variants of TCC were identified in this study including the nested variant, clear variant as well as a rare low grade TCC with lymphoplasmacytic infiltrate in the fibrovascular core, which is an unusual finding.

In this study, the findings of TCC configuration are contrary to those of Sharfi *et al* where 58% of tumors were solid, and 33% were papillary. Our findings differ with reports from Egypt where solid fungating tumors constitute 68.5% and Iraq (52%) of all bladder neoplasms<sup>15,16</sup>. It should be noted that the solid tumors form only 18.9% of non-

bilharzial bladder cancer, 81.1% of which are papillary<sup>17</sup>.

Recent advances in the morphological, molecular, and quantitative evaluation of non-invasive, intraepithelial neoplasms of the urothelium have contributed to the refinement of the current classification and grading schemes. However, some controversies on the precise criteria and terminology exist, especially those concerning papillary lesions<sup>18</sup>.

In this study, only 32 patients (33.3%) were followed. Of these, 46.9% died. The commonest cause of death in this study was renal failure due to involvement of the ureters rather than wide-spread metastasis.

Despite the short duration of this study, follow up was difficult. This is due to a number of factors experienced in third world countries, the most important of which is that the majority of patients are based in rural underdeveloped regions. Secondly, the impoverished rural hospitals are under equipped with cystoscopy armamentarium and no specialist urological surgeons. The poor educational health and awareness background of many patients made follow up difficult. Follow-up cystoscopy is usually missed despite patients are not pathology free.

The recurrence rate within five years after partial resection was reported as high as 78%<sup>19</sup>. However, in this series only 12.5% of the surgically resected lesions showed recurrences and this low percentage is mostly attributed to the difficulties in follow up of patients.

In the current study, there is a statistically significant relationship between muscle invasion in TCC and the outcome of the disease ( $P=0.002$ ). This is supported by Blaveri, et al who evaluated the associations between measures of genomic instability and bladder cancer clinical phenotype using array-based comparative genomic hybridization and found that the fraction of genome altered was associated with worse outcome in muscle-invasive tumors, independent of other clinicopathological parameters ( $P=0.002$ )<sup>20</sup>.

Tumor grade showed a significant association with the outcome ( $P=0.006$ ) in this study. This is closely related to the findings of Messing E, et al. that, of the high-grade or invasive cases, the proportion of late stage (T2 or higher) tumors were significantly lower in the screening-detected bladder cancers compared to unscreened ones ( $P=0.007$ ). They pointed out to the importance of hematuria home screening which detects high-grade cancers before they become muscle invading. This significantly reduces bladder cancer mortality<sup>21</sup>. Better alternatives are presently available, and in the near future we will likely see urine tests for specific clinical conditions<sup>22</sup>. On the molecular level, there is no evidence for the benefit of routine screening for bladder cancer. However, prospective long-term studies are required to evaluate the benefits of bladder cancer screening; particularly in high risk groups<sup>23</sup>. It is time to detect cytogenetically high-grade cancers early, in a high risk population, in order to reduce bladder cancer mortality.

**Conclusion:** Urinary bladder neoplasms in this sample share some epidemiological features with other developing countries and others with developed countries. A high percentage of patients presented with locally advanced disease at the time of diagnosis. Pathologic grade and muscle invasion are the most valuable prognostic predictors of survival. A subset of the cases could not be assessed for muscle invasion due to inadequate sampling. Thus improvements in the TUBP techniques would be of benefit. We stress the significance of public health education and awareness amongst patients and health care professionals. Bladder cancer screening awareness programs should be implemented to improve the outcome.

## References

1. Bostwick DG, Mikuz G. Urothelial papillary (exophytic) neoplasms. *Virchows Arch* 2002; 441:109-116.
2. Bostwick DG, Ramnani D, Cheng L. Diagnosis and grading of bladder

- cancer and associated lesions. *Urol Clin North Am* 1999;26:493-507.
3. Reuter VE. Urinary bladder, ureter, and renal pelvis. In: *Sternberg SS. Histology for Pathologists*. 2nd ed. Philadelphia: Lippincott-Raven; 1997:838-839.
  4. Ordonez NG, Rosai J. Urinary tract. In: Rosai J, ed. *Ackerman's Surgical Pathology*. 9<sup>th</sup> ed. St. Louis: Mosby; 2004: 1163-1390.
  5. Mostofi FK, Sobin LH, Torloni H. Histological typing of urinary bladder tumours. Presented at *International Classification of Tumor*, 19, Geneva, 1973.
  6. Epstein JI, Amin MB, Reuter VR, et al. The World Health Organization/International Society of Urological Pathology consensus classification of urothelial (transitional cell) neoplasms of the urinary bladder: Bladder Consensus Conference Committee. *Am J Surg Pathol* 1998;22:1435-1448.
  7. Mostofi FK, Sesterhenn IA, Davis CJ Jr. *Dysplasia Versus Atypia Versus Carcinoma In Situ of Bladder*. New York: Churchill Livingstone, 1988.
  8. Eble JN, Sauter G, Epstein JI, et al. *Pathology and Genetics of Tumours of the Urinary System and Male Genital Organs*. Geneva: World Health Organization, 2004.
  9. Mantel N. Evaluation of survival data and two new rank order statistics arising in its consideration. *Cancer Chemother Rep* 1966; 50:163-170.
  10. Cox DR. *Analysis of Survival Data*. 1<sup>st</sup> ed. New York: Chapman and Hall, 1990.
  11. Waihenya CG, Mungai PN. Pattern of transitional cell carcinoma of the urinary bladder as seen at Kenyatta National Hospital, Nairobi. *East Afr Med J* 2004; 981(3):114-9.
  12. Mohammed S. Abomella. Genito-urinary cancer in Saudi Arabia. *Saudi Medical Journal* 2004; 25(5): 552-556.
  13. Sharfi AR, el Sir S, Beleil O. Squamous cell carcinoma of the urinary bladder. *Br J Urol* 1992; 69(4):369-71.
  14. Herr HW, Wartinger DD, Fair WR, Oettgen HF. Bacillus Calmette-Guerin therapy for special bladder cancer: a 10-year followup. *J Urol* 1992;147: 1020.
  15. Boulkany MN, Ghoniem MA, Mansour MA. Carcinoma of bilharzial bladder in Egypt. Clinical and pathological features. *Br J Urol* 1972; 44:561-70.
  16. Talib, H. The problem of carcinoma of the bladder in Iraq: critical review. *Br J Urol* 1970;42:571-574.
  17. Whitfield HN, Henary WF. *Textbook of genitourinary surgery*. 1985; vol.2:p.973-978.
  18. Montironi R, Lopez-Beltran A, Mazzucchelli R, Bostwick. Classification and grading of non-invasive urothelial neoplasms: recent advances and controversies. *Journal of Clinical Pathology* 2003; 56:91-95.
  19. Faysal MH, Freiha FS. Evaluation of partial cystectomy for carcinoma of bladder. *Urology* 1979;14(4):352-6.
  20. Blaveri E, Brewer JL, Roydasgupta R, et al. Bladder cancer stage and outcome by array-based comparative genomic hybridization. *Clin Cancer Res* 2005;11(19 Pt 1):7012-22.
  21. Messing EM, Young TB, Hunt VB, et al. Comparison of bladder cancer outcome in men undergoing hematuria home screening versus those with standard clinical presentations. *Urology* 1995; 45(3):387-96 .
  22. Malmstrom PU. Advances in intravesical therapy of urinary bladder. *Expert Rev Anticancer Therapy* 2004; 4(6):1057-67.
  23. Kirkali Z, Chan T, Manoharan M, et al. Bladder cancer: epidemiology, staging and grading, and diagnosis. *Urology* 2005; 66(6 suppl 1):4-34.