

Case Report

Bilateral Symmetrical Humeral Fracture on a Background of Multiple Myeloma and Humeral Capillary Hemangioma

Amechi Uchenna Katchy¹, Henry Chinedum Ekwedigwe², Ikenna Theophilus Ikele¹, Ifeanyi Victor Ugwu³, Francis Nduhuisi Ahaotu⁴, Chioma Nneka Ikele⁵

Departments of ¹Anatomy and ⁵Medical Rehabilitation, University of Nigeria Enugu Campus, Nsukka, ²Department of Orthopaedics, Federal University Teaching Hospital, Abakaliki, Departments of ³Pathology and ⁴Orthopaedics, National Orthopaedic Hospital, Enugu, Nigeria

Abstract

A 59-year-old female who was managed for multiple myeloma presented with spontaneous bilateral pathologic fracture of the distal third of both humeri. She had associated renal impairment and background diabetes mellitus. Biopsy of her bone specimen from surgery shows features in keeping with capillary hemangioma. The patient was properly optimized for surgery; she was reviewed by a nephrologist and endocrinologist before surgery. Her blood investigations showed that she was anemic. She was transfused with fresh whole blood and also had renal dialysis. She subsequently was offered bilateral retrograde locked intramedullary nailing of both humeri, which was done 2 weeks apart under regional anesthesia (brachial plexus block). There was profuse intraoperative bleeding, which was controlled with bone wax and electrocautery. Biopsy of her bone specimen from surgery shows that she also has osseous capillary hemangioma rather than the provisional diagnosis of bilateral pathological fracture of the humerus following extramedullary manifestation of multiple myeloma. There have been suggestions in the literature that extra manifestations of multiple myeloma simulating hemangioma may be due to neoangiogenesis propagated by myeloma cells secreting vascular endothelial growth factor. We present a case of multiple myeloma with renal failure that presented to us with bilateral humeral fracture with a histological report of capillary hemangioma. We suggest that tumor-neoangiogenesis may be responsible for this type of manifestation. This case is a rare coincidental finding which has not been reported in literature, hence the objective of this presentation.

Keywords: Bilateral humeral fracture, capillary hemangioma, multiple myeloma, neoangiogenesis, vascular endothelial growth factor

INTRODUCTION

Myeloma is a malignant proliferation of neoplastic plasma cells of B-cell lineage within the bone marrow, leading to increased production of plasma paraprotein and immunoglobulin.^[1,2] The median age at diagnosis is 70 years, and it is infrequently diagnosed before the age of 40 years.^[2] It is the most common primary malignant lesion arising in the bone.^[2] There is the presence of a triad of bone marrow infiltration by plasma cells, lytic bone lesions, and the presence of M-protein in serum/urine. A mnemonic sometimes used to remember the common tetrad of multiple myeloma is “CRAB” (C: calcium [elevated], R: Renal failure, A: Anemia, B: Bone lesion).^[3] Patients may present with pathologic fractures of long bones or vertebral collapse, hypercalcemia, pancytopenia, and renal impairment owing to a combination of factors –deposition of light chains, hypercalcemia, hyperuricemia, and rarely deposition of

amyloid.^[1] Pathologic fractures occur in approximately 40% of patients.^[2] However, bilateral symmetrical fractures are rare.^[4,5]

The hemangiomas that occur in bones are seen most frequently in the skull or spine and rarely occur in other bones. It is the most common in people who are 40–50 years of age.^[6] Capillary and cavernous types are the most common hemangiomas found in bone. The tumors are slow-growing and are generally asymptomatic.^[6] The coincidental finding

Address for correspondence: Dr. Ikenna Theophilus Ikele,
Department of Anatomy, University of Nigeria, Enugu Campus,
Nsukka, Nigeria.
E-mail: ikenna.ikele@gmail.com

This is an open access journal, and articles are distributed under the terms of the Creative Commons Attribution-NonCommercial-ShareAlike 4.0 License, which allows others to remix, tweak, and build upon the work non-commercially, as long as appropriate credit is given and the new creations are licensed under the identical terms.

For reprints contact: WKHLRPMedknow_reprints@wolterskluwer.com

Quick Response Code:



Website:
www.njmonline.org

DOI:
10.4103/NJM.NJM_132_20

How to cite this article: Katchy AU, Ekwedigwe HC, Ikele IT, Ugwu IV, Ahaotu FN, Ikele CN. Bilateral symmetrical humeral fracture on a background of multiple myeloma and humeral capillary hemangioma. *Niger J Med* 2020;29:730-3.

Submitted: 10-Jul-2020

Revised: 27-Jul-2020

Accepted: 19-Sep-2020

Published: 24-Dec-2020

of bilateral humeral hemangioma, multiple myeloma, and bilateral symmetric pathologic fracture is exceedingly rare.

Here, we report the case of a woman who is being managed for multiple myeloma, and she presented with a bilateral pathologic fracture of the distal third of the humerus and who had associated renal impairment and background diabetes mellitus. Biopsy of her bone specimen from surgery shows that she also has osseous capillary hemangioma rather than the provisional diagnosis of bilateral pathological fracture of the humeri following extramedullary manifestation of multiple myeloma.

Meenakshi *et al.* in a report of two cases of extramedullary manifestations of multiple myeloma simulating hemangioma had suggested neoangiogenesis propagated by myeloma cells as a contributor to the unusual morphological manifestations of extramedullary manifestations of multiple myeloma.

CASE REPORT

A 59-year-old female was referred to us by a hematologist. She presented with complaints of left and right upper arm pain of 4-weeks and 2-weeks duration, respectively; there was associated history of sudden onset of inability to raise both upper limbs in one piece. She also complained of easy fatigability, weakness, and anorexia. There was a marked restriction of physical activity due to tiredness for the past 3 months. There was no history of significant trauma. The patient is a known diabetic mellitus patient on medications. Examination of the patient revealed a conscious middle-aged woman, she was afebrile, pale, not dehydrated, not cyanosed, and there was no significant edema or peripheral lymphadenopathy. Her vital signs were normal. Examination of the musculoskeletal system revealed tenderness at the distal third of both upper arms. The patient could not raise both upper limbs in one piece. The distal neurovascular status was normal in both upper and lower limbs. The chest was clinically clear. There were no significant findings in other systems.

Investigation result

The laboratory results gave the following values: full blood count was normal except for the hemoglobin level of 7.0 g/dl and erythrocyte sedimentation rate of 110 mm/1st h WG.

The serum electrolyte urea and creatinine showed sodium 136 mmol/L, potassium 4.3 mmol/L, chloride 100 mmol/L, urea 200 mmol/L (normal 10–50), and creatinine 4 mmol/L (normal 0.5–1.2).

The urinalysis showed the presence of Bence Jones proteins and a monoclonal spike of free κ light chains on electrophoresis.

The serum protein electrophoresis showed a monoclonal spike in the immunoglobulin gamma region. The serum globulin assay revealed immunoglobulin A: 156 (reference range: 70–400 mg/dl), immunoglobulin G: 1873 (reference range: 700–1600 mg/dl), and immunoglobulin M: 177 (reference range: 40–230 mg/dl).

The bone marrow aspirate biopsy showed the presence of an increased number of mononuclear cells with eccentric nuclei in keeping with plasma cells. The plasma cells constitute about 30% of the marrow nucleated cells. The histological report concluded that the bone marrow plasmacytosis was in keeping with multiple myeloma.

Following the above findings, a diagnosis of multiple myeloma with symmetrical bilateral humeral pathological fracture and renal failure in a known diabetic mellitus patient was made. X-rays of both humeri revealed lytic lesions on both humeri with fracture of both distal shafts at about the same point [Figure 1a]. The patient was reviewed by an endocrinologist and nephrologist who optimized her condition for surgery. The patient had central intravenous cannulation for the delivery of fluids and drugs. She was transfused with fresh whole blood to optimize her blood level. She received 6 units of blood all through her admission. She had renal dialysis twice before surgery. She subsequently had internal fixation of the fractures with retrograde locked intramedullary nails which had started healing at the time of this report [Figure 1b]. The surgical fixation of both humeri was done 2 weeks apart under brachial plexus block to limit her metabolic response to trauma. Histology specimen taken from both humeri during surgery showed a benign neoplastic lesion composed of proliferating small-sized vascular channels lined by unremarkable endothelium and interspersed by fibrocollagenous tissue, most of them containing blood cells. These findings were in keeping with the features of capillary hemangioma [Figure 2a and b]. Her postoperative condition has been stable, she had regained good bilateral arm function, and her elbow and shoulder range of motion had been adequate. She was subsequently referred to the oncology clinic for her chemotherapy. The patient is presently doing well and getting along with her activities of daily living.

DISCUSSION

Multiple myeloma is the most common primary malignant

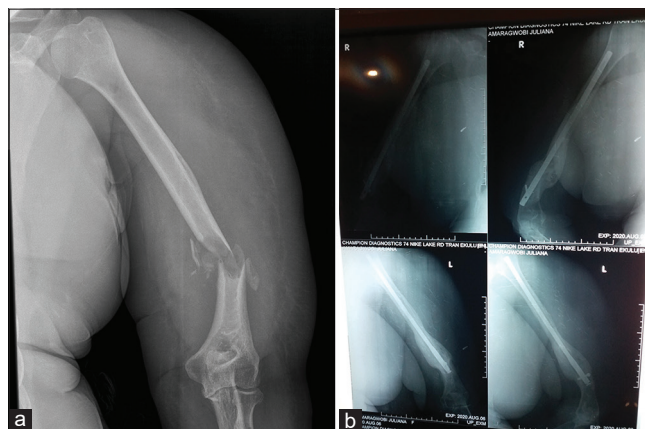


Figure 1: (a) X-ray showing pathological humeral fracture of the distal third of the humerus. (b) Healed bilateral humeral fractures of with mirror images that were fixed with retrograde interlocking humeral nails

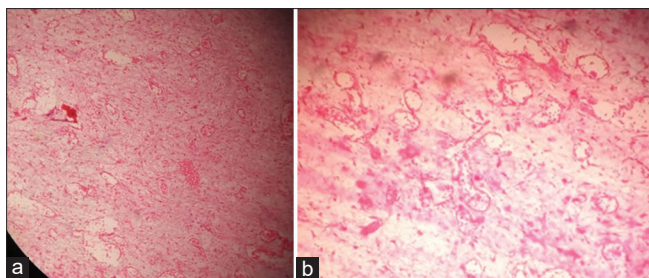


Figure 2: (a and b) Histological slide of the biopsy showing features of capillary hemangioma

lesion arising in the bone; it has an estimated incidence of 3000 per annum in the United Kingdom.^[2] Bone pain especially is a presenting symptom of myeloma in 60% of cases.^[7] Presentation of the disease as bilateral, symmetrical fractures is extremely rare and has been reported by few authors.^[4,5] To our knowledge, multiple myeloma presenting with bilateral symmetrical distal humeral fracture and capillary hemangioma has not been reported before. This coincidence is rare and surprising because hemangioma of other bones apart from the skull and vertebral hemangioma are not common.^[8] Myeloma lesions are sharply defined small lytic areas of bone destruction with no reactive bone formation. The most common sites include the vertebrae, ribs, skull, pelvis, and proximal long bones.^[7] Other clinical presentations of multiple myeloma include fatigue, anemia, recurrent infection (often pneumococcal), symptoms of renal failure, and hypercalcemia.^[9] The index patient presented with easy fatigability, anemia, and renal failure.

Urinalysis shows the presence of Bence Jones proteins in about 49% of cases. In 83% of multiple myeloma cases, serum electrophoresis produces a single band called a monoclonal spike on M-band.^[9] Urinary electrophoresis shows a spike in 75% of cases.^[9] Bone marrow shows abundant plasma cells in contrast to normal marrow, which contains <4% of plasma cells.^[9] In the present case, bone marrow examination demonstrated abundant plasma cells, and she had an abnormally elevated pattern of immunoglobulin G. Patients with multiple myeloma and associated renal insufficiency benefit from intermittent renal dialysis.^[10] This will help to normalize the renal function to a reasonable extent before surgery as was the case in our patient.

Shaft fractures in patients with a metastatic bone tumor should always be treated by internal fixation, and in most cases, intramedullary nailing is the most effective method of stabilization.^[2] This is because it also fixes already weakened areas of the shaft where the fracture is imminent. The bilateral humeral fractures in the index patient were fixed with retrograde nailing because of the distal nature of the fractures. Other studies had shown that retrograde nailing of distal humeral fractures gives satisfactory arm function postoperative and excellent recovery of shoulder and elbow functions.^[11] Upper extremity regional anesthesia is a practical alternative to general anesthesia for significant surgery on the

upper limb; it provides superior quality of analgesia and avoids the common side effects associated with general anesthesia such as postoperative nausea and vomiting.^[12] The index patient benefitted from the brachial plexus block, and she was clinically stable in the immediate postoperative period. Brachial plexus block can be extremely useful in patients with significant comorbidities such as severe respiratory, cardiovascular disease, and diabetes mellitus because the patient does not need to fast before the surgery.^[12]

The capillary hemangiomas are largely asymptomatic; however, there could be a problem of excessive intraoperative blood loss during surgery.^[13] We experienced profuse bleeding during the surgical procedures; however, we were able to control the bleeding with bone wax and diathermy coagulation. Some people had used preoperative embolization of the feeding vessel to decrease vascularity of hemangiomas; however, this is where the diagnosis is made preoperatively.

Patients presenting with bilateral pathological fractures and multiple myeloma should be ruled out, and this can easily be done using plain X-rays and laboratory examinations though a biopsy is required for confirmation.^[14] We had this in mind when we sent the specimen for biopsy, but we were rather surprised when capillary hemangioma was reported. Formation of blood lakes (pseudoangiomatous pattern) in a plasmacytoma has been described by Lennert as an “anastomosing blood-filled channels which are uniformly interspersed in large areas of the compact proliferation of neoplastic plasma cells.” He further stated that, at a higher magnification and on silver stain, the spaces are lined with plasma cells, though the channels have neither a basement membrane nor a boundary of fibrous tissue.^[15]

The lesion of our indexed patient composed of proliferating small-sized vascular channels lined by unremarkable endothelium, interspersed by fibrocollagenous tissue, most of them containing blood cells similarly described by Lennert. Suggestions have been made by some authors^[15-19] that this type of extra manifestations of multiple myeloma is triggered by tumor-induced angiogenesis.

Vascular endothelial growth factor, a key angiogenic molecule and a multifunctional cytokine that acts both as a potent inducer of vascular permeability and as a specific endothelial cell mitogen, has been implicated in the induction of angiogenesis in various hematopoietic tumors including multiple myeloma, acute lymphoblastic leukemia of childhood, and non-Hodgkin lymphomas. It is further suggested that this neoangiogenesis induced by these tumors is more commonly seen during an active phase of multiple myeloma than during the quiescent phase and may also play a role in the progression or growth of myeloma.^[16,19-23] We believe that this phenomenon may explain what happened in our reported case.

CONCLUSION

We present a case of multiple myeloma with renal failure that presented to us with bilateral humeral fracture with a

histological report of capillary hemangioma. We suggest that tumor-neoangiogenesis may be responsible for this type of manifestation. We suggest further studies to explore this phenomenon.

Declaration of patient consent

The authors certify that they have obtained all appropriate patient consent forms. In the form the patient(s) has/have given his/her/their consent for his/her/their images and other clinical information to be reported in the journal. The patients understand that their names and initials will not be published and due efforts will be made to conceal their identity, but anonymity cannot be guaranteed.

Financial support and sponsorship

Nil.

Conflicts of interest

There are no conflicts of interest.

REFERENCES

1. Kelsey SM, Galagher CJ, Tate T. Medical oncology including haematological malignancy. In: Kumar P, Clark M, editors. *Kumar and Clark Clinical Medicine*. 5th ed.. London: WB Saunders; 2002. p. 501-2.
2. Jonathan S, Michael P. Tumours. In: Ashley B, David W, Michael R, editors. *Apley and Solomon System of Orthopaedics and Trauma*. 10th ed.. Boca Raton: Taylor and Francis Group; 2017. p. 214-7.
3. Alexa O, Veliceasa B. Multiple myeloma with bilateral humerus location. Case report. *Rev Med Chir Soc Med Nat Iasi* 2013;117:160-4.
4. Mouzopoulos G, Stamatakos M, Kouvaris C, Mouzopoulos D, Tzurbakis M. Spontaneous bilateral subcapital hip fracture due to multiple myeloma: An 18-month follow-up. *Eur J Cancer Care (Engl)* 2007;16:413-6.
5. Collins CD. Multiple myeloma. *Cancer Imaging* 2004;4 Spec No A: S47-53.
6. Greene AK, Rogers GF, Mulliken JB. Intraosseous "hemangiomas" are malformations and not tumors. *Plast Reconstr Surg* 2007;119:1949-50.
7. Meenakshi AN, Susan LA, Markku M. Extramedullary manifestation of multiple myeloma (systemic plasmacytoma) that simulates hemangioma. *Arch Pathol Lab Med* 2000;124:628-31.
8. Boccadoro M, Pileri A. Diagnosis, prognosis, and standard treatment of multiple myeloma. *Hematol Oncol Clin North Am* 1997;11:111-31.
9. Yu L, Cai L, Yu G, Zeng Z, Tao S. Solitary giant hemangioma of the humerus. *Orthopedics* 2009;32:925.
10. Gupta V, Srivastava NK, Khandelwal B. Spontaneous bilateral pathological fracture of the proximal humerus: A rare presentation of multiple myeloma. *JIACM* 2015;16:155-7.
11. Iggo N, Palmer AB, Severn A, Trafford JA, Mufti GJ, Taube D, *et al.* Chronic dialysis in patients with multiple myeloma and renal failure: A worthwhile treatment. *Q J Med* 1989;73:903-10.
12. Kumar P, Raju BC, David MC. Ultrasound guided brachial plexus blocks. *J Contin Educ Anaesth Crit Care Pain* 2014;14:185-91.
13. Singh A, Singh TP, Datta AK. Varied picture of multiple myeloma. *J Indian Med Assoc* 1974;62:348-51.
14. Lennert K. Histopathology and diagnosis of non-Hodgkin's lymphomas. In: *Malignant Lymphomas, Other Than Hodgkin's Disease: Histology, Cytology, Ultrastructure, Immunology*. Berlin, Germany: Springer-Verlag; 1978. p. 263-81.
15. Vacca A, Ribatti D, Roncali L, Dammacco F. Angiogenesis in B cell lymphoproliferative diseases. *Biological and clinical studies. Leuk Lymphoma* 1995;20:27-38.
16. Paweletz N, Knierim M. Tumor-related angiogenesis. *Crit Rev Oncol Hematol* 1989;9:197-242.
17. Bellamy WT, Richter L, Frutiger Y, Grogan TM. Expression of vascular endothelial growth factor and its receptors in hematopoietic malignancies. *Cancer Res* 1999;59:728-33.
18. Vacca A, Ribatti D, Roncali L, Ranieri G, Serio G, Silvestris F, *et al.* Bone marrow angiogenesis and progression in multiple myeloma. *Br J Haematol* 1994;87:503-8.
19. Yaccoby S, Barlogie B, Epstein J. Primary myeloma cells growing in SCID-hu mice: A model for studying the biology and treatment of myeloma and its manifestations. *Blood* 1998;92:2908-13.
20. Angelo V, Ribatti D, Roncali L, Dammacco F. Angiogenesis in B-cell lymphoproliferative diseases: Biological and clinical studies. *Leuk Lymphoma* 1995;20:27-38.
21. Vacca A, Ribatti D, Roncali L, Ranieri G, Serio G, Silverstris F, *et al.* Bone marrow angiogenesis and progression in multiple myeloma. *Br J Haematol* 1994;87:503-8.
22. Lin J, Hou SM, Hang YS, Chao EY. Treatment of humeral shaft fractures by retrograde locked nailing. *Clin Orthop Relat Res* 1997; (342):147-55.
23. Fox MW, Onofrio BM. The natural history and management of symptomatic and asymptomatic vertebral hemangiomas. *J Neurosurg* 1993;78:36-45.