

Case Report

Glycemic Control in an Undiagnosed Diabetes Mellitus Patient with Coronavirus Disease 2019

Nwawueze Andrew Efam Okonta¹, Taofeek Oloyede¹, Olayinka Rasheed Ibrahim², Bashir Olajide Yusuf¹, Abdallah Sanda³, Bello Muhammed Suleiman²

Departments of ¹Internal Medicine, ²Paediatrics and ³Medical Microbiology, Federal Medical Centre, Katsina, Nigeria

Abstract

Diabetes mellitus in coronavirus disease 2019 (COVID-19) patients is associated with poor outcomes due to poorly understood reasons inclusive of blood sugar patterns. Hence, we report a case of a 52-year-old Nigerian man known hypertensive heart disease patient, previously undiagnosed diabetes mellitus patient with difficulty in blood sugar control, heart failure, and persistent severe acute respiratory syndrome coronavirus 2 8 weeks after he tested positive. A 52-year-old male civil servant obese, known hypertensive heart disease patient presented with complaints of fever, cough, difficulty with breathing, headache, and generalized body weakness. At presentation, he had respiratory distress with low oxygen saturation of 78% and hyperglycemia (blood sugar of 40 mmol/l). His body mass index was 35.9 kg/m². Chest radiography showed ground-glass appearance with cardiomegaly. Over the next 10 days on admission, his blood sugar fluctuated between hyperglycemia and an episode of hypoglycemia with occasional euglycemia and had glycated hemoglobin of 10.8%. The full blood count was normal, electrolyte, urea and creatinine showed mild elevation of the urea and creatinine, other parameters were normal, while the lipid profile showed hypercholesterolemia. He received multiple doses of insulin, anti-hypertensive, lopinavir/ritonavir, methylprednisolone, and azithromycin. The patient was weaned off oxygen after 10 days and discharged home 15 days after admission. This case report highlighted the challenges that may face a patient with undiagnosed diabetes mellitus and COVID-19. It also brings forth the need to expand research options in COVID-19 and risk factors associated with the disease as the world strives to control the global pandemic.

Keywords: Coronavirus disease 2019, glycemic control, undiagnosed diabetes mellitus

INTRODUCTION

Coronavirus disease 2019 (COVID-19) is an acute respiratory tract infection that is caused by severe acute respiratory syndrome coronavirus 2 (SARS-CoV-2). It presents with symptoms with severity ranging from a mild flu-like illness to severe viral pneumonia that is potentially fatal.^[1,2] Symptoms may start from 2 days to 2 weeks following exposure to the virus, with some of the patients being asymptomatic.^[3] Diabetes mellitus is characterized by high blood glucose concentration resulting from defects in insulin secretion, insulin action, or both.^[4] The relationship between diabetes and infection has long been clinically recognized.^[5] Nevertheless, the fact remains that controversies exist regarding whether diabetes mellitus itself indeed increases susceptibility and impacts outcomes from infections, including SARS-CoV-2, or the renal and cardiovascular comorbidities that are often associated with diabetes are the main factors involved.^[6]

Despite the ample publications and reports on blood sugar control in different illnesses, a literature search on blood sugar patterns in

COVID-19 patients with severe disease did not show any report. Scarce data exist on glucose metabolism and the development of acute complications of diabetes mellitus in patients with COVID-19. Hence, we reported a case of a 52-year-old Nigerian man known hypertensive heart disease patient with undiagnosed diabetes mellitus who presented with severe COVID-19 in heart failure and difficult to control blood sugar until the 10th day.

CASE REPORT

A 52-year-old male civil servant obese, known hypertensive heart disease patient who presented to our emergency triage unit with complaints of fever, cough, difficulty with breathing,

Address for correspondence: Dr. Nwawueze Andrew Efam Okonta, Department of Internal Medicine, Federal Medical Centre, Katsina, Nigeria.
E-mail: eephamyza@gmail.com

This is an open access journal, and articles are distributed under the terms of the Creative Commons Attribution-NonCommercial-ShareAlike 4.0 License, which allows others to remix, tweak, and build upon the work non-commercially, as long as appropriate credit is given and the new creations are licensed under the identical terms.

For reprints contact: WKHLRPMedknow_reprints@wolterskluwer.com

How to cite this article: Efam Okonta NA, Oloyede T, Ibrahim OR, Yusuf BO, Sanda A, Suleiman BM. Glycemic control in an undiagnosed diabetes mellitus patient with Coronavirus Disease 2019. *Niger J Med* 2020;29:726-9.

Submitted: 31-Jul-2020

Revised: 10-Aug-2020

Accepted: 09-Sep-2020

Published: 24-Dec-2020

Access this article online

Quick Response Code:



Website:
www.njmonline.org

DOI:
10.4103/NJM.NJM_141_20

headache, generalized body weakness, and malaise of 5 days duration. There was an associated history of orthopnea and paroxysmal nocturnal dyspnea. He was not a known diabetic. He did not smoke cigarettes but ingested alcohol (an average of 5 units in a day). For the hypertensive heart disease, he took oral amlodipine/valsartan 10/160 mg, spironolactone 25 mg, clopidogrel 75 mg, and frusemide 20 mg daily for the past 10 years. Examination findings at admission showed a severely obese middle-age man with a body mass index of 35.9 kg/m² and a waist circumference of 110 cm. He was in obvious respiratory distress, febrile with a temperature of 37.9°C, not pale, mild dehydration, not cyanosed, and had bilateral pitting pedal edema. The blood pressure was 140/90 mmHg; pulse rate was 102 bpm, regular, and full volume, oxygen saturation was 78% in room air, had bibasal crepitations on both lungs. The other systemic examination findings were not remarkable. He tested positive for SARS-CoV-2 using reverse transcriptase polymerase chain reaction. The investigation results showed a normal full blood count [Table 1]; chest X-ray showed ground glass appearance with cardiomegaly [Figure 1]; the point of admission random blood glucose was 40 mmol/l (laboratory). The blood sugar pattern showed hyperglycemia in the first 2 days of admissions. From day 3 to 10, he had a fluctuating blood sugar of hyperglycemia with occasional hypoglycemia [Figure 2]. Urinalysis showed pH = 6.2, glucose (++) , protein (+), nitrite (+), and glycated hemoglobin (HbA1c) of 10.8%. The lipid profile showed hypercholesterolemia [Table 1]. The electrolyte, urea, and creatinine showed mild elevation of urea and creatinine, with other parameters being normal [Table 1].

He was managed as a case of known hypertensive heart disease in heart failure with diabetes mellitus and COVID-19. The patient received intravenous amoxicillin-clavulanic acid, methylprednisolone, torsemide, subcutaneous (Sc) enoxaparin, oral azithromycin, zinc sulphate, Vitamin C, amlodipine/valsartan, and spironolactone. The symptoms of respiratory distress and heart failure improved over 48 h on admission and the oxygen at 8–10 L/min he received through nonrebreathing facemask was reduced to 4-5 L/min 5 days into

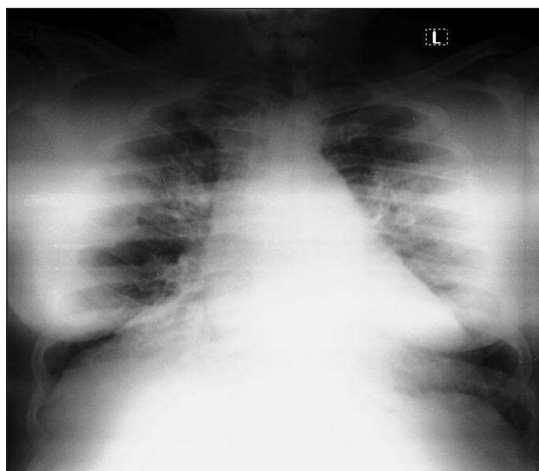


Figure 1: Chest radiograph of the patient (not pattern)

admission. He received 10 IU of soluble insulin for the first 24 h without achieving euglycemia. On the 2nd day, he was switched to insulin infusion at 60 IU in 500 ml of normal saline 6 h with hourly blood sugar check [Figure 2]. The glycemic

Table 1: Laboratory data of the patient

Test name	Result	Units	Normal ranges
Full blood count			
Packed cell volume	38	%	35-53
White blood cell count	8800	/mm ³	4.0-10.0
Platelet count	203	×10 ⁹ /L	100-350
Neutrophil	61	%	45-75
Lymphocyte	31	%	25-45
Monocyte	5	%	3-7
Basophils	0	%	0-1
Eosinophils	3	%	1-3
Electrolyte, urea, and creatinine			
Creatinine	128	umol/l	62-115
Urea	8.8	mmol/l	2.5-7.1
Sodium	143	mmol/l	135-145
Potassium	4.2	mmol/l	3.5-5.5
Chloride	100	mmol/l	98-108
Bicarbonate	24	mmol/l	21-28
Lipid profile			
Total cholesterol	203	mg/dl	≤200
Triglycerides	192	mg/dl	<200
HDL cholesterol	98	mg/dl	>60
LDL cholesterol	66.6	mg/dl	<100

HDL: High-density lipoprotein, LDL: Low-density lipoprotein

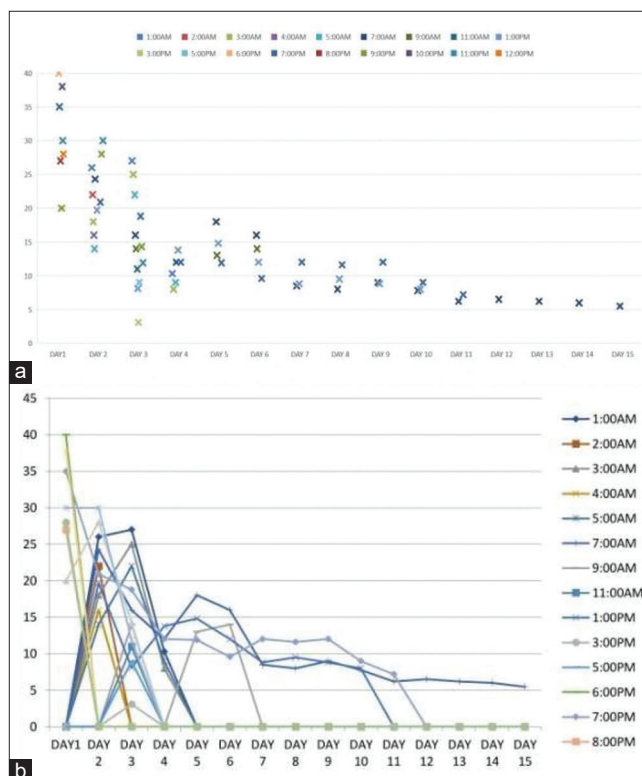


Figure 2: (a and b) Blood sugar pattern

control was still suboptimal on the 3rd day, with the insulin in the infusion increased to 80 IU with blood sugar check, as shown in Figure 2. On the 4th day, he was commenced on Sc isophane human insulin 20 IU 8 h with a 2 h infusion of normal saline + 40 IU of insulin and Sc Glargine 20 IU nocte with blood sugar check as shown in Figure 2. This regimen was maintained until the 6th day before the withdrawal of the infusion. Subsequently, vildagliptin/metformin 50/1000 mg twice daily was added, and Sc soluble insulin 20 IU, Sc Glargine 20 IU nocte was continued for the 7th, 8th, 9th and 10th days with blood sugar check as shown in Figure 2.

From the 11th day, he was commenced on Sc premixed Lispro 28 IU AM and 14 IU PM and vildagliptin/metformin 50/1000 mg twice daily with blood sugar checks, as shown in Figure 2. The regimen was continued till discharge on the fifteenth day and when proper glycemic control was achieved, as shown in Figure 2. He was maintained on tablets vildagliptin/metformin twice daily. He was weaned off oxygen therapy after 10 days on admission and discharged home 15 days after the admission on oral medications. On follow-up, he had euglycemia that ranged between 5.0 and 6.0 mmol/l.

DISCUSSION

Our patient was previously not a known diabetic but severely obese with markedly elevated random blood glucose on admission. He also had two-pluses of glucose in urinalysis with elevated HbA1c. Besides, he also presented with features of heart failure. Hence, he was diagnosed as a case of known hypertensive heart disease in heart failure with diabetes mellitus and COVID-19. While the features of heart failure and respiratory distress improved following the commencement of treatments, he had persistent hyperglycemia, which extended to the 10th day on admission with some difficulty before we achieved control of his blood sugar. He also had nitrite in the urinalysis, which could be explained by the lowered immunity in the patient, most likely from dysglycemia as there were no urinary symptoms.

Infection with SARS-CoV-2 in those with diabetes mellitus possibly triggers higher levels of stress conditions, with the more significant release of hyperglycemic hormones, for example, glucocorticoids and catecholamines, leading to hyperglycemia, and abnormal glucose variability.^[7,8] Hyperglycemia can cause injury to a large number of organs and tissues.^[9] Most cells in humans adapt to the rate of intracellular glucose transport under hyperglycemic conditions. However, β cells are unable to adapt and rather equilibrate their intracellular glucose level to the extracellular concentrations. Hence, they are more susceptible to the effect of hyperglycemia.^[10-12] Hyperglycemia can cause acute and chronic complications that represent important determinants of morbidity and mortality.^[13]

Diabetes and uncontrolled glycemia are significant predictors of severity and deaths in patients infected with different viruses, including the 2009 pandemic influenza A (H1N1),^[14] SARS-CoV,^[15] and Middle East respiratory syndrome-CoV.^[16]

Besides, the corticosteroids administered to hospitalized patients may cause acute hyperglycemia, suboptimal glycemic control, more extended hospital stays, and increased morbidity and mortality.^[17,18] In the current SARS-CoV-2 pandemic, some studies did not find a clear association between diabetes and severe disease.^[19,20] A recent meta-analysis could not confirm that diabetes increased the risk of COVID-19 infection but did find that it worsened the outcome.^[21]

Individuals with marked abdominal obesity also have mechanical respiratory issues, with reduced ventilation of the basal part of the lungs, increasing the risk of pneumonia and hypoxemia.^[22] Independent of diabetes, obesity is a significant risk factor for morbidity and mortality in COVID-19 infection. In a study from Italy, 48% of patients with COVID-19 admitted to an intensive care unit were obese.^[23]

There are concerns in patients of undiagnosed diabetes mellitus contracting COVID-19 infections as they have chances of a severe manifestation of pulmonary pathology. The unexplained interaction between diabetes mellitus and COVID-19 may set up a cascade of events in which COVID-19 produces critical poor glycemic control, which worsens the severity of COVID-19.^[24] The cytokine storm in COVID-19 may induce some form of insulin resistance and directly cause pancreatic beta-cell destruction, and this may lead to worsening of glycemic control in patients of diabetes mellitus due to the massive release of cytokines and proinflammatory mediators.^[24] Because of the increased mortality risk of diabetes mellitus with COVID-19, undiagnosed diabetes mellitus patients may be one of the worst sufferers if they happen to contract COVID-19 infection. The higher percentage of undiagnosed diabetes mellitus patients in Africa, in the scenario of the COVID-19 pandemic, may also progress to morbid states with COVID-19 and may add up to the mortality rates.

CONCLUSION

This case report highlighted the challenges that may face a patient with undiagnosed diabetes mellitus and COVID-19. It also brings forth the need to expand research options in COVID-19 and risk factors associated with the disease as the world strives to control the global pandemic.

Declaration of patient consent

The authors certify that they have obtained all appropriate patient consent forms. In the form the patient(s) has/have given his/her/their consent for his/her/their images and other clinical information to be reported in the journal. The patients understand that their names and initials will not be published and due efforts will be made to conceal their identity, but anonymity cannot be guaranteed.

Financial support and sponsorship

Nil.

Conflicts of interest

There are no conflicts of interest.

REFERENCES

- Gorbalenya A.E. Severe Acute Respiratory Syndrome-Related Coronavirus: The Species and its Viruses – A Statement of the Coronavirus Study Group; February, 2020.
- Ren LL, Wang YM, Wu ZQ, Xiang ZC, Guo L, Xu T, *et al.* Identification of a novel coronavirus causing severe pneumonia in human: A descriptive study. *Chin Med J (Engl)* 2020;133:1015-24.
- CDC. 2019 Novel Coronavirus, Wuhan, China: Symptoms. CDC. Available from: <https://www.cdc.gov/coronavirus/2019-ncov/about/symptoms.html>. January 26, 2020. [Last accessed on 2020 Jan 27].
- The Expert Committee on the Diagnosis and Classification of Diabetes Mellitus, *Diabetes Care*; 2000. p. 23. Available from: https://www.medscape.com/viewarticle/412642_2. [Last accessed on 2020 Jul 12].
- Pearson-Stuttard J, Blundell S, Harris T, Cook DG, Critchley J. Diabetes and infection: Assessing the association with glycaemic control in population-based studies. *Lancet Diabetes Endocrinol* 2016;4:148-58.
- Knapp S. Diabetes and infection: Is there a link? A mini-review. *Gerontology* 2013;59:99-104.
- Wang A, Zhao W, Xu Z, Gu J. Timely blood glucose management for the outbreak of 2019 novel coronavirus disease (COVID-19) is urgently needed. *Diabetes Res Clin Pract*. 162: 108118. p1-2. PMID: 32179126.
- Zhou J, Tan J. Diabetes patients with COVID-19 need better blood glucose management in Wuhan, China. *Metabolism* 2020;107:1-2.
- Shrayyef MZ, Gerich JE. Normal glucose homeostasis. In: Poretzky L, editor. *Principles of Diabetes Mellitus*. Boston, MA, US: Springer; 2010. p. 19-35.
- Lostanlen D, Oudea MC, Godard-Launay AN, Oudea P. Modifications of citrate and isocitrate metabolism in liver mitochondria of ethanol-fed rats. *Biochem Pharmacol* 1975;24:2061-8.
- Giugliano D, Ceriello A, Esposito K. Glucose metabolism and hyperglycemia. *Am J Clin Nutr* 2008;87:217S-222S.
- Brownlee M. The pathobiology of diabetic complications: A unifying mechanism. *Diabetes* 2005;54:1615-25.
- Orasanu G, Plutzky J. The pathologic continuum of diabetic vascular disease. *J Am Coll Cardiol* 2009;53:S35-42.
- Schoen K, Horvat N, Guerreiro NF, de Castro I, de Giassi KS. Spectrum of clinical and radiographic findings in patients with diagnosis of H1N1 and correlation with clinical severity. *BMC Infect Dis* 2019;19:964.
- Yang JK, Feng Y, Yuan MY, Yuan SY, Fu HJ, Wu BY, *et al.* Plasma glucose levels and diabetes are independent predictors for mortality and morbidity in patients with SARS. *Diabet Med* 2006;23:623-8.
- Banik GR, Alqahtani AS, Booy R, Rashid H. Risk factors for severity and mortality in patients with MERS-CoV: Analysis of publicly available data from Saudi Arabia. *Virology* 2016;31:81-4.
- Donihi AC, Raval D, Saul M, Korytkowski MT, DeVita MA. Prevalence and predictors of corticosteroid-related hyperglycemia in hospitalized patients. *Endocr Pract* 2006;12:358-62.
- Umpierrez GE, Isaacs SD, Bazargan N, You X, Thaler LM, Kitabchi AE. Hyperglycemia: An independent marker of in-hospital mortality in patients with undiagnosed diabetes. *J Clin Endocrinol Metab* 2002;87:978-82.
- Zhang JJ, Dong X, Cao YY, Yuan YD, Yang YB, Yan YQ, *et al.* Clinical characteristics of 140 patients infected with SARS-CoV-2 in Wuhan, China. *Allergy* 2020;75:1730-41.
- Lippi G, Plebani M. Laboratory abnormalities in patients with COVID-2019 infection. *Clin Chem Lab Med* 2020;58:1131-4.
- Fadini GP, Morieri ML, Longato E, Avogaro A. Prevalence and impact of diabetes among people infected with SARS-CoV-2. *J Endocrinol Invest* 2020;43:867-9.
- Dixon AE, Peters U. The effect of obesity on lung function. *Expert Rev Respir Med* 2018;12:755-67.
- Simonnet A, Chetboun M, Poissy J, Raverdy V, Noulette J, Duhamel A, *et al.* High prevalence of obesity in severe acute respiratory syndrome coronavirus-2 (SARS-CoV-2) requiring invasive mechanical ventilation. *Obesity (Silver Spring)* 2020;28:1195-9.
- Pal R, Bhadada SK. COVID-19 and diabetes mellitus: An unholy interaction of two pandemics. *Diabetes Metab Syndr* 2020;14:513-7.