

## Case Report

# LIPOMA OF THE TRANSVERSE COLON: REVIEW OF LITERATURE AND A CASE REPORT IN A YOUNG NIGERIAN FEMALE

Muktar Muhammad Umar<sup>1</sup>, Ahmed Hamza, Oloko Nasirudeen<sup>2</sup>, Adogu Adoge Ibrahim

Department of Surgery, Abubakar Tafawa Balewa University Teaching Hospital, Bauchi, Nigeria

<sup>1</sup> Department of Radiology, Abubakar Tafawa Balewa University Teaching Hospital, Bauchi, Nigeria

<sup>2</sup> Department of Histopathology, Abubakar Tafawa Balewa University Teaching Hospital, Bauchi, Nigeria

## ABSTRACT

Colonic lipomas are rare benign tumour of the gastrointestinal tract (GIT); however, they remain the commonest non-epithelial (mesenchymal) benign neoplasm of the GIT tract. The majority remains asymptomatic. They can mimic malignant tumours of the GI tract. We present a review of literature and our experience with the management of a case of this rare tumour.

A 35-year-old woman presented to us with an upper abdominal pain of six weeks, vomiting and passage of bloody mucoid stool of four weeks. A huge palpable mass in the epigastric region. Contrast-enhanced Computed tomography revealed a well-defined, 18cm, fatty tissue mass in the transverse colon. She had a right hemicolectomy. Histology confirmed the diagnosis revealing a submucosal lipoma. One year follow up, she remained symptom-free with no evidence of recurrence. This study raises the awareness of this rare tumour as a cause of GIT symptoms and highlights the challenges in differentiating it from the more common malignancy of the colon.

**KEYWORDS:** Colonic lipoma, lipoma of transverse colon, Non-epithelial tumour Nigerian female

NigerJmed 2020: 172-174  
© 2020. Nigerian Journal of Medicine

## INTRODUCTION

Colonic lipomas are rare subepithelial benign tumour of the colon. They are benign proliferations of mature fatty cells. They make up 0.035 to 4.4% of all intestinal neoplasms. They, therefore, constitute the commonest non-epithelial (mesenchymal) benign neoplasm of the GI tract<sup>1</sup>. Bauer first reported it in 1757.

The most common site is the ascending colon close to the caecum followed in descending order by rectum, sigmoid colon and descending colon. The tumour is relatively rare in the transverse colon. Only one case in the transverse colon to the best of our knowledge, has been reported from Nigeria.

We present a 35-year-old Nigerian female with submucosal transverse colonic lipoma presenting with a change in bowel habit. We herein also report a literature review of the clinical characteristics, diagnosis and treatment modalities of colonic lipomas.

### Case Report

A 35-year-old woman with complaints of progressively

increasing upper abdominal swelling and colicky abdominal pain of six weeks, vomiting and passage of muco-bloody stool of four weeks, she had no weight loss, loss of appetite nor easy satiety. No history of tenesmus. No cough or contact with chronic coughing patient. There was a negative past history of malignancy in the patient or her family members. No significant comorbid history. She does not smoke cigarette or ingest alcoholic beverages..

Physical examination revealed a young woman, not pale, anicteric, no significant lymphadenopathy with stable cardiovascular and respiratory systems. The abdomen was asymmetrical, moves with respiration, nil area of abdomen was tenderness. A palpable 18cm x 10cm irregularly-shaped, firm intra-abdominal mass over the epigastrium, non-tender, and freely mobile with a well-defined margin. Mass was not pulsatile and non-fluctuant. We could get above and below the mass, does not move with respiration with an absent medial notch. Succussion splash was absent. Liver, spleen and kidneys were not palpably enlarged. Ascites was no demonstrable, and bowel sound was normoactive. Rectal and vaginal examinations revealed normal findings.

A clinical diagnosis of the colonic tumour was made with differential diagnosis of omental tumour and ameboma of the colon. Axial abdominal computed tomography scan image at the level of part of the kidneys showed a rounded, well defined non-enhancing hypodense mass of fat density which appeared to be within the colonic wall in the left upper quadrant close to the left kidney, no bowel dilatation

### Correspondence to:

Dr Umar Muhammad M  
Department of Surgery,  
Abubakar Tafawa Balewa University Teaching Hospital, Bauchi, Nigeria  
umarmuktardr@gmail.com  
+2348038890294

seen. Features in keeping with an intra-abdominal lipoma of colonic origin. (fig.1). The Patient was booked for a pre-operative colonoscopy, but this was omitted due to logistic reasons in the colonoscopy suite at the time of management of the patient.

Carcinoembryonic antigen was less than 1 ng/ml. She was prepared and had laparotomy with an intra-operative finding of 18cm x 6cm firm, well-defined mass within the wall of the proximal transverse colon and a solitary 3cm x 2cm transverse mesocolonic lymph node. Other harvested lymph nodes were less than 2cm in size

She had right hemicolectomy with end to end ileo-transverse anastomosis.

She was discharged home on the seventh postoperative day. There were no untoward events post-operative before discharge.

Histologic analysis of the mass revealed submucosal sheets of matured adipocytes with peripherally displaced nuclei and abundant clear(vacuolated) cytoplasm in keeping with submucous lipoma of the transverse colon (figs 2A and B)

Section of the lymph node showed reactive hyperplasia in one lymph node. Others were essentially normal..

She had some episodes of diarrhoea following discharge from the hospital; she was reassured, and symptoms resolved spontaneously.

She has been followed up for one year, and she has remained asymptomatic – no evidence of recurrent disease.

#### Discussion

Lipomas, though rare non-epithelial benign colonic tumours, they represent the most common non-epithelial derived tumours of the gastrointestinal tract.

The disease is more commonly found in women, and its peak incidence is in the fifth and sixth decades of life. However, the disease can also be seen in younger patients. Our patient was a 35-year-old woman and to our knowledge is the youngest in English literature. The aetiology of the disease is unknown. Several theories have been propounded, but none have been widely accepted. Some authors proposed that fatty tissue accumulates in a certain area due to under-development of the arterial, venous and lymphatic circulation. Chronic irritation and inflammation of the colonic mucosa are believed by some to be responsible for forming colonic lipomas.

Our patient presented with an isolated and solitary transverse colonic lipoma. This agrees with previous cases reported in the literature. Commonly, about 90% of colonic lipomas are solitary, amongst which the most common site is the ascending colon close to the caecum (45%), sigmoid colon(30.3%),descending colon (1.2%) and transverse colon (9.1%) .The least common location is the transverse colon which is the location in our patient.

The submucosal location of the tumour in our index case is the common location in previously reported cases. 10% are, however subserosal; they may be sessile or pedunculated.

They are commonly asymptomatic. However, our index patient was symptomatic with dragging abdominal sensation and muco-bloody stools. This can be explained by the massive size of the tumour in our index patient. The 25% that are symptomatic are usually larger than 2cm in size . Crocetti and coworkers demonstrated a correlation

between size and symptoms, the larger the size, the severer the symptoms .

Preoperative diagnosis is important in planning treatment; however, differentiation from a malignant colonic lesion may be difficult. Patients devoid of symptoms are found incidentally during colonoscopy or a Computer tomography scan. Our patient was diagnosed correctly pre-operatively with a computer tomography scan.

A barium enema is a useful modality in preoperative assessment. It demonstrates a non specific filling defect, and a lobulated appearance may be seen<sup>5</sup>. However, this appearance is nonspecific, making differentiation from malignancy extremely difficult .

Computed tomography and magnetic resonance imaging that has the capabilities of demonstrating the fatty composition of the tumour but exclusion of local infiltration may be difficult . These two modalities have been used in accurate preoperative diagnosis as aptly demonstrated in our case.

During a colonoscopy, three signs may suggest the diagnosis: the “cushion sign” (flattening and restoration of the shape of the lipoma by a probing biopsy forceps), the “tenting effect” (grasping the overlying mucosa with biopsy forceps presents a tent-like appearance), and the “naked fat sign” (extrusion of fat after biopsy of the colonic mucosa). Biopsy by colonoscopy is discouraged in patients suspected of having a lipoma because the lesion is beneath the normal mucosa and thus a biopsy often is not representative of the tumour; thus, cannot completely exclude malignancy. In addition, a biopsy may increase the risks of complications such as bleeding and perforation; furthermore, there was a case report of colitis following biopsy .

At present, colon lipoma is difficult to differentiate preoperatively from a colon carcinoma, and the recommendation is the removal of the tumour in case of doubt. A firm and confirmatory diagnosis of colonic lipoma can only be established based on the histopathological examination . Therefore, the resection of symptomatic or greater than 2 cm in diameter colonic lipomas is mandatory but if the diameter is lower than 2 cm tumour removal should be reserved to cases of doubtful diagnosis.

There are various modalities for endoscopic treatment of the tumour. Endoscopic removal of colonic lipomas is recommended for lipomas smaller than 2 cm. If endoscopic removal is performed for lipomas greater than 2 cm, a significant risk of complications, especially for sessile lesions, is reported .However, endoscopic resection for larger tumours have been reported to be successful in experienced hands. Endoscopic ligation(loop-and-let-go) has also been reported to be successful in the management of large colonic lipomas . Endoscopic unroofing was tried by Tomiki and coworkers without success .These modalities were not considered in the index case due to its massive size of 18cm.

Surgical resection appears to be the ideal and more acceptable treatment for symptomatic large lipomas., especially when malignancy cannot be excluded. Excision can be done through a colotomy or segmental colon resection which permits complete removal of the lipomas. Recently different workers have reported laparoscopic resection as a good alternative to open conventional

surgery with all the documented advantages of minimally-invasive procedures . Intraoperative frozen section is used to guide surgery to prevent unnecessary radical resections .The huge size and being symptomatic were the indications for segmental resection in the index case. Unfortunately due to absence of frozen section (to unequivocally confirm the absence of malignancy)at our facility at the time of management of the patient we opted for a right hemicolectomy.

Data on long-term follow-up is nonexistent in literature. At one year follow up, the index patient was asymptomatic; this is similar to reports from previous workers. Most of the reports present a short follow up period. At a mean follow-up of 12 months, none of the workers reported problems related to the operation or recurrence of the disease .

In a systematic review by Crocetti and coworkers, no statistically significant differences were noted between patients treated with open or laparoscopic surgery .

In conclusion, a transvers colonic lipoma is a rare cause of abdominal symptoms, and unequivocal intra-operative differentiation from the common malignant tumor still remains a challenge in a low resource setting. Surgical tumour removal is the standard-of-care in the present day for large and symptomatic colonic lipomas and endoscopic removal for smaller tumour.

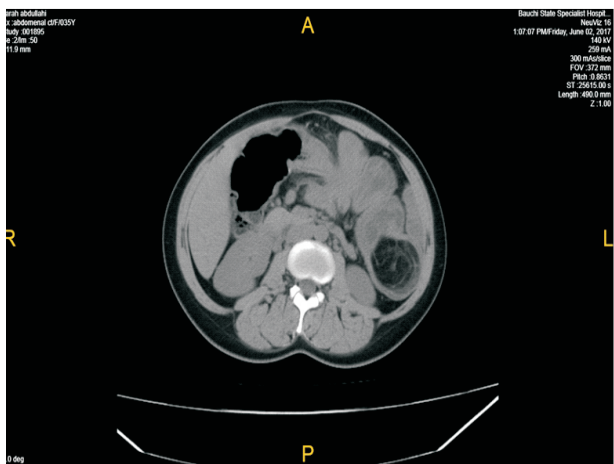


Fig 1. AXIAL COMPUTED TOMOGRAPHIC SCAN IMAGE AT THE LEVEL OF PART THE KIDNEYS SHOWING A ROUNDED DEFINED NON ENHANCING HYPODENSE MASS OF FAT DENSITY WHICH APPEARS TO BE WITHIN THE COLONIC LOOP IN THE LEFT UPPER QUADRANT CLOSE TO THE LEFT KIDNEY, NO BOWEL DILATATION SEEN. (intrabdominal lipoma –bowel origin)

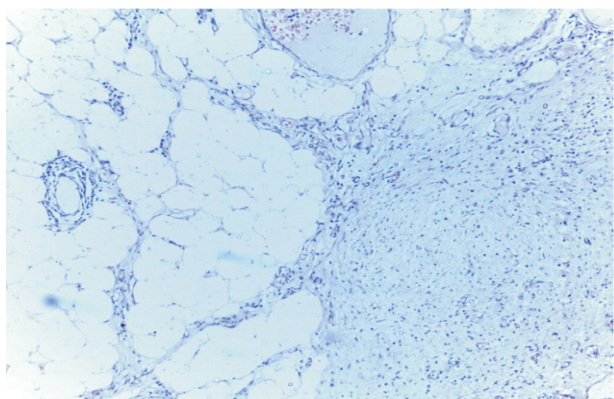


Fig 2A. Magnification x20 showing sheets of mature adipocytes overlying submucosal tissue

## REFERENCES:

1. Ryan J, Martin JE, Pollock DJ. Fatty tumours of the large intestine: a clinicopathological review of 13 cases. *Br J Surg.* 1989 Aug;76(8):793–6.
2. Rogy MA, Mirza D, Berlakovich G, Winkelbauer F, Rauhs R. Submucous large-bowel lipomas--presentation and management. An 18-year study. *Eur J Surg Acta Chir.* 1991 Jan;157(1):51–5.
3. Abiodun-Wright W, Keshinro S, Olumide F. Lipoma of the transverse colon presenting as simple intestinal obstruction: A Case Report. *Niger Postgrad Med J.* 2014 Dec;21(4):350–2.
4. Crocetti D, Sapienza P, Sterpetti AV, Paliotta A, DE Gori A, Pedullà G, et al. Surgery for symptomatic colon lipoma: a systematic review of the literature. *Anticancer Res.* 2014 Nov;34(11):6271–6.
5. Kwag S-J, Choi S-K, Jung E-J, Jung C-Y, Jung S-H, Park T-J, et al. Surgical Strategy for Colonic Intussusception Caused by a Giant Colonic Lipoma: A Report of Two Cases and a Review of the Literature. *Ann Coloproctology.* 2014 Jun;30(3):147–50.
6. Lazaraki G, Tragiannidis D, Xirou P, Nakos A, Pilpilidis I, Katsos I. Endoscopic resection of giant lipoma mimicking colonic neoplasm initially presenting with massive haemorrhage: a case report. *Cases J.* 2009 Mar 10;2:6462.
7. Ivekovic H, Rustemovic N, Brkic T, Ostojic R, Monkemuller K. Endoscopic ligation (“Loop-And-Let-Go”) is effective treatment for large colonic lipomas: a prospective validation study. *BMC Gastroenterol.* 2014 Jul 8;14(1):122.
8. Tomiki Y, Niwa K, Nagayasu K, Okazawa Y, Ito S, Ichikawa R, et al. Two Patients with Large Colonic Lipomas for which Endoscopic Unroofing was Ineffective. *Case Rep Gastroenterol.* 2016;10(3):538–44.
9. Miloudi N, Hefaiiedh R, Khalfallah MT. Giant lipoma of the transverse colon causing colo-colonic intussusceptions. *J Visc Surg.* 2012 Dec;149(6):421–2.
10. Zhou X-C, Hu K-Q, Jiang Y. A 4-cm lipoma of the transverse colon causing colonic intussusception: A case report and literature review. *Oncol Lett.* 2014 Sep 1;8(3):1090–2