

Original Article

THYROID-LIKE LOW GRADE NASOPHARYNGEAL PAPILLARY ADENOCARCINOMA IN A 20 YEAR OLD STUDENT: A CASE REPORT AND REVIEW OF LITERATURE

Ukah CO¹, Menkiti FE¹, Ofoegbu VC², Achusi Ib³¹ Histopathology Department, Nnamdi Azikiwe University Teaching Hospital, PMB 5025, Nnewi, Anambra State, Nigeria.² Otorrhinolaryngology unit, Surgery Department, St Charles Borromeo Specialist Hospital, Onitsha, Anambra State, Nigeria.³ Anatomic Pathology Department, Federal medical Centre, Abuja, Nigeria.

ABSTRACT

Low grade nasopharyngeal papillary adenocarcinoma (LGNPA) is a rare variant of nasopharyngeal adenocarcinoma with an excellent prognosis and a histo-morphologic similarity with papillary thyroid carcinoma (PTC). It can be differentiated from PTC using Thyroid Transcription Factor-1 (TTF-1) and Thyroglobulin immunostains. We report a case of thyroid-like LGNPA in a 20 year old Nigerian student.

Keywords: Papillary Adenocarcinoma, Nasopharynx, Thyroglobulin, Thyroid Transcription Factor-1.

NigerJmed 2019; 560-565
© 2019. Nigerian Journal of Medicine

INTRODUCTION

Primary nasopharyngeal adenocarcinomas (PNACs) are uncommon neoplasms with varied morphology, histogenesis and clinical biologic behavior,¹ reported to account for <0.5% of all types of Nasopharyngeal carcinomas.²⁻⁵ They are classified by their morphology and clinical behavior into 2 groups: surface epithelial origin type and salivary gland type.¹ Low grade nasopharyngeal papillary adenocarcinoma (LGNPA) is an extremely rare indolent tumour of surface epithelial origin with only a few cases reported in the literature,^{1,5,6} and characterized by an exophytic growth comprising of complex papillary and glandular structures.^{6,7} This was first reported by Wenig *et al.* in 1988,⁸ and

included in the 2005 World Health Organization (WHO) classification of nasopharyngeal cancers.⁹ Owing to anatomical limitations and poor exposure of the tumor in the nasopharynx, it is sometimes difficult to completely remove the tumor with an adequate safety margin, especially in cases of large infiltrative tumors;¹⁰ overall, it has an excellent prognosis following complete surgical resection.⁸ We report a case of this rare tumour (LGNPA) in a 20-year-old Nigerian student, with a review of the literature in order to highlight what is known to date about this rare entity.

CASE REPORT

M.E. is a 20 year old Nigerian male student who hails from Enugu State in south eastern Nigeria. He came to the Otolaryngology clinic with a 2 year history of nose bleeding that had recurred every 2 to 3 months since onset. Bleeding issued predominantly from the left nasal cavity in rapid drops and usually stops without medical intervention after about 10 to 20 minutes. He has never been admitted to hospital or received blood

Correspondence to: Dr Menkiti Felix
Histopathology Department,
Nnamdi Azikiwe University Teaching Hospital,
PMB 5025, Nnewi, Anambra State, Nigeria.
menkiti_f@yahoo.com
Tel: +2348168104151

transfusion on account of the epistaxis. About 3 weeks prior to presentation, he began to experience a rapidly worsening bilateral nasal obstruction that was worse on the left side. At the time of presentation, he was experiencing an obvious difficulty in breathing. This was associated with noisy and mouth breathing, snoring at night and episodes of obstructive sleep apnoea. There was reduction in hearing and fullness in the ears, severe intermittent deep seated headache transiently relieved by analgesics. There was no neck swelling nor were there any other rhinological or otological symptoms.

On Clinical examination, he was in respiratory distress (breathing that was stertorous with open mouth posture and hyponasal speech). Anterior rhinoscopy showed no abnormal finding. Oral cavity and Oropharyngeal examination also showed no abnormal findings. Postnasal examination showed a hemorrhagic mass in the nasopharynx with a tan surface that was mottled with clots.

Otological examination revealed a dull tympanic membrane on both sides. Both sides also had a negative Rhinne's test and a Weber's test that was central.

The plain lateral soft tissue X-ray of the nasopharynx (Figure 1) showed a lobulated soft tissue opacity in the nasopharynx that narrowed the nasopharyngeal airway.

A provisional diagnosis of Nasopharyngeal Carcinoma was made and he was worked up for Examination under Anaesthesia and Biopsy of the Nasopharynx. Intra-operative findings were that of a florid predominantly right sided friable haemorrhagic tissue in the nasopharynx. Bleeding during the curettage was minimal.

Histology of the biopsied tissue (Figures 2A

and B) revealed a malignant epithelial neoplasm composed of complex arborizing papillae with hyalinized fibrovascular cores and glandular structures. Both are lined by pseudostratified cuboidal to columnar cells with moderate nuclear pleomorphism, nuclear crowding, indistinct nucleoli, moderate cytoplasm and scant mitotic activity. Immunohistochemical staining for Thyroid Transcription Factor-1 (TTF-1) demonstrated nuclear positivity (Figures 3A and B), while Thyroglobulin (Figures 4A and B) was negative. Features were consistent with Thyroid-like Low grade Nasopharyngeal Papillary Adenocarcinoma (T-LGNPA).

The patient was discharged after one day on admission. He has done remarkably well postoperatively and has remained symptom free after 18months of regular follow up visits. No anterior neck mass has been noted and thyroid function tests has remained normal.

DISCUSSION

Ear, nose and throat cancers are the commonest cancers of the head and neck region,¹¹⁻¹⁵ with carcinomas of the nasopharynx being the second most common otorhinolaryngeal carcinoma after laryngeal carcinoma.¹¹ The most common malignancy of the nasopharynx is nasopharyngeal carcinoma.¹⁶

PNACs are a group of extremely rare tumors with a reported frequency of <0.5 of all types of carcinomas of the nasopharynx.² PNACs can be classified into two main categories having different morphological features and clinical behaviours: the conventional or mucosal surface origin type to which low Grade Nasopharyngeal papillary adenocarcinoma (LGNPA) belongs; and the salivary gland type.^{1,2,7,8,17} Primary salivary gland-type nasopharyngeal carcinoma includes

adenoid cystic carcinoma and mucoepidermoid carcinoma.^{1,18}

The case we presented here is that of LGNPA. These tumors usually arise from the roof, lateral wall, and posterior wall of the nasopharynx and present commonly with nasal obstruction and less often with epistaxis.⁵ The index case was a 20 year old male, who came with history of nasal obstruction and prior history of epistaxis, all of which features is consistent with the presentation of NPAC having a reported age range of 11-64 years (mean=36years). The tumour in the index patient was located in the posterior aspect of the nose.

A review of 25 reported cases of LGNPA by Minhua *et al.* showed a slight male preponderance, the commonest location being the posterior aspect of the nasal septum, with most presenting as a polypoid lesion and No recurrence noted after one year of follow up.¹⁹ Also, a fifteen year clinico-pathologic study of cases of PNAC by Daboin *et al.* showed 13 cases of LGNPAs, all of which show no evidence of disease following surgical excision after 5-20 years surveillance.¹ The index case has remained symptom free after 18months of follow-up. Surgical excision with adequate margin has been shown to be sufficient treatment,⁸ except cases in which anatomical location limits complete excision; adjuvant treatment is needed in such cases, however LGNPAs have low sensitivity to conventional radiotherapy or chemo-radiotherapy owing to its well differentiation, and it becomes a problem dealing with incompletely removed tumours.¹⁰

Although there is well-documented link between Epstein-Bar Virus (EBV) and tumours of the nasopharynx, this association has not been confirmed in LGNPA.¹⁹⁻²¹ The LGNPA presents a

histologic picture that is similar to papillary thyroid carcinoma (PTC), but differentiated from PTC via immunostaining for TTF-1 and thyroglobulin which are both negative for LGNPA.¹ However, a subset of the LGNPA, termed thyroid-like LGNPA, has been found to be immune-reactive to TTF-1 but not to thyroglobulin.^{1,5,7,22,23} This is true of the index case which is TTF-1 positive but Thyroglobulin negative.

CONCLUSION

LGNPA is an extremely rare tumour with a morphologic feature similar to that of PTC but with an excellent prognosis. Even much rarer is the Thyroid-like LGNPA. Surgical excision with negative margins is a choice treatment with no recorded recurrence. Awareness and proper diagnosis is important as its clinical behavior and treatment differs from the other PNACs.

LEGENDS

figure1: Plain lateral soft tissue X-ray of the nasopharynx of the patient in review showed a lobulated soft tissue opacity in the nasopharynx (arrow in figure) that narrowed the nasopharyngeal airway.

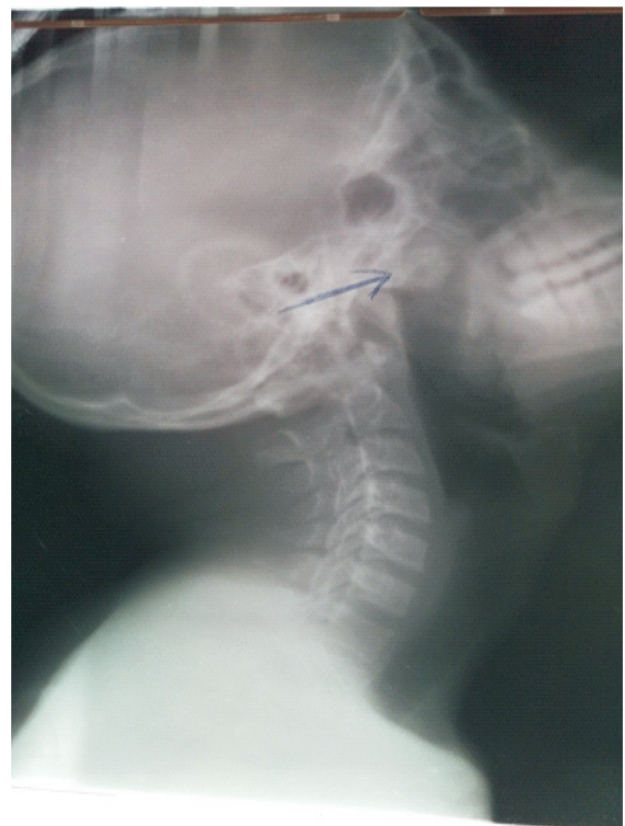
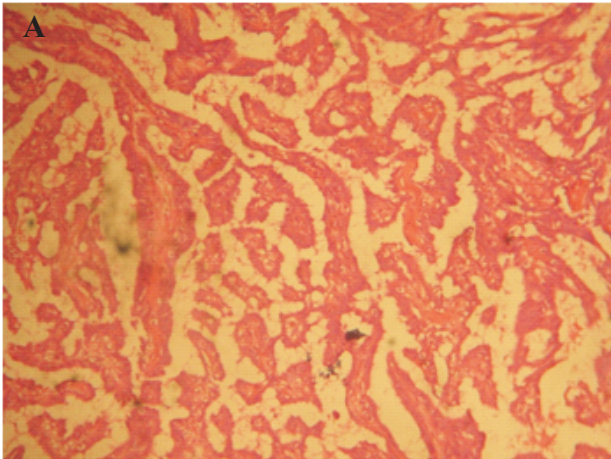


Figure 2: Haematoxylin and Eosin Photomicrographs showing complex arborizing papillae (A=X50 magnification), with nuclear pseudo-stratification, crowding and overlap (B=X400 magnification).



ThyroidTranscriptionFactor-1.

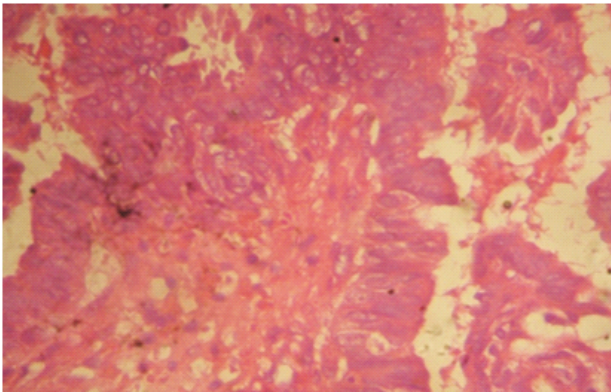


Figure 3: Sections show nuclear staining to TTF-1 immunostaining. (A=X50, B=X400 magnification)

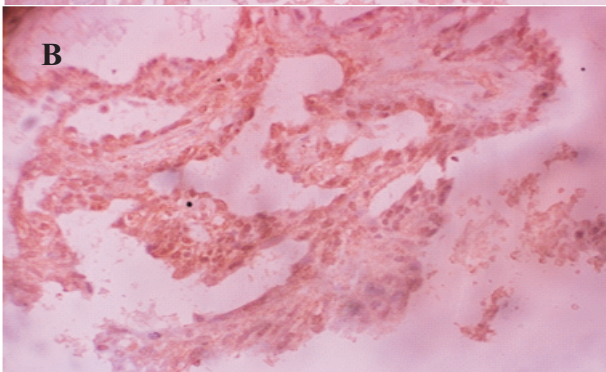
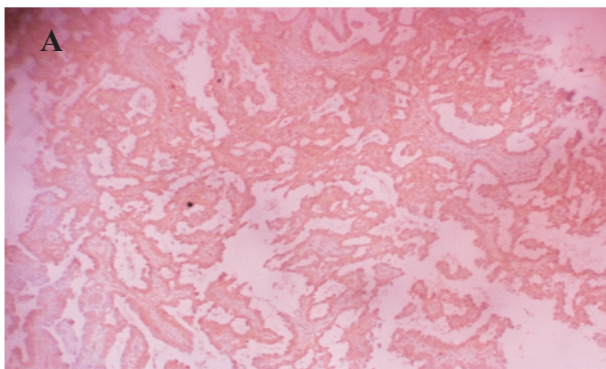
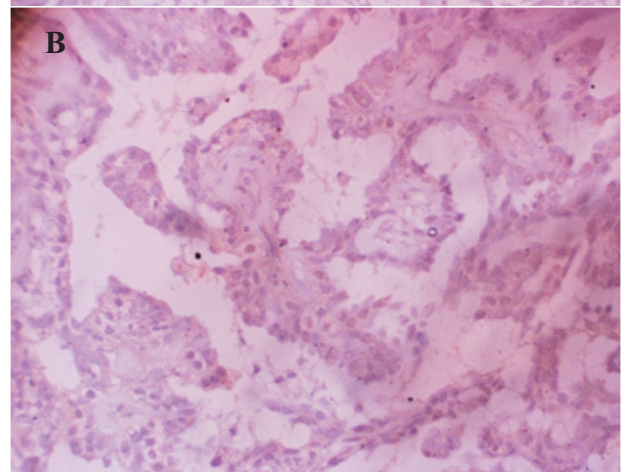
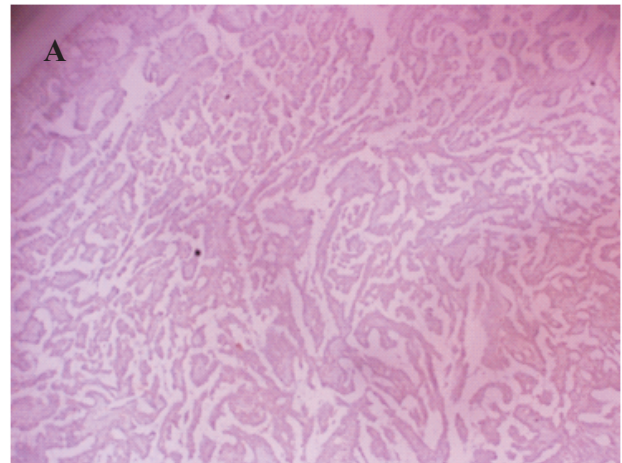


Figure 4: Sections show negativity to TTF-1 immunostaining. (A=X50, B=X400 magnification)



REFERENCES

1. Pineda-Daboïn K, Neto A, Ochoa-Perez V, Luna MA. Nasopharyngeal adenocarcinomas: A clinicopathologic study of 44 cases including immunohistochemical features of 18 papillary phenotypes. *Ann Diagn Pathol.* 2006; **10** (4): 215-21.
2. He JH, Zong YS, Luo RZ, Liang XM, Wu QL, Liang YJ. Clinicopathological characteristics of primary nasopharyngeal adenocarcinoma. *Ai Zheng.* 2003; **22**(7):753-757.
3. Guo ZM, Liu WW, He JH. A retrospective cohort study of nasopharyngeal adenocarcinoma: a rare histological type of nasopharyngeal cancer. *Clin Otolaryngol.* 2009; **34** (4):322-327.

4. Tang Q, Hu QY, Piao YF, Hua YH, Fu AF. Clinical analysis of twenty-three nasopharyngeal adenocarcinoma patients. *Chin J Cancer Prev Treat.* 2009;**14**(21):1669-1672.
5. Rajeswari B, Sukumaran Nair RK, Parukuttyamma K, Mathews A. Low-grade papillary adenocarcinoma of nasopharynx with expression of thyroid transcription factor-1: Case report and review of literature. *Indian J Pathol Microbiol.* 2016;**59**:518-20
6. Kuo TT, Chan JKC, Wenig BM, Eveson JW. Nasopharyngeal papillary adenocarcinoma and salivary gland-type carcinomas. In: Barnes L, Eveson JW, Reichart P, Sidransky D, editors. *WHO classification of Tumours. Pathology and Genetics of Head and Neck tumours.* Lyon: IARC press; 2005. p. 98.
7. Ohe C, Sakaida N, Tadokoro C, et al. Thyroid-like low-grade nasopharyngeal papillary adenocarcinoma: report of two cases. *Pathol Int.* 2010;**60**(2):107-111
8. Wenig BM, Hyams VJ, Heffner DK. Nasopharyngeal papillary adenocarcinoma: a clinicopathologic study of a low-grade carcinoma. *Am J Surg Pathol.* 1988;**12**:946-53.
9. Thompson L. World Health Organization classification of tumours: pathology and genetics of head and neck tumours. *Ear Nose Throat J.* 2006;**85**:74.
10. Xiaoli Wang, Hongjiang Yan, Yijun Luo, Tingyong Fan. Low-grade nasopharyngeal papillary adenocarcinoma: a case report and review of the literature. *OncoTargets and Therapy.* 2016;**9**:2955-2959
11. Forae GD, Nwafor CC. Pattern of occurrence of primary head and neck cancers presenting in Benin City, Southern Nigeria. *Saudi J Health Sci.* 2017;**6**:52-6
12. da Lilly-Tariah OB, Somefun AO, Adeyemo WL. Current evidence on the burden of head and neck cancers in Nigeria. *Head Neck Oncol.* 2009;**1**:14.
13. Lasrado S, Prabhu P, Kakria A, Kanchan T, Pant S, Sathian B, et al. Clinicopathological profile of head and neck cancers in the Western development region, Nepal: A 4-year snapshot. *Asian Pac J Cancer Prev.* 2012;**13**:6059-62.
14. Onyango JF, Awange DO, Njiru A, Macharia IM. Pattern of occurrence of head and neck cancer presenting at Kenyatta National Hospital, Nairobi. *East Afr Med J.* 2006;**83**:288-91.
15. Adisa AO, Adeyemi BF, Oluwasola AO, Kolude B, Akang EE, Lawoyin JO. Clinico-pathological profile of head and neck malignancies at University College Hospital, Ibadan, Nigeria. *Head Face Med.* 2011;**7**:9.
16. Lester D. R. Thompson. **Nasopharyngeal papillary adenocarcinoma.** *Ear Nose Throat J.* 2017 December;**96**(12):456-457.)
17. Kuo T, Tsang NM. Salivary gland type nasopharyngeal carcinoma: a histologic, immunohistochemical, and Epstein-Barr virus study of 15 cases including a psammomatous mucoepidermoid carcinoma. *Am J Surg Pathol.* 2001;**25**(1):80-86.
18. Xu T, Li ZM, Gu MF, et al. Primary nasopharyngeal adenocarcinoma: a review. *Asia Pac J Clin Oncol.* 2012;**8**(2):123-131.
19. Minhua Li, Jiangguo Wei, Xiaofee Yao, Cheng Wang. **Clinicopathological Features of Low-Grade Thyroid-like Nasopharyngeal Papillary Adenocarcinoma.** *Cancer Res Treat.* 2017 Jan;**49**(1): 213-218.

20. Wu PY, Huang CC, Chen HK, Chien CY. Adult thyroid-like low-grade nasopharyngeal papillary adenocarcinoma with thyroid transcription factor-1 expression. *Otolaryngol Head Neck Surg.* 2007;**137**:837-8.
21. Fu CH, Chang KP, Ueng SH, Wu CC, Hao SP. Primary thyroid-like papillary adenocarcinoma of the nasopharynx. *Auris Nasus Larynx.* 2008;**35**:579-82.
22. Carrizo F, Luna MA. Thyroid transcription factor-1 expression in thyroid-like nasopharyngeal papillary adenocarcinoma: Report of 2 cases. *Ann Diagn Pathol.* 2005;**9**:189-92.
23. Appukutty SJ, Di Palma S, Pitkin L, Smith CE. Thyroid-like low grade nasopharyngeal papillary adenocarcinoma presenting as snoring in a 49-year-old male. *Diagn Histopathol.* 2013;**9**:350-3.24