

PREVALENCE, PATTERN AND RISK FACTORS FOR RETINAL VASCULAR OCCLUSIONS IN A TERTIARY HOSPITAL IN JOS, NIGERIA

Olukorede O. Adenuga, Alice V. Ramyil, Ojo P. Odugbo, Funmilayo J. Oyediji

Department of Ophthalmology, Jos University Teaching Hospital, Jos, Plateau State, Nigeria.

ABSTRACT

INTRODUCTION

Retinal vascular occlusions are the second most common retinal vascular diseases following diabetic retinopathy. They are associated with several systemic and ocular pathologies and are significant causes of visual loss.

OBJECTIVE

This study aims to determine the prevalence, pattern and risk factors for retinal vascular occlusions in a tertiary hospital in Jos, Nigeria.

METHODOLOGY

A retrospective review of all cases of retinal vascular occlusions seen in the eye clinic from January 2011 to December 2014 was carried out. The patients were identified from the clinic register and their case folders retrieved. The following data were then extracted from the files: patients' age, sex, presenting visual acuity, presence of any systemic disorders and type of retinal vascular occlusion. Data analysis was done using Epi Info 7.

RESULTS

Three thousand eight hundred and twenty one new patients were seen during the study period and there were 52 (1.36%) cases of retinal vascular occlusions. Only the case files of 44 (84.6%) patients were available and were analysed. These were made up of 17 (39%) males and 27 (61%) females. These had a total of 46 retinal vascular occlusions made up of 37 (80.4%) retinal vein occlusions, 8 (17.4%) central retinal artery occlusions and a case (2.2%) of combined central retinal artery and vein occlusion. Hypertension and diabetes were the most common systemic risk factors while glaucoma was the most common ocular association.

CONCLUSION

Retinal vascular occlusions are uncommon in our centre but lead to severe visual loss and are associated with significant systemic pathologies.

KEYWORDS: Retinal vein occlusion, retinal artery occlusion

NigerJMed2015: 331-336

Copyright © 2015. Nigeria Journal of Medicine

INTRODUCTION

Retinal vascular occlusions are serious diseases and significant causes of blindness that include venous and arterial obstructions.¹ They are the second most common retinal vascular diseases following diabetic retinopathy.² Retinal vein occlusion (RVO) manifests at a mean age of 65 years and is more common in men than women with prevalence in population based studies ranging from 5.2 to 16 per 1000.^{2,3} There are three types of RVO: (1) Branch Retinal Vein Occlusion (BRVO) which is divided further into major BRVO and macular BRVO; (2) Central Retinal Vein Occlusion (CRVO) which can either be ischemic or nonischemic; and (3) Hemicentral Retinal Vein

Occlusion (HRVO) which involves only one half of the retina surface and like CRVO is divided into ischemic and nonischemic types.⁴ Central retinal vein occlusion blocks all venous outflow, whereas BRVO may be occlusion of a first-order (hemispheric or quadrant) or second-order (macular or twig) tributary. Hemicentral retinal vein occlusion involves blockage of one of two central retinal vein trunks within the optic nerve head, an anatomical variation found in only 20 per cent of the population.⁵ Branch retinal vein occlusion is four to six times more common than CRVO while HRVO is the least common.^{5,6}

Retinal vein occlusion is associated with a number of systemic and ocular risk factors. The systemic risk factors include hypertension, diabetes mellitus, hyperlipidaemia, systemic vasculitis (sarcoidosis, syphilis), haematologic neoplasia (polycythemia rubra vera, leukemia), hypercoagulable states such as protein

Corresponding Author: Olukorede O. Adenuga
Department of Ophthalmology, Jos University Teaching Hospital,
Jos, Plateau State.
Phone: +2348034515042
Email: korexmed@yahoo.com

S deficiency and antiphospholipid syndrome, drug therapy (oral contraceptives, diuretics, and hypotensive drugs) and atherosclerotic associated diseases (ischemic heart disease, obesity, and cigarette smoking).³ Ocular risk factors include glaucoma, decreased ocular perfusion pressure and external globe compression from orbital neoplasms and endocrine orbitopathy.³

Retinal artery occlusion (RAO) represents an ophthalmologic emergency as delay in treatment may result in permanent loss of vision.¹ According to the involved vessels, RAO can be subdivided into several forms, including: Central Retinal Artery Occlusion (CRAO), Branch Retinal Artery Occlusion (BRAO), cilioretinal artery occlusion, CRAO sparing cilioretinal artery, ophthalmic artery occlusion and CRAO associated with CRVO.⁷ The two main forms however are CRAO and BRAO.⁷ Central retinal artery occlusions account for 58% of acute RAOs and BRAOs for 38%.¹ The combined incidence of CRAO and BRAO lies between 0.5 and 1.5 per 1000 initial ophthalmic outpatient visits.⁸ The mean age of patients with CRAO and BRAO is 62 years and 58 years respectively.² Retinal artery occlusions are most often caused by emboli and the most common risk factors are arterial hypertension, diabetes mellitus, valvular diseases of the heart, and carotid artery stenosis or plaques.²

The department commenced treatment for retinal diseases in May 2011 following the installation of a diode laser machine in the eye clinic and in July 2013 started administering intravitreal bevacizumab (Avastin) injections. Retinal vascular occlusions have been observed as a common indication for both procedures. We therefore sought to determine the prevalence and pattern of retinal vascular occlusions seen in our eye clinic as well as the associated risk factors over a 4 year period from January 2011 to December 2014.

METHODOLOGY

A retrospective study of retinal vascular occlusions seen in the eye clinic over a period of 4 years from January 2011 to December 2014 was carried out. The number of new patients seen during this period was determined from the eye clinic register and all the cases of retinal vascular occlusions identified and their case files retrieved. The following data were then extracted from the files; patients' age, sex, presenting visual acuity (VA), presence of any systemic disorders, type of retinal vascular occlusion and duration of follow up. Ocular co-morbidities and complications of vascular occlusion such as macular oedema, ocular Neovascularization (NV) and Neovascular Glaucoma (NVG) were all recorded. Fundus photographs were

taken in some of the patients when a fundus camera (Opto angiocam ADS 1.3 FA by Opto Electronica S/A, Sao Paulo, Brazil) was installed in the clinic. However, none of the patients had Fundus Fluorescein Angiography (FFA) or Optical Coherence Tomography (OCT) as the facilities for these were not available in the clinic during the study period. Where a patient had a bilateral vascular occlusion or 2 separate occlusions in the same eye, they were recorded as separate events. Any complication in an eye with more than one vascular occlusion occurring at different times was however recorded once. Results of blood investigations such as full blood count and erythrocyte sedimentation rate, electrolytes and urea, serum lipid profile were also evaluated and any derangement recorded. All eyes with retinal vascular occlusions, including both acute and old cases were included in the study. Data analysis was done using Epi Info 7.1.5.0. Mean values were compared by Student's t-test and frequencies by the χ^2 test. A p value of less than 0.05 was considered statistically significant. Ethical clearance for the study was obtained from the Ethics Committee of the hospital.

RESULTS

Three thousand eight hundred and twenty one new patients were seen during the study period and 52 (1.36%) of these had retinal vascular occlusion. These comprised of 43 RVOs (82.6%), 8 RAOs (15.4%) and 1 case of CRAO with an impending CRVO (2%). Of these, only the case files of 44 (85%) patients were available and were analysed. These were made up of 17 (39%) males and 27 (61%) females giving a male:female ratio of 1:1.6. These had a total of 46 retinal vascular occlusions with one patient having bilateral disease and another having two separate venous occlusions in the same eye. These were recorded as separate events. These 46 cases were made up of 37 RVOs (80.4%), 8 RAOs (17.4%) and 1 case of CRAO with an impending CRVO (2.2%). The RVOs comprised of 22 (47.8%) CRVOs, 11 (24%) HRVOs and 4 (8.7%) BRVOs. All the RAOs involved the central retinal artery and one patient had bilateral involvement. Figure 1 shows the sex distribution of the various retinal vascular occlusions. The age range of the patients was 20-85 years with a mean of 53.5 years (SD \pm 16.5). The mean age for patients with RVO was 57 years and for patients with RAO 38 years. This difference was statistically significant with a p value of 0. Two (25%) of the patients with CRAO were 50 years and above while 25 (68%) of the patients with RVO were 50 years and above (Table 1). This difference was statistically significant ($\chi^2=4.96$, p value = 0.03).

Presenting VA ranged from no light perception to 6/18. It was less than 3/60 in 31 (54%) eyes and less than 6/60 in 35 (76%) eyes (Table 2). Seventeen (46%) of the 37 eyes

with RVO and 7 (88%) eyes with RAO had a VA of less than 3/60. This difference was not statistically significant ($\chi^2=0.38$, p value = 0.53)

The most common systemic association identified was hypertension followed by diabetes mellitus (Table 3). Hypertension was associated with 29 (78%) eyes with RVO and 3 (38%) eyes with RAO. This difference was statistically significant ($\chi^2=5.35$ p value = 0.02). Diabetes mellitus was associated with 10 (27%) eyes with RVO and 1 (13%) eye with RAO. This difference was not statistically significant ($\chi^2 = 0.73$, p value = 0.39). Other systemic disorders identified were 1 case each of alcoholic cardiomyopathy, sickle cell disease, thrombocytosis, hyperlipidaemia and Human Immunodeficiency Virus (HIV) infection. The patient with HIV had bilateral CRAO. Glaucoma occurred in 8 (22%) eyes with RVO and in 1 (13%) eye with RAO. This difference was not statistically significant ($\chi^2 = 0.5$, p value = 0.47). The only other ocular association was a case of papillitis diagnosed in an eye with CRAO. Twenty two (48%) eyes were associated with more than one risk factor.

Ocular complications were documented in 32 (70%) eyes (Figure 2). These comprised of ocular NV; 13 (28%), macular oedema; 12 (26%), NVG; 7 (15%) and vitreous haemorrhage; 1 (2%). Ocular NV was seen in 12 (32%) cases of RVO and one (13%) case of CRAO. This difference was statistically significant ($\chi^2=4.22$, p value = 0.03). These cases of RVO with NV comprised of 4 HRVOs (1 iris NV, 3 retinal NVs) and 8 CRVOs (5 iris NVs, 3 retinal NVs). Macular oedema was seen in 8 (22%) eyes with RVO and 3 (38%) eyes with CRAO. This difference was not statistically significant ($\chi^2 = 0.9$, p value = 0.34). Neovascular glaucoma was seen in 7 (15%) eyes; 6 RVOs and 1 CRAO. This difference was also not statistically significant ($\chi^2 = 0.06$, p value = 0.8). The only eye with HRVO that developed NVG had features of an old superior HRVO and an acute inferior HRVO at presentation.

DISCUSSION

Retinal vascular occlusions are uncommon in our centre accounting for less than 2% of all new patients seen during the study period. The prevalence of RVO in this study lies between 0.6% and 2.1% obtained in population based studies in America and Asia.⁹⁻¹¹ A female preponderance was observed in this study. For patients with RVO this is in consonance with reports from other tertiary institutions in Nigeria.^{12,13} Other studies on RVO however observed no significant gender difference or a male preponderance.^{9,10,14}¹⁶ Studies on RAO reported a gender difference with male predominance.^{17,18}

Central retinal vein occlusion was the commonest type

of RVO seen in this study and this compares with other studies in Nigeria.^{12,13} Studies done in Asia and America however reported BRVO as the commonest type of RVO seen.^{9-11,15} This difference may be as a result of study design and ethnic differences. Also, CRVO results in more profound visual loss^{12,15} and this may make it more likely for patients with this condition to seek medical care in the hospital. Retinal artery occlusion is a rare event with studies in America and Croatia estimating an annual incidence of 1.90 and 0.70 per 100,000 respectively.^{17,19} All the cases of RAO in this series were occlusions of the central retinal artery. A study on RAO in the young by Ratra and Dhupper also reported CRAO as the most common type of RAO seen followed by BRAO.²⁰ In contrast however, Greven et al²¹ reported BRAO as the most common type of RAO seen in a study conducted in patients less than 40 years of age.

Retinal vascular occlusive disease is associated with advancing age and significant systemic and ophthalmic pathologies.^{9,17} The mean age of patients with RVO in this study compares favourably with 54 years and 58 years reported by other authors in Nigeria^{12,13} but is lower than findings in other studies done in Asia where mean ages of over 60 years were reported.^{11,14} For patients with CRAO however, the mean age obtained in this study contrasts sharply with the mean of 74 yrs and 66 yrs obtained in America and Europe respectively.^{17,19} Racial differences as well as the relatively smaller number of cases in this series may explain this age differences.

Systemic diseases such as hypertension, hyperlipidaemia and diabetes are associated with the development of both RVO and RAO.^{17, 22} Hypertension was the major systemic association in this study. This is consistent with findings from previous studies.¹²⁻¹⁷ Hypertension in blacks tends to be more severe and develops at an earlier age. The overall mortality due to hypertension and its consequences is also more likely in blacks.²³ This may explain the lower mean age of patients with RVO in this series. Hypertension and diabetes, the major risk factors in this study are associated with an increased risk of systemic arteriosclerosis, which is generally considered the main pathophysiological component of developing RVO.³

Central retinal artery occlusion is mostly due to atherosclerosis related thrombosis at the level of the lamina cribrosa.²⁴ The incidence of atherosclerosis increases with age and is also accelerated by hypertension, diabetes, hyperlipidaemia, oral contraceptives, and hyperhomocysteinaemia.²⁴ The proportion of patients with CRAO that had

hypertension and diabetes in our series is lower than what was reported by Leavitt et al.¹⁷ Hypertension and diabetes are diseases of the older population and the mean age of patients with RAO in this study was 38 years.

Glaucoma was the major ocular risk factor for vascular occlusion in this series. Studies have shown a significant association between RVO and glaucoma.^{15,25} Twenty two percent of eyes with RVO in this series had associated glaucoma. This correlates with 22.2% reported by Nwosu¹³ but contrasts with 33.3% and 9.9% reported by Feibai et al¹² and Hayreh et al²⁶ respectively.

The commonest ocular complication seen in this study was ocular NV. This is at variance with reports by Feibai et al¹² and Prajapati et al¹⁶ which reported vitreous haemorrhage and macular oedema respectively as the most common complication in their series. These differences could be as a result of variations in time intervals from the acute event to presentation in the hospital as well as duration of follow-up. In RVO, ocular NV is a complication of ischemic CRVO/HRVO and major BRVO only. It does not occur in non-ischemic CRVO/HRVO or macular BRVO.²⁶ This implies that the cases with this complication in this series were most likely the ischaemic types of RVO even though this was not confirmed by FFA. A study by Hayreh and Zimmerman²⁷ showed that in ischemic CRVO, anterior segment NV is much more common than posterior segment NV while the reverse is the case with HRVO. This correlates with our finding in this series. The only eye with HRVO that developed anterior segment NV had occlusions of the superior and inferior hemiretinal vein occurring on separate occasions. The proportion of eyes with RVO that developed NVG in our study is slightly lower than 20% reported by Prajapati et al.¹⁶ For the cases of CRAO the prevalence of ocular NV and NVG was 13% respectively. This is comparable to findings in other studies that reported a prevalence of 18% for iris NV

following CRAO and 15% to 18% for associated NVG.²⁸⁻³⁰

Retinal vein occlusion is a very elegant example of a red (haemorrhagic) infarct, whereas RAO typifies a white (ischaemic) infarct.³¹ Regardless of mechanism, unresolved infarction results in tissue death and tissue death leads to visual loss.⁵ Majority of the patients in this series presented with poor vision with VA of less than 6/60. For the RVOs, most of those with poor visual acuities were eyes with CRVO. This is in keeping with findings from other studies.^{12,15,16} Acute CRAO presents with a sudden, painless and profound drop in vision, usually with an initial Snellen acuity of counting fingers or worse, unless a cilioretinal artery is present in which case central vision may be preserved.^{8,32} Only one eye with CRAO in this study had a VA greater than 6/60. This eye may have had a cilioretinal artery sparing not documented at the time the patient was seen. In a study by Hayreh and Zimmerman³³ on the visual outcome in CRAO, 80% of the patients had profound visual loss with VA less than 3/60. This agrees with 87.5% obtained in this study.

The limitations of this study include its retrospective design and the relatively small number of cases reviewed. Also FFA as well as OCT were not available during the study period. FFA would have been valuable in differentiating ischaemic from non-ischaemic RVO while OCT would have been helpful in evaluating the macular for the presence or absence of oedema.

In conclusion our results indicate that retinal vascular occlusions are uncommon in our centre, result in severe visual loss and are most commonly associated with hypertension and diabetes mellitus. A comprehensive management of patients with retinal vascular occlusions is therefore necessary to correct associated diseases or predisposing risk factors that could lead to local recurrences. Early diagnosis and treatment of these associated systemic disorders in the general population will also help in reducing the incidence of these conditions and resultant blindness.

TABLES AND FIGURES

Figure 1; Sex Distribution

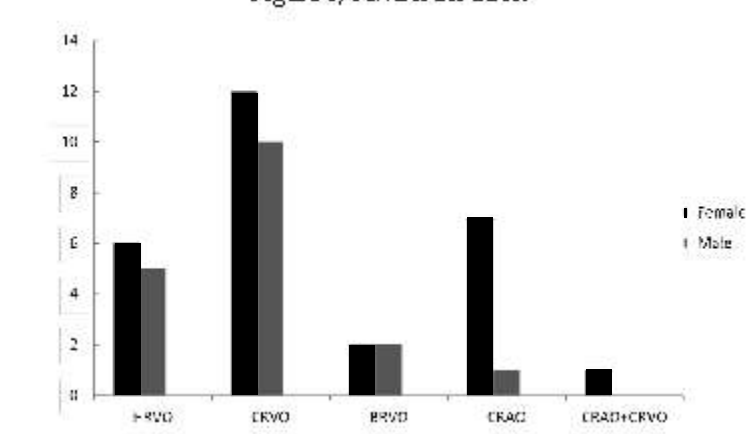


Table 1; Age Specific Prevalence of Retinal Vascular Occlusions

Age (yrs)	CRVO n(%)	BRVO n(%)	HRVO n(%)	CRAO n(%)	CRAO+CRVO n(%)	Total n(%)
20-29	-	1(25)1(9.1)	1(12.5)	-	3(6.5)	-
30-39 1(5)	-	-	4 (50)	-	5 (11)	-
40-49	-	5(23)	-	4(36.4)1(12.5)1(100)	-	11(24)
50-59	-	4(18)	1(25)	3(27.3)1(12.5)	-	9(19.5)
60-69	-	6(27)	1(25)3(27.3)	-	1(12.5)-	11(24)
70-79	2(9)	-	-	-	-	2(4.4)
80-89	-	4(18)	1(25)	-	-	5(11)
Total	22(100)	4(100)	11(100)8(100)	1(100)	1(100)	46(100)

CRVO: Central Retinal Vein Occlusion, BRVO: Branch Retinal Vein Occlusion, HRVO: Hemiretinal Vein Occlusion, CRAO; Central Retinal Artery Occlusion

Table 2; Presenting Visual Acuity

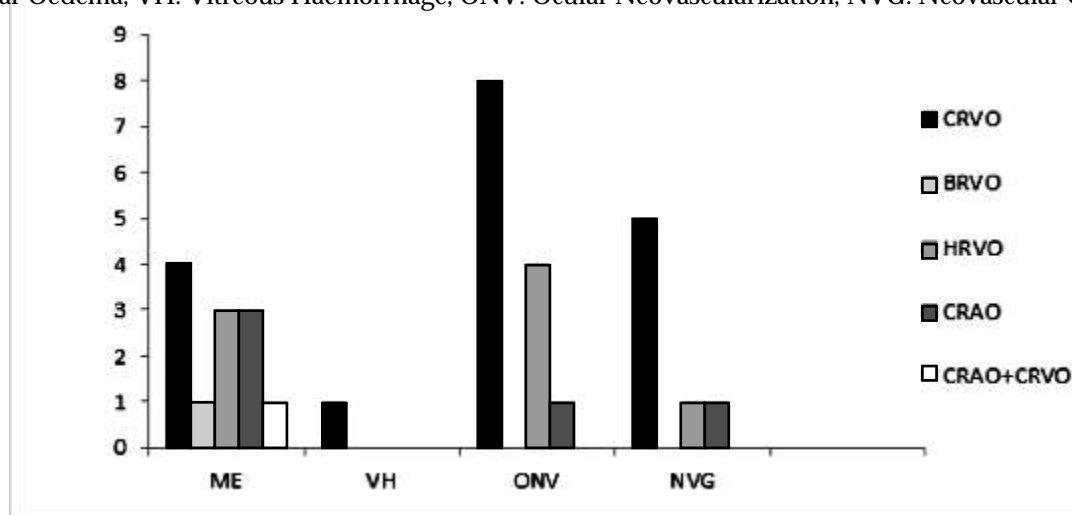
VA	CRVO n(%)	BRVO n(%)	HRVO n(%)	CRAO n(%)	CRAO+CRVO n(%)	Total n(%)
<3/60	14 (63.6)	-	3(27.3)	7(87.5)	1(100)	25 (54)
3/60 -<6/60	3 (13.6)	3 (75)	4(36.4)	-	-	10 (22)
6/60-<6/18	4 (18.2)	1 (25)	2 (18.2)	1 (12.5)	-	8 (17)
6/18	1 (4.5)	-	2 (18.2)	-	- 3 (7)	-
Total	22 (100)	4 (100)	11 (100)	8 (100)	1 (100)	46(100)

Table 3; Systemic and ocular associations

Type of VO n(%)	HT n(%)	DM n(%)	HIV n(%)	SCD n(%)	Glaucoma n(%)	Others
CRVO	17(53)	4(36.4)	-	-	3(33.3)	-
BRVO	4(13)	2(18.2)	-	-	3(33.3)	-
HRVO	8(25)	4(36.4)	-	-	2(22.2)	-
CRAO	3(9)	1(9)	2 (100)	-1(11.1)	6(100)	-
CRAO+CRVO	-	-	-	1(100)	-	-
Total	32 (100)	11(100)	2(100)	1(100)	9(100)	6(100)

VO: Vascular Occlusion, HT: Hypertension, DM: Diabetes Mellitus, HIV: Human Immunodeficiency Virus, SCD: Sickle Cell Disease

ME: Macular Oedema, VH: Vitreous Haemorrhage, ONV: Ocular Neovascularization, NVG: Neovascular Glaucoma



REFERENCES

1. Bradvica M, Benasik T, Vinkovic M. Retinal vascular occlusions. In: Rumeldt S (ed) *Advances in ophthalmology*. Rijeka: InTech; 2012. p 357-98. <http://www.intechopen.com/books/advances-in-ophthalmology/retinal-vascular-occlusions>. (accessed 15 March 2015).
2. Lang GE, Spraul CW. Risk factors for retinal occlusive diseases. *Klin Monbl Augenheilkd* 1997;211:217-26.
3. Kolar P. Risk factors for central and branch retinal vein occlusion: a meta-analysis of published clinical data. *J Ophthalmol* 2014; 724780: 5 pages. <http://dx.doi.org/10.1155/2014/724780>. (accessed 15 march 2015)
4. Hayreh SS, Zimmerman MB, Podhajsky P. Incidence of various types of retinal vein occlusion and their recurrence and demographic characteristics. *Am J Ophthalmol* 1994;117:429-41.
5. MacDonald D. The ABCs of RVO: a review of retinal venous occlusion. *Clin Exp Optom* 2013;1-13.
6. McAllister IL. Central retinal vein occlusion: a review. *Clin Experiment Ophthalmol* 2012; 40:48-58.
7. Bandello F, Parodi MB. Retinal Artery Occlusion. In: Bandello F, Querques G (eds). *Medical Retina*. Basel: Karger; 2012. P.74-80. (ESASO course series vol 1).

8. Beatty S, Au Eong KG. Acute occlusion of the retinal arteries: current concepts and recent advances in diagnosis and management. *J Accid Emerg Med* 2000;17:324-9.
9. Klein R, Klein BEK, Moss SE, Meuer SM. The epidemiology of retinal vein occlusion: the Beaver Dam eye study. *Tr Am Ophth Soc* 2000;98:133-43.
10. Lim LL, Cheung N, Wang JJ, Islam FM, Mitchell P, Saw SM et al. Prevalence and risk factors of retinal vein occlusion in an Asian population. *Br J Ophthalmol* 2008;92:1316-9.
11. Yasuda M, Kiyohara Y, Arakawa S, Hata Y, Yonemoto K, Doi Y et al. Prevalence and systemic risk factors for retinal vein occlusion in a general Japanese population: the Hisayama study. *Invest Ophthalmol Vis Sci* 2010;51:3205-9.
12. Fiebai B, Ejimadu CS, Komolafe RD. Incidence and risk factors for retinal vein occlusion at the University of Port Harcourt Teaching Hospital, Port Harcourt, Nigeria. *Niger J Clin Pract* 2014;17:462-6.
13. Nwosu SNN. Pattern and risk factors for retinal vein occlusion in Onitsha, Nigeria. *Nig J Ophthalmol* 2008;16:30-32.
14. Thapa R, Paudyal G, Bernstein PS. Demographic characteristics, patterns and risk factors for retinal vein occlusion in Nepal: a hospital-based case-control study. *Clin Experiment Ophthalmol* 2010;38:583-90.
15. Mitchell P, Smith W, Chang A. Prevalence and associations of retinal vein occlusion in Australia. The Blue Mountains Eye Study. *Arch Ophthalmol* 1996;114:1243-7.
16. Prajapati VA, Vasvada D, Patel SM, Chaunhan W, Prajapati V. A study of evaluation of various risk factors of retinal vein occlusion. *Int J Res Med Sci* 2014;2:1054-7.
17. Leavitt JA, Larson TA, Hodge DO, Gullerud RE. The incidence of central retinal artery occlusion in Olmsted County, Minnesota. *Am J Ophthalmol* 2011;152:820-3.
18. Park SJ, Choi NK, Seo KH, Park KH, Woo SJ. Nationwide incidence of clinically diagnosed central retinal artery occlusion in Korea, 2008 to 2011. *Ophthalmology* 2014;121:1933-8.
19. Ivanišević M, Karelović D. The incidence of central retinal artery occlusion in the District of Split, Croatia. *Ophthalmologica* 2001;215:245-6.
20. Ratra D, Dhupper M. Retinal arterial occlusions in the young: systemic associations in Indian population. *Indian J Ophthalmol* 2012;60:95-100.
21. Greven CM, Slusher MM, Weaver RG. Retinal arterial occlusions in young adults. *Am J Ophthalmol* 1995;120:776-83.
22. Mohamed Q, McIntosh RL, Saw SM, Wong TY. Interventions for central retinal vein occlusion. An evidence-based systematic review. *Ophthalmology* 2007;114:507-19.
23. Ferdinand KC, Armani AM. The management of hypertension in African Americans. *Crit Pathw Cardiol* 2007;6:67-71.
24. Kanski JJ, Bowling B. *Clinical ophthalmology: a systemic approach*. 7th ed. Edinburgh:Elsevier; 2011.
25. Hayreh SS, Zimmerman MB, Beri M, Podhajsky P. Intraocular pressure abnormalities associated with central and hemicentral retinal vein occlusion. *Ophthalmology* 2004;111:133-41.
26. Hayreh SS, Rojas P, Podhajsky P, Montague P, Woolson RF. Ocular neovascularization with retinal vascular occlusion-III. Incidence of ocular neovascularization with retinal vein occlusion. *Ophthalmology* 1983;90:488-506.
27. Hayreh SS, Zimmerman MB. Ocular neovascularization associated with central and hemicentral retinal vein occlusion. *Retina* 2012;32:1553-65.
28. Rudkin AK, Lee AW, Chen CS. Ocular neovascularization following central retinal artery occlusion: prevalence and timing of onset. *Eur J Ophthalmol* 2011;20:1042-6.
29. Schäfer S, Lang GE. Iris neovascularization as a complication of central artery occlusion. *Klin Monbl Augenheilkd* 2005;222:343-5.
30. Duker JS, Sivalingam A, Brown GC, Reber R. A prospective study of acute central retinal artery obstruction. The incidence of secondary ocular neovascularization. *Arch Ophthalmol* 1991;109:339-42.
31. Hayreh SS, Zimmerman MB. Fundus changes in central retinal artery occlusion. *Retina* 2007;27:276-89.
32. Augsburger JJ, Magargal LE. Visual prognosis following treatment of acute central retinal artery obstruction. *Br J Ophthalmol* 1980;64:913-17.
33. Hayreh SS, Zimmerman MB. Central retinal artery occlusion: visual outcome. *Am J Ophthalmol* 2005;140:376-91.