

## FOREIGN BODY IN SCROTUM FOLLOWING A BOAT ENGINE BLAST ACCIDENT

S. D. MANTE<sup>1</sup>, E. D. YEBOAH<sup>2</sup>, B. ADUSEI<sup>1</sup> and S. EDUSA<sup>1</sup>

<sup>1</sup>Urology Unit, 37 Military Hospital, P.O. Box KB 282, Korle-Bu, Accra, Ghana, <sup>2</sup>Department of Surgery, University of Ghana Medical School, PO Box 4236 Accra, Ghana,

*Corresponding Author: Dr. Sunny Doodu Mante*

*Email: sunnymante44@yahoo.com*

*Conflict of interest: None declared*

### SUMMARY

Male genital injuries, demand prompt management to prevent long-term sexual and psychological damage. Injuries to the scrotum and contents may produce impaired fertility. We report our experience in diagnosing and managing a case of a foreign body in the scrotum following a boat engine blast accident. This case report highlights the need for a good history and thorough general examination to establish the mechanism of injury in order to distinguish between an embedded penetrating projectile injury and an injury with an exit wound. Prompt surgical exploration with hematoma evacuation limits complications.

**Keywords:** Blast Injury, Scrotal Haematoma, Ischaemia, Laceration, Penetrating injury

### INTRODUCTION

While the exposed and dependant nature of the scrotum makes it vulnerable to traumatic injury, the relative mobility of the scrotum often serves to protect it from serious injury. The testicles are further protected by the tough surrounding tunica albuginea and by the cremasteric reflex.<sup>1</sup> Up to 85% of testicular injuries are a result of blunt trauma<sup>2,3</sup> and most of these injuries are sustained during athletic activity. Blunt trauma may cause local haematoma, ecchymosis of the scrotum, or injuries to the testicle, epididymis or spermatic cord. In testicular rupture the tunica albuginea is disrupted, while in intratesticular haematoma the tunica albuginea remains intact.

Haematocoeles, in which blood accumulates in the space between the tunica albuginea and tunica vaginalis, and hydroceles, can be the result of trauma. Traumatically induced testicular torsion is another well recognised entity.<sup>4</sup> Penetrating injuries to the scrotum can be the result of knife wounds, gunshot or other missile wounds. Scrotal injuries include lacerations, haematomas and delayed blast type injuries. All of the scrotal contents can be injured from projectile trauma. In wartime, blast injuries to the scrotum may be more common. Bite injuries from both animals and humans

can involve the scrotum and, less frequently, the scrotal contents.<sup>5</sup>

### CASE REPORT

A 56-year-old man was working on a faulty engine of a boat at sea when it exploded resulting in multiple injuries. The patient was rushed to the trauma and surgical emergency of the 37 Military Hospital for further care. Patient complained of a headache but had no neck pain, dizziness or palpitations. He did not have any significant past medical history or drug history but did admit to being a habitual smoker and drinker.

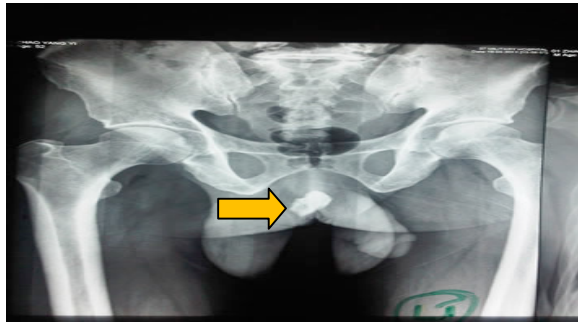
On examination the patient had soot and oil all over his body, was in pain but was not pale and was well hydrated. The patient had multiple superficial lacerations all over his body. His cardiopulmonary system was stable with a pulse rate of 70 beats/min, blood pressure of 120/80mmHg and a respiratory rate of 24 cycles/min. The patient had mild right sided chest compression tenderness. Abdominal findings were unremarkable and examination of his central nervous system was essentially normal. The patient sustained a 3cm x 2cm superficial laceration on his upper eyelid.

A close examination of the patient's trousers and underpants revealed a tear which when superimposed was consistent with the location of the laceration on his scrotum. The scrotal laceration was on the right side of the scrotum and was about 4cm x 3cm. A clot was seen at the site of the laceration and the right side of the scrotum was tender and enlarged with a darkened colour.

The history of a blast and a general examination of the tear in his trousers and pants tallying with the site of the laceration on his scrotum was consistent with a penetrating projectile trauma and the further lack of an exit wound raised our level of suspicion of there being a foreign body embedded in his scrotum. A clinical impression of a penetrating right scrotal injury by a foreign body which most likely was embedded in the-

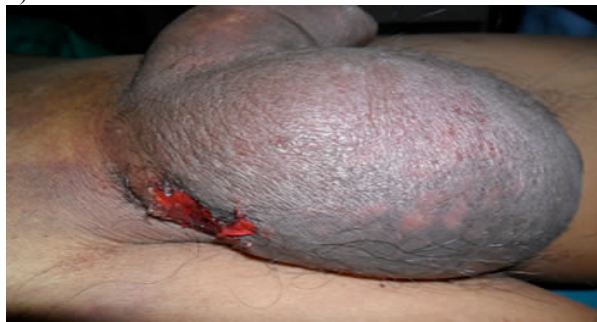base of the right scrotal cavity with scrotal hematoma was made.

The patient's haemoglobin was 11.0g/dl and all the other indices were normal. A chest x-ray done revealed no fractures on the right side of his chest. However a pelvic x-ray showed an irregular radio-opaque mass on the right side of the patient's scrotum (Arrow in Figure 1).



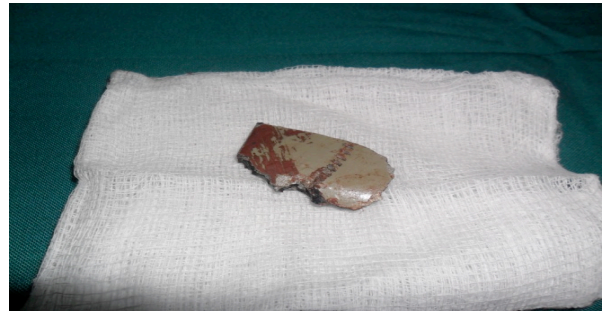**Figure 1** X-ray showing radio-opaque object in right scrotum (Arrow).

The patient was given an initial dose of tetanus prophylaxis, analgesia and started on antibiotics. An informed consent was obtained for surgery, which was done under general anaesthesia. The findings at surgery were a right scrotal hematoma with swelling (Figure 2), an area of skin necrosis and a metallic foreign body (Fig 3).



**Figure 2** Scrotal hematoma

An incision was made over the right scrotal area and the hematoma was evacuated. A 4cm x 6cm rectangular piece of metal was removed from the deeper scrotal layers (Figure 3). The rectangular piece of metal could be part of the engine block. The lacerated testicular vessels were ligated and an ischemic but viable testis was seen hanging on an intact vas deferens and its vessels. The testis was preserved, a drain was left in situ and the laceration was closed in two layers. The estimated blood loss was 100mls.



**Figure 3** Metal piece removed from scrotum

Postoperatively the patient did very well and alternate daily dressing was done. During the course of his admission the patient was able to urinate normally. The drain was removed on the third post-operative day. The scrotal swelling continued to decrease and the wound remained clean. On the seventh post-operative day the patient was discharged to continue his regular dressing at a clinic closer to his home and to come for review after a week. Post operative review indicated a normal sized right testis

## DISCUSSION

Although male genital injuries are rarely life threatening they demand prompt and appropriate management to prevent long-term sexual and psychological damage<sup>6</sup>. It has been reported that up to 85% of testicular injuries are a result of blunt trauma<sup>2,3</sup> with the remaining percentage caused by penetrating, bite injuries and self-mutilation or assault.<sup>6</sup> According to the literature up to 83% of patients presenting with penetrating trauma to the scrotum or penis have other injuries.<sup>7,8</sup>

Our patient sustained several superficial injuries due to metal pieces and a laceration on his upper eyelid.

In our patient the history of a blast and a general examination of the tear in his trousers and pants tallying with the site of the laceration on his scrotum was consistent with a penetrating projectile trauma and the further lack of an exit wound raised our level of suspicion of there being a foreign body embedded in his scrotum. An adequate physical examination was difficult to obtain, as there was a lot of scrotal pain and swelling.

Even though scrotal ultrasonography (SUS) is the most sensitive and specific imaging method for detecting intrascrotal injury<sup>9-12</sup>, penetrating trauma to the scrotum or penis warrants prompt surgical exploration to accurately assess the extent of damage to the reproductive organs and prevent complications.<sup>6</sup> Our patient had no testicular rupture and our decision to evacuate the large hematoma is supported by reports in literature, which recommends hematoma evacuation to prevent infectious complications, prolonged pain, disability and ischemia of the testis from compression.<sup>13</sup>

Even though the use of a retrograde urethrogram (RUG) has been recommended in the setting of penetrating genital injuries<sup>6</sup> it was not done in this case as intraoperative findings did not suggest any urethral damage. Viable testicular tissue should be salvaged when possible because endocrine function is usually maintained, and the psychological benefit of preserving the native testicle is considered to be substantial. Follow up studies show no detrimental effect of testicular salvage on subsequent fertility.<sup>2,14</sup>

However, when massive injury is sustained, resulting in scant viable testicular parenchyma, orchidectomy should follow. McCormack *et al*<sup>14</sup> reported the value of early exploration and repair in reducing complications and hospitalization. A few years later, Gross<sup>15</sup> reported that the probability of testicular salvage after blunt trauma decreased from 80% to 32% if the exploration was delayed by more than 3 days. Jeffrey *et al*<sup>16</sup> and Lupetin *et al*<sup>11</sup> similarly reported the rate of testicular salvage to be 90% when explored within 72 h, and only 45% when surgery was delayed by > 72 h.

## CONCLUSION

This case report highlights the need for a good history and thorough general examination to establish the mechanism of injury in order to distinguish between an embedded penetrating projectile injury and an injury with an exit wound. It has also shown that prompt surgical exploration with hematoma evacuation is important if complications are to be kept to a minimum.

## REFERENCES

1. Cass AS. Testicular trauma. *J Urol* 1983; 129: 299–300.
2. McAninch JW, Kahn RI, Jeffrey RB, Laing FC, Krieger MJ. Major traumatic and septic genital injuries. *J Trauma* 1984; 24 : 291–8.
3. Cass AS, Luxenberg M. Testicular injuries. *Urology* 1991; 37 : 528–30.
4. Seng YJ, Moissinac K. Trauma induced testicular torsion. a reminder for the unwary. *J Accid Emerg Med* 2000; 17: 381–2.
5. Gomes CM, Ribeiro-Filho L, Giron AM, Mitre AI, Figueria ER, Arap S. Genital trauma due to animal bites. *J Urol* 2000; 165 : 80–3.
6. Morey AF, Metro MJ, Carney KJ, Miller KS, McAninch JW. Consensus on genitourinary trauma: external genitalia. *British Journal of Urology* 2004; 94:507-515.
7. Gomez RG, Castanheira ACC, McAninch JW. Gunshot wounds to the male genitalia. *J Urol* 1993; 150:1147-1149.
8. Cline KJ, Mata JA, Venable DD, Eastham JA. Penetrating trauma to the male genitalia. *J Trauma* 1998; 44:492-494.
9. Albert NE. Testicular ultrasound for trauma. *J Urol* 1980 October; 124:558-559/
10. McConnell JD, Peters PC, Lewis SE. Testicular rupture in blunt scrotal trauma. A review of 15 cases with recent application of testicular scanning. *J Urol* 1982; 128:309-311.
11. Lupetin AR, King W, Rich PJ, Ledeman RB. The traumatized scrotum. Ultrasound evaluation. *Radiology* 1983; 148:203-207.
12. Anderson KA, McAninch JW, Jeffrey RB, Laing FC. Ultrasonography for the diagnosis and staging of blunt scrotal trauma. *J Urol* 1983; 130:993-995.
13. Kukadia AN, Ercole CJ, Gleich P, Hensleigh H, Pryor JL. Testicular trauma. potential impact on reproductive function. *J Urol* 1996; 156 : 1643–6.
14. McCormack JL, Kretz AW, Tocantis R. Traumatic rupture of the testicle. *J Urol* 1966; 96 : 80- 2.
15. Gross M. Rupture of the testicle: The importance of early surgical treatment. *J Urol* 1969; 101 : 196–7.
16. Jeffrey RB, Laing FC, Hricak H, McAninch JW. Sonography of testicular trauma. *Am J Roentgenol* 1983; 141: 993–5