

HELD TO RANSOM - CMV TREATMENT IN SOUTH AFRICA

Fatima Laher¹, MB BCh, Dip HIV Man (SA)
 Gail Ashford², FCFP, Dip HIV Man (SA), DMH (SA)
 Angela Cescon³, BSc/BPHE
 Claire Cullen⁴, MB BCh
 Erica Lazarus¹, MB BCh, Dip HIV Man (SA)
 Adrian Puren⁵, MB BCh PhD
 Linda Visser⁶, FCOphth

¹Perinatal HIV Research Unit, Soweto, Johannesburg

²Donald Gordon Medical Centre, Parktown, Johannesburg

³Faculty of Health Sciences, Simon Fraser University, Canada

⁴Department of Ophthalmology, University of Limpopo and Dr George Mukhari Hospital, Limpopo Province

⁵National Institute for Communicable Diseases, Sandringham, Johannesburg

⁶Department of Ophthalmology, University of KwaZulu-Natal, Durban

Cytomegalovirus is a multi-systemic infection reactivated in the immunocompromised. Diagnosis and treatment are prohibitively costly in sub-Saharan Africa, and efforts need to be made for their price reduction to support the expanding highly active antiretroviral treatment programme in the region.

Almost all humans are latently IgG-seropositive for the double-stranded DNA human herpesvirus 5 named cytomegalovirus (CMV). CMV is an AIDS-defining World Health Organization (WHO) stage 4 opportunistic infection for both adults and children, seen when the CD4 T-cell count falls below 100 cells/ μ l and as an immune reconstitution syndrome after starting highly active antiretroviral therapy (HAART).¹

CLINICAL MANIFESTATIONS

Active CMV disease may present multi-systemically, with significant morbidity and mortality. Organ system manifestations include:

CMV retinitis (CMV-R). This is a visual emergency usually presenting with blurred vision, floaters, black spots, flashing lights, distortions, redness and photophobia, but sometimes asymptomatic. WHO clinical diagnosis guidelines for CMV-R include dilated pupil indirect fundoscopic identification of 'discrete patches of retinal whitening with distinct borders, spreading centrifugally, often following blood vessels, associated with retinal vasculitis, haemorrhage and necrosis'.² Figs 1 and 2 show CMV-R before and after local treatment, respectively. This fundoscopic picture is known as the 'pizza pie' appearance. CMV-R may result in blindness.³

CMV of the gastro-intestinal tract. Colitis is symptomatic as chronic watery diarrhoea that may become

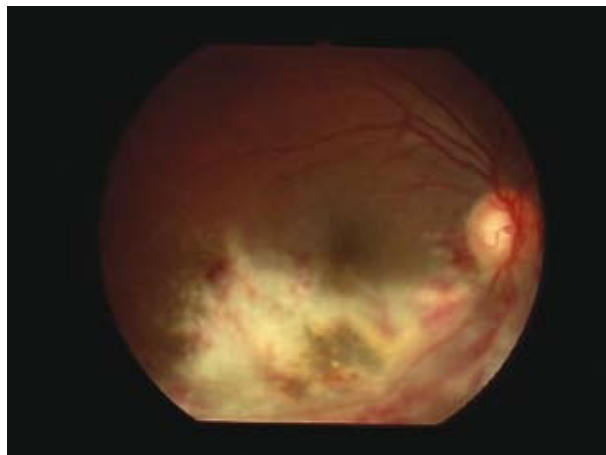


Fig. 1. CMV Retinitis at baseline. Full-thickness retinal necrosis along the inferotemporal arcade with some haemorrhage. There is minimal vitritis and mild macular oedema (courtesy Dr Linda Visser, University of KwaZulu-Natal).

bloody, and oesophagitis symptomatic as dysphagia, anorexia and weight loss. Hepatitis may occur, and there are reports of acalculous cholecystitis.

CMV adrenalitis. Adrenal insufficiency may manifest as postural hypotension, fatigue, hyponatraemia, hyperkalaemia and acidosis. It has a high mortality rate.⁴

CMV pneumonitis. Manifestations are tachypnoea, hypoxia and dry cough, which are commonly misdiagnosed as *Pneumocystis jirovecii* pneumonia.⁵

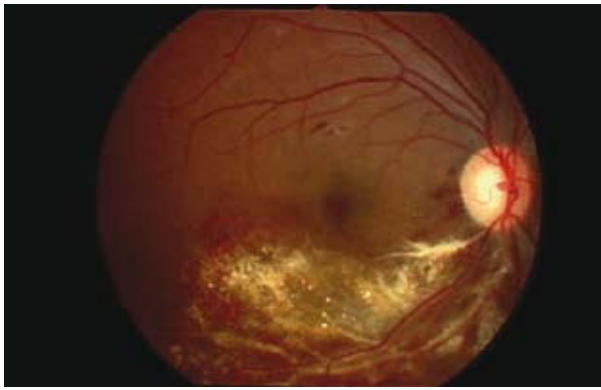

Fig. 2. CMV retinitis after six intra-ocular ganciclovir injections. Note scarring in the area of previous necrosis. There is less vitritis, and the macular oedema has resolved. Haemorrhages may take months to resolve, and intraretinal gliosis can usually be seen late (courtesy Dr Linda Visser, University of KwaZulu-Natal).

CMV of the neurological system.⁶ Encephalitis presents with headache, subacute personality changes, decreased concentration, and progressive dementia. Transverse myelitis may occur. CMV is a recognised cause of acute inflammatory demyelinating polyradiculopathy (Guillain-Barré syndrome), the hallmarks of which are rapidly progressive ascending and often asymmetrical paraesthesiae, sensory loss and areflexia, as well as urinary retention, constipation and incontinence. The cerebrospinal fluid may demonstrate polymorphonucleocytosis and raised protein, and the diagnostic method of choice is polymerase chain reaction (PCR) testing of the cerebrospinal fluid for CMV DNA.

SOUTH AFRICAN SPECTRUM OF DISEASE

Most data for CMV in the developed world were established in the 1990s, before the HAART era. CMV-R was found in a third of AIDS patients, with a large resulting burden of blindness.⁷ In one pre-HAART Swiss study of 48 patients, median survival after CMV retinitis was 6 months.⁸ HAART improved survival markedly in AIDS CMV-R patients.⁹

There is a paucity of CMV data in the developing world. CMV has been called the 'neglected disease of the AIDS pandemic' because of poor diagnostic and treatment capability.¹ In South Africa's pre-HAART era, 90 AIDS patients were treated for CMV-R at the University of Natal over 7 years, and the incidence was noted to increase with time.¹⁰ A cross-sectional study screening all HIV-infected patients with CD4 counts <50 cells/ μ l in Khayelitsha, South Africa, diagnosed CMV-R in 2% of these patients using dilated pupil indirect ophthalmoscopy.¹ In a South African autopsy study of 47 HIV-infected cadavers where the clinician-attributed cause of death had been tuberculosis, CMV pneumonitis was proven in 15% and 66% tested positive for CMV-DNA.¹¹

South Africa has both a high burden of HIV disease¹² and a large, expanding HAART programme.¹³ Many South African HIV-infected patients present for initiation of HAART when the CD4 count is less than 100 cells/ μ l,¹⁴ and often the median is less than 50 cells/ μ l,¹⁵ which makes them susceptible to CMV disease. The return to health and longevity that HAART confers¹⁶ shapes a powerful argument to treat CMV efficiently and prevent its debilitating effects.

DIAGNOSTIC OPTIONS

A variety of testing options exist to identify active systemic CMV infection (Table I). Viral culture is traditionally accepted as the 'gold standard' method of detection.¹⁷ Simpler and more rapid options are now proving as or more effective.¹⁸ The pp65 antigen assay can provide very sensitive results in less than 6 hours, the main drawback being the need for immediate sample processing after retrieval in order to ensure test validity. Serological tests for the presence of IgM and IgG antibodies may have little diagnostic value in the immunocompromised patient. CMV DNA-PCR tests provide sensitive results that can reproducibly quantify CMV viral loads.¹⁹ In HIV-infected patients, both DNA-PCR and pp65 antigen assay have proven to be more predictive in detecting CMV than serology or viral culture.²⁰ The CMV pp67 mRNA test is a promising new method used in research settings.

TREATMENT: THE URGENT NEED FOR VALGANCICLOVIR PRICE REDUCTION IN SA FOR CMV TREATMENT IN HIV PATIENTS

CMV treatment strategies (Table II) include systemic as well as local products, the latter for ophthalmological indications. After completion of an induction phase, patients remain on maintenance therapy until immune recovery (CD4 >100 cells/ μ l).

Because southern African health facilities are poorly resourced, widespread use of intra-ocular ganciclovir (GCV) is not feasible.¹ Specialist ophthalmological services are scarce in the state sector, and sometimes non-existent in rural areas. Intra-ocular GCV may not always be acceptable to patients, and is not without procedure-related adverse effects such as endophthalmitis.¹⁰ Most importantly, intra-ocular GCV does not prevent spread of CMV to the other eye, and completely fails to treat disseminated CMV.^{1,10}

Unfortunately, the exorbitant cost of systemic CMV treatments is prohibitive in the state sector. Systemic GCV necessitates a 3-week stay in hospital for intravenous induction, followed by oral maintenance GCV.²¹ Lengthy intravenous induction is not always realistic in resource-poor settings and may place

TABLE I. CMV DIAGNOSTIC TESTS

Test	Tube/transport	Samples	Volume required	Turnaround time	Price estimate (2009)
CMV viral culture (shell vial)	No preservative Send on ice to arrive at lab and be processed within 24 hours	Urine, CSF aspirate, breastmilk Blood not an ideal sample	1 ml	2 - 7 d (state), 3 - 28 d (pvt)	R82 (state), R97.11 (pvt)
CMV pp65 antigen (IFA)	EDTA, room temperature, must be received at NICD before 14h00 same day as collection	Whole blood Result may be impossible if patient neutropenic	5 ml	1 - 3 d	R171 (state), R182.97 (pvt)
CMV IgG and IgM	Yellow-top	Blood (serum)		1 d	IgG R104.85 (pvt), IgM R113.76 (pvt)
Qualitative CMV DNA-PCR	EDTA	Any sample including blood, CSF, etc.		1 d	R607.14 (pvt)
Quantitative CMV DNA-PCR (i.e. CMV viral load)	EDTA	Whole blood		1 d	R1 214.18 (pvt)

pvt = estimated prices courtesy Toga Laboratories; state = estimated prices courtesy NHLS/NICD.

TABLE II. CMV TREATMENT IN ADULTS

Drug	Dose	Price estimates across sectors			Safety
		Private	State	NGO	
Valganciclovir (Valcyte; Roche) 450 mg per tablet, 60 tablets per bottle	Initiation phase	900 mg bd po with meals x 21 days	R24 719.87 for 21 days	R19 479.32 for 21 days	Specially imprinted price-reduced boxes can be ordered by NGOs from Roche Switzerland*
No generics currently available in South Africa	Maintenance phase	900 mg/d po with meals until HAART restores CD4 count >100 cells/ μ l	R17 657.05 per month	R13 913.85 per month	Doubles ddl levels Monitor FBC 2 - 3 x week Discontinue if neutrophils <0.5 x 10 ⁹ /l or platelets <25x10 ⁹ /l. Adjust doses in renal failure
Ganciclovir (Cymevene; Roche) Inj.: 500 mg in 10 ml vials x5 Caps: 250 mg (84), 500 mg (90) No generics currently available in South Africa	Induction phase: intravenous	5 mg/kg IV bd x 21 days	R2 558.24 for 5 vials	R1 789.65 for 5 vials	N/A
	Maintenance phase: oral	1 g tds po	Oral ganciclovir is not available in South Africa Suggest maintenance with valganciclovir		Beware pancytopenia Monitor FBC every 2 days Reduce dose by 30 - 50% if neutrophils 0.5 - 0.8x10 ⁹ /l. Discontinue if neutrophils <0.5 x 10 ⁹ /l. Cautious use with AZT or ddl: similar toxicities
	Local treatment for CMV retinitis	In a recumbent patient, 2 mg of a 25 mg/ml ganciclovir solution in normal saline is injected with a 1 ml syringe and 30G needle, 4 mm behind the limbus of the eye superiorly with the patient looking down. Patients are given intravitreal ganciclovir injections twice a week for the first 2 weeks, then weekly until immune recovery or retinitis quiescence ⁹			

*Minimum order of CHF 10 000. Each 60-tab box of 450 mg tablets costs CHF 500, plus freight and insurance changes apply (estimated CHF 177.40 + 40.20 respectively for a 26-box order) (CHF = Swiss franc, 1 CHF = 7.47309 ZAR, exchange rate at 1 June 2009). NGO orders can be placed only at Roche Basle (sandra.torriani_cazzato@roche.com). The lead time is 3 months after receipt of firm order. Prices quoted are per Roche, May/June 2009.
FBI = full blood count; AZT = zidovudine.

immune-compromised patients at risk of contracting nosocomial illnesses.

The benefits of valganciclovir are evident: it is taken orally, easy to administer in resource-poor settings, well tolerated, and efficacious in both induction and maintenance phases of treatment.²¹ Its cost currently prevents its use in South African CMV AIDS patients.

Second-line intravenous treatment options such as foscarnet and cidofovir are avoided because of nephro-toxicity.

PAEDIATRIC CMV TREATMENT AND PREVENTION IN PREGNANCY

Congenital CMV causes a broad range of neurodevelopmental deficits in both symptomatic and initially asymptomatic neonates, including microcephaly, chorioretinitis and sensorineural hearing loss.

A 6-week course of intravenous ganciclovir has been shown to be effective in preventing hearing loss, improving weight gain and head circumference, and resolving hepatic dysfunction, hepatomegaly and retinitis. Ganciclovir toxicity, especially neutropenia, can however be life-threatening.²²

Results of a small pharmacokinetic study show that oral valganciclovir at a dose of 16 mg/kg provided similar plasma levels of drug compared with 6 mg/kg intravenous ganciclovir, so it appears that valganciclovir is a promising option for treating neonatal and paediatric patients.²³

Vertical CMV transmission is trans-placental, and the rate is observed to be higher in HIV-1-infected mothers. Infants who are co-infected with HIV-1 and CMV are more likely to have rapid HIV disease progression.²⁴

Valganciclovir and ganciclovir are both considered potentially teratogenic from animal data, but there are no controlled studies in pregnant women.

A recent development in March 2009 is a CMV vaccine that may offer future public health benefits for pregnant women by eliminating congenital CMV.²⁵

HOW CAN VALGANCICLOVIR PRICE REDUCTION BE ACHIEVED IN SOUTH AFRICA?

Currently, the cost of CMV treatment makes it unaffordable to most.

Letters of concern on behalf of the South African HIV Clinicians Society have been sent to Roche urging price

reduction of CMV treatments in the sub-Saharan African region. Various organisations internationally are lobbying for price reduction, including Médecins Sans Frontières, Universities Allied for Essential Medicines and the Clinton HIV/AIDS Foundation.

Valganciclovir for CMV treatment in AIDS patients must be placed on our state tender request list. Currently it is available through state discretionary funds to transplant patients only. Government should consider compulsory licensing for price-slashed generic production of valganciclovir for the state sector.

REFERENCES

1. Heiden D, Ford N, Wilson D, et al. Cytomegalovirus retinitis: The neglected disease of the AIDS pandemic. *PLoS Med* 2007; 4(12): 1845-1851.
2. World Health Organization. *Revised WHO Clinical Staging and Immunological Classification of HIV/AIDS and Case Definitions of HIV and Related Conditions*. Geneva: WHO, 2006.
3. Jacobson MA, Stanley H, Holtzer C, et al. Natural history and outcome of new AIDS-related cytomegalovirus retinitis diagnosed in the era of highly active antiretroviral therapy. *Clin Infect Dis* 2000; 30: 231-233.
4. Eddleston M, Peacock M, Juniper M, et al. Severe cytomegalovirus infection in immunocompetent patients. *Clin Infect Dis* 1997; 24: 52-56.
5. Baughman RP. Cytomegalovirus: The monster in the closet? *Am J Respir Crit Care Med* 1997; 156(1): 1-2.
6. McCutchan JA. Cytomegalovirus infections of the nervous system in patients with AIDS. *Clin Infect Dis* 1995; 20: 747-754.
7. Holbrook JT, Jabs DA, Weinberg DV, Lewis RA, et al. Visual loss in patients with cytomegalovirus retinitis and acquired immunodeficiency syndrome before widespread availability of highly active antiretroviral therapy. *Arch Ophthalmol* 2003; 121: 99-107.
8. Olmari M, Gabriel V, Sansonetti A, et al. Long-term visual outcome in CMV retinitis. Presented at the Xth International Conference on AIDS, Yokohama, Japan, 7-12 August 1994 (abstract no. PB0517).
9. Gross JG, Bozzette SA, Mathews WC, et al. Longitudinal study of cytomegalovirus retinitis in acquired immune deficiency syndrome. *Ophthalmology* 1990; 97(5): 681-686.
10. Visser L. Managing CMV retinitis in the developing world. *Comm Eye Health* 2003; 16(47): 38-39.
11. Martinson NA, Karstaedt A, Venter WD, et al. Causes of death in hospitalized adults with a premortem diagnosis of tuberculosis: an autopsy study. *AIDS* 2007; 21(15): 2043-2050.
12. National Department of Health, South Africa. Report: The National HIV and Syphilis Prevalence Survey South Africa 2007. http://data.unaids.org/pub/Report/2008/20080904_southafrica_anc_2008_en.pdf (accessed 7 May 2009).
13. National Department of Health, South Africa. HIV and AIDS and STI Strategic Plan for South Africa for 2007-2011, 2007. www.doh.gov.za/docs/misc/stratplan/2007-2011/part1.pdf (accessed 7 August 2009).
14. Keiser O, Orrell C, Egger M, et al. Public-health and individual approaches to antiretroviral therapy: Township South Africa and Switzerland compared. *PLoS Med* 2008; 5(7): e148. doi:10.1371/journal.pmed.0050148.
15. Coetzee D, Hildebrand K, Boule A, et al. Outcomes after two years of providing antiretroviral treatment in Khayelitsha, South Africa. *AIDS* 2004; 18(6): 887-895.
16. Lima VD, Hogg RS, Harrigan PR, et al. Continued improvement in survival among HIV-infected individuals with newer forms of highly active antiretroviral therapy. *AIDS* 2007; 21(6): 685-692.
17. Müller LV, Hampf W, Hinz J, et al. High variability between results of different in-house tests for cytomegalovirus (CMV) monitoring and a standardized quantitative plasma CMV PCR assay. *J Clin Microbiol* 2002; 40(6): 2285-2287.
18. Mocarski ES, Shenk T, Pass RF. Cytomegaloviruses. In: Knipe DM, Howley PM, Griffin DE, eds. *Fields Virology*. 5th ed, Philadelphia: Lippincott Williams & Wilkins, 2007: 2701-2772.
19. Boeckh M, Boivin G. Quantitation of cytomegalovirus: methodologic aspects and clinical applications. *Clin Microbiol Rev* 1998; 11(3): 533-554.
20. Dodt KK, Jacobsen PH, Hofmann B, et al. Development of cytomegalovirus (CMV) disease may be predicted in HIV-infected patients by CMV polymerase chain reaction and the antigenemia test. *AIDS* 1997; 11: F21-F28.
21. Martin DF, Sierra-Madero J, Walmsley S, et al., for the Valganciclovir Study Group. A controlled trial of valganciclovir as induction therapy for cytomegalovirus retinitis. *N Engl J Med* 2002; 346: 1119-1126.
22. Nasetta L, Kimberlin D, Whitley R. Treatment of congenital cytomegalovirus infection: implications for future therapeutic strategies. *J Antimicrob Chemother* 2009; 63: 862-867.
23. Kimberlin D, Acosta E, Sanchez P, et al. Pharmacokinetic and pharmacodynamic assessment of oral valganciclovir in the treatment of symptomatic congenital cytomegalovirus disease. *J Infect Dis* 2008; 197: 836-845.
24. Kovacs A, Schluchter M, Easley K, et al. Cytomegalovirus infection and HIV-1 disease progression in infants born to HIV-1-infected women. *N Engl J Med* 1999; 341: 77-84.
25. Pass RF, Zhang C, Evans A, et al. Vaccine prevention of maternal cytomegalovirus infection. *N Engl J Med* 2009; 360: 1191-1199.