

Acanthosis nigricans: a flag for insulin resistance

Venkatswami S, MD(Dermatology), Senior Resident

Department of Dermatology, Sri Ramachandra University, Tamil Nadu, India

Anandan S, MD(Dermatology), Professor

Department of Dermatology, Sri Ramachandra University, Tamil Nadu, India

Correspondence to: Sandhya Venkatswami, e-mail: sandhyavenkatswami@yahoo.com

Keywords: acanthosis nigricans, insulin resistance, grades, texture

Abstract

Objectives: Acanthosis nigricans refers to the velvety, black hyperpigmentation seen in the flexures. It is a cutaneous marker for insulin resistance (IR), some metabolic disorders and rarely malignancy. When secondary to IR, it is asymptomatic, except for the hyperpigmentation. The neck is the most accessible and easiest to grade. Our aim was to identify the predictive value of the grades of acanthosis nigricans in identifying IR, the predictive value of the textures of acanthosis nigricans in identifying IR, and the diagnostic utility of acanthosis nigricans grading in comparison to the laboratory tests.

Settings and subjects: The institutional ethics committee of Sri Ramachandra University approved this study. Three hundred, consecutively presenting adults (50 males) with acanthosis nigricans on the neck were enrolled.

Design: History, physical parameters and acanthosis nigricans grades, location and textures were noted. An oral glucose tolerance test (OGTT), fasting serum insulin and homeostasis model assessment of IR (HOMA IR) were carried out. The acanthosis nigricans grades were correlated to establish any association. Thirty obese controls without acanthosis nigricans were included.

Outcome measures: OGTT, fasting serum insulin and HOMA IR were the outcome measures studied.

Results: This cross-sectional study revealed that 94 subjects with acanthosis nigricans (31.34%) had IR. Grades III and IV, and textures II and III, were more predictive of IR. Acanthosis nigricans grading was insignificant in the non-insulin-resistant group. Acne (p-value 0.379), hirsutism (p-value 0.12) and acrochorda (p-value 0.415) were not significantly associated with IR.

Conclusion: Severe grades and higher textures of acanthosis nigricans are reliable clinical diagnostic tools for IR. The absence of acanthosis nigricans was not associated with IR. Acanthosis nigricans grading is an inexpensive and non-invasive way of identifying pre-diabetes.

Peer reviewed. (Submitted: 2013-11-04. Accepted: 2014-05-04.) © SEMDSA

JEMDSA 2014;19(2):68-74

Introduction

The skin functions as an endocrine organ, producing various hormones and possessing specific hormone receptors. Many endocrine disorders manifest themselves as skin afflictions. Insulin resistance (IR) is a continuously high level of plasma insulin in response to a glucose challenge due to resistance to insulin at cellular level.¹ It is a precursor to obesity, vascular disorders, infertility, growth abnormalities, cardiac complications and type 2 diabetes mellitus.² Acanthosis nigricans is a well established cutaneous marker for IR. It was added to the list of markers for the risk of diabetes in 2000 by the American Diabetes Association.³ In one study, patients without acanthosis nigricans never had IR.⁴

Acanthosis nigricans can be classified as benign, pseudo associated with obesity, syndromic, malignant, acral, unilateral, drug induced and mixed.⁵ The back of the neck and axilla are most commonly involved in IR. Clinically, the neck is the most easily accessible area for examination. Skin colour may influence the presence of acanthosis nigricans. People with the type IV Fitzpatrick phototype, common in south India, have a high frequency of acanthosis nigricans on the neck.⁶

Insulin and insulin-like growth factor 1 and their receptors on keratinocytes are involved in the complex regulations leading to peculiar epidermal hyperplasia. Stuart proposed a correlation between acanthosis nigricans and IR.⁷

The Indian scenario

India is the “diabetes capital of the world”. The number of people with diabetes is expected to rise to 69.9 million by 2025.⁸ Subjects with a high socio-economic status with a positive family history of diabetes have a five times greater prevalence of glucose intolerance than those with a low socio-economic status.⁹ The prevalence of impaired glucose tolerance is approximately 8.7% in urban areas and 7.9% in rural areas, of which 35% proceed to type 2 diabetes.¹⁰ Most patients with diabetes already experience vascular complications at the time of diagnosis. Hence, early diagnosis of IR is crucial in preventing morbidity.

This study was undertaken to correlate the presence of acanthosis nigricans with IR, and identify if acanthosis nigricans grading and textures are sound diagnostic tools in this regard in population-based screenings in resource-limited settings.

Method

A case-control study was conducted as part of the cross-sectional survey, SanMetLife, at Sri Ramachandra University, Chennai, Tamil Nadu, India. The protocol was approved by the Indian Council of Medical Research and Institutional Ethics Committee. Recruitment occurred between July 2008 and January 2012. Informed consent was obtained prior to enrolment. Three hundred consecutively presenting subjects with acanthosis nigricans on the neck, aged 18-55 years, attending the dermatology outpatient department, were included. Pregnant and nursing women were excluded. Thirty obese subjects with a body mass index (BMI) > 30, who were age and gender matched, without acanthosis nigricans, were included as controls from the dermatology outpatient department, in whom there was no IR on investigation.

A detailed history was taken and a systemic examination conducted. Vital statistics, height, weight, BMI and waist to hip ratio were recorded. BMI (kg/m²) was documented. Knuckles, elbows and knees, palms, soles and the oral cavity were also examined for acanthosis nigricans.

Enrolled participants underwent the following tests at Sri Ramachandra University’s central diagnostic laboratory after an overnight fast. An oral glucose tolerance test (OGTT) was performed using the hexokinase method and included blood sugar levels at fasting and at two hours after a 75 g glucose load. Fasting serum insulin levels were calculated using AxSYM® Auto Analyser (Abbott Laboratories, North Chicago, USA). Lipid profiles were assessed using the enzymatic method.

Diagnostic criteria

BMI was classified as per the World Health Organization criteria (Table I).¹¹ Fasting blood sugar (FBS) < 6.99 mmol/l and a two-hour challenge of 7.77-11.04 mmol/l was considered to be diagnostic of IR.¹² The homeostasis model assessment for IR (HOMA IR) was calculated using the equation: fasting serum insulin (μU/ml) x fasting plasma glucose (mg/dl)/405.¹³ A level < 27 μ/ml was considered to be insulin sensitive and > 27 μ/ml to constitute insulin resistance.¹¹

Table I: Body mass index classification chart

| Classification | Body mass index (kg/m ²) |
|---------------------|--------------------------------------|
| Underweight | < 18.5 |
| Normal range | 18.5-25.99 |
| Pre-obese (class I) | 30-34.99 |
| Obese (class II) | 35-39.9 |
| Obese (class III) | > 40 |

Neck and texture was graded in acanthosis nigricans (Tables II and III), as well as axilla (Table IV).

Table II: Neck grading in acanthosis nigricans

| Neck grading | Description |
|--------------|---|
| I | Visible only on close inspection |
| II | Confined to the base of the skull |
| III | Extending laterally up to the posterior border of the sternocleidomastoid muscle. This is not visible when the patient is viewed from the front |
| IV | Visible (encircling the neck) when the subject is viewed from the front |

Table III: Neck texture grading in acanthosis nigricans

| Neck texture grading | Description |
|----------------------|--|
| 0 | Smooth to the touch |
| 1 | Rough to the touch |
| 2 | Coarseness is visible |
| 3 | Extremely coarse: “Hills and valleys” are observable on visual examination |

Table IV: Axilla grading in acanthosis nigricans

| Classification | Description |
|----------------|---|
| 0 | Absent |
| 1 | Clearly present on close visual inspection |
| 2 | <i>Mild:</i> Localised to the central portion of the axilla |
| 3 | <i>Moderate:</i> Involving the entire axillary fossa |
| 4 | <i>Severe:</i> Visible from the front or the back of the unclothed participant, when the arms are left to rest against the patient’s side |

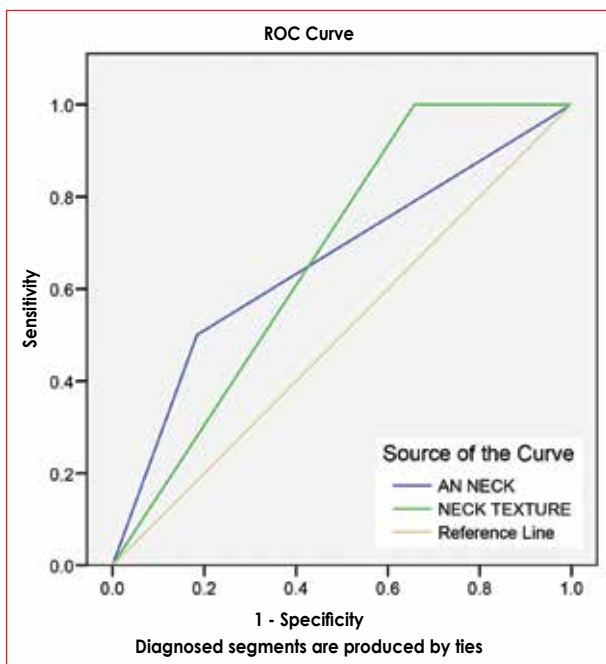
Statistical analysis

Proportions were compared using the chi-square test and the means compared using the t-test. Appropriate nonparametric tests were utilised in case the variables were not normally distributed. Acquired data was analysed using SPSS® version 17. The different grades of acanthosis nigricans were compared using the chi-square test. A comparison of patients with higher and lower grades and textures of acanthosis nigricans, with and without IR, was carried out using the chi-square test for categorical variables and the unpaired t-test for continuous variables. Sensitivity and specificity were calculated and receiver operating characteristic (ROC) curve determined for acanthosis nigricans neck grading and texture. A p-value less than 0.05 was considered to be statistically significant. Logistic regression analysis was carried out to test the hypothesis that severe acanthosis nigricans grades are independently associated with IR.

Results

Characteristics of the population

Of the 300 included subjects, only 50 patients were males. The mean age group was 36.5 years. There was IR in 94 (31.33%), 88 (29.33%) had diabetes mellitus and 118 normal glycaemia. BMI ranged from 23.11-54.30 kg/m². A normal BMI was reported in only 42 subjects. The waist to hip ratio varied from 0:84 to 1:56. The HOMA IR cut-off value in the insulin-resistant population was 2.68 using sensitivity analysis. The cut-off also discriminates well between patients with high-



ROC: receiver operating characteristic; AN: acanthosis nigricans

Figure 1: Receiver operating characteristic curve showing the sensitivity and specificity of the acanthosis nigricans grading in diagnosing insulin resistance

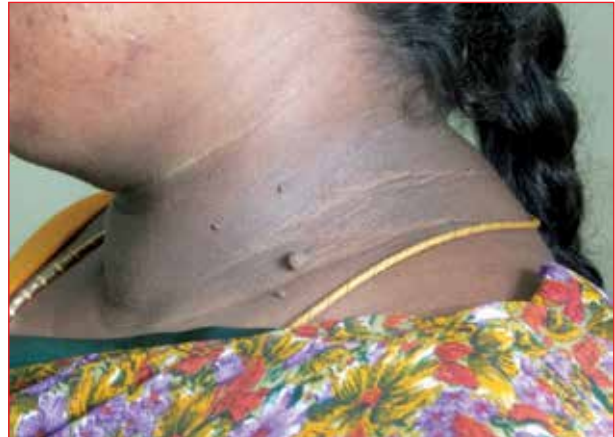

Figure 2: Acanthosis nigricans, neck grade III. Pigmentation on the lateral aspect of the neck, extending up to the posterior border of the sternocleidomastoid muscle

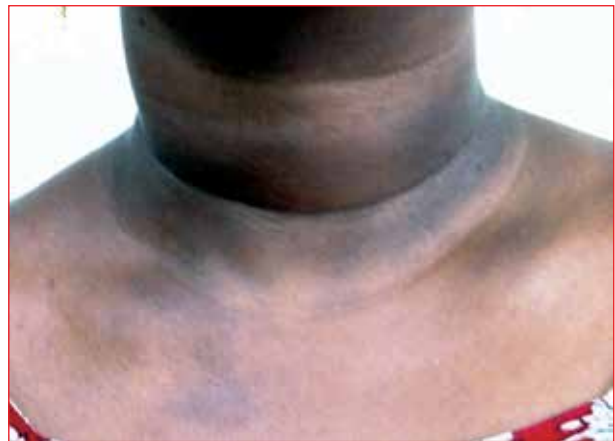

Figure 3: Acanthosis nigricans, neck grade IV. Pigmentation encircling the neck, and visible when facing the subject

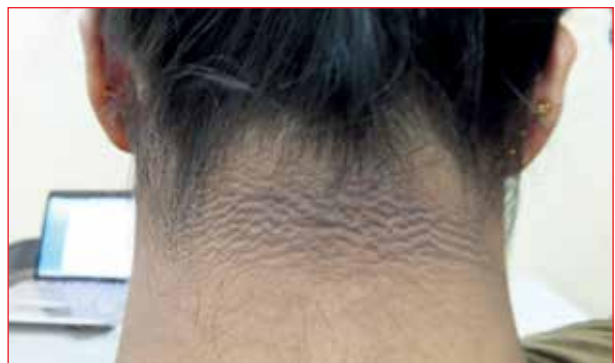

Figure 4: Acanthosis nigricans, neck grade II. Pigmentation at the base of the neck, texture IV. There are visible "hills and valleys" on the pigmented skin

and low-grade AN. The ROC curve nears the upper-left corner of the grid when there is higher sensitivity. From Figure 1, we derived that there was higher sensitivity with regard to the grades, and higher specificity for the acanthosis nigricans textures, when diagnosing IR.

Figures 2, 3 and 4 are examples of neck grading in acanthosis nigricans.

Grades and textures of acanthosis nigricans on the neck

Higher grades and textures of acanthosis nigricans were recorded in patients with IR (Tables V and VI). Of those with IR, higher grades were reported in 72%,

Table V: Distribution of acanthosis nigricans neck grades in those with and without insulin resistance

| Neck grading | Subject with IR n (%) | Subjects without IR n (%) | Total n (%) |
|--------------|-----------------------|---------------------------|-------------|
| Grade I | 2 (2.1) | 40 (19.4) | 42 (14) |
| Grade II | 20 (21.3) | 96 (46.6) | 116 (38.7) |
| Grade III | 40 (42.6) | 56 (27.2) | 96 (32) |
| Grade IV | 32 (34) | 14 (6.8) | 46 (15.3) |

IR: insulin resistance
p-value 0.003

Table VI: Distribution of acanthosis nigricans neck textures in those with and without insulin resistance

| Neck texture grading | Subjects with IR n (%) | Subjects without IR n (%) | Total n (%) |
|----------------------|------------------------|---------------------------|-------------|
| 0 | 0 (0) | 6 (2.9) | 6 (2) |
| I | 26 (27.7) | 112 (54.4) | 138 (46) |
| II | 40 (42.6) | 66 (32) | 106 (35.3) |
| III | 28 (29.8) | 16 (7.8) | 44 (14.7) |
| IV | 0 (0) | 6 (2.9) | 6 (2) |

IR: insulin resistance
p-value 0.004

Table VII: Characteristics of patients with varying acanthosis nigricans neck grades

| Characteristics | Grade I n = 42 | Grade II n = 116 | Grade III n = 96 | Grade IV n = 46 | p-value |
|--|----------------|------------------|------------------|-----------------|---------|
| Age | | | | | |
| Mean ± SD | 28.04 ± 4.34 | 31.52 ± 3.62 | 29.37 ± 3.27 | 30 ± 4.12 | 0.350 |
| Gender | | | | | |
| n (% of women) | 38 (90) | 106 (91.37) | 8 (91.66) | 41 (89.13) | 0.781 |
| Body mass index | | | | | |
| Mean ± SD | 28.78 ± 2.32 | 29.67 ± 3.74 | 28.57 ± 2.12 | 30.97 ± 1.98 | 0.787 |
| Obese or overweight | | | | | |
| n (% of overweight) | 4 (10) | 26 (22.41) | 16 (16.66) | 9 (19.56) | 0.724 |
| Waist to hip ratio | | | | | |
| Mean | 1.00 ± 0.098 | 1.04 ± 0.132 | 1.04 ± 0.094 | 1.03 ± 0.189 | 0.369 |
| Hypertension | | | | | |
| n (%) | 1 (2.38) | 5 (4.31) | 7 (7.29) | 5 (10.86) | 0.704 |
| FBS (mg/dl) | | | | | |
| Mean ± SD | 119 ± 36.50 | 105 ± 48.63 | 90 ± 40.24 | 95 ± 42.13 | 0.627 |
| Serum insulin | | | | | |
| Non-insulin-resistant group (mean) (μU/ml) | 11.13 ± 4.76 | 12.74 ± 5.57 | 19.43 ± 4.12 | 14.56 ± 4.65 | 0.581 |
| Insulin-resistant group (mean) (μU/ml) | 28.11 ± 10.65 | 27.82 ± 9.47 | 31.12 ± 9.84 | 30.45 ± 8.82 | 0.042 |
| Dyslipidaemia | | | | | |
| n (%) | 15 (35.7) | 39 (33.62) | 26 (27.08) | 11 (23.91) | 0.575 |
| Insulin resistance | | | | | |
| n (%) | 2 (2.1) | 20 (21.3) | 40 (42.6) | 32 (34) | 0.005 |

FBS: fasting blood sugar, SD: standard deviation

and lower grades in 23% (p-value 0.003). Higher-grade texture was present in 30% of IR patients. Lower-grade texture was reported in 86% of non-insulin-resistant patients (p-value 0.004). This significance remained, even after adjusting for confounding factors, such as BMI, abdominal obesity and age.

As per Table VII, we observed that there was no association between acanthosis nigricans grading and age, sex, BMI (p-value 0.787), waist to hip ratio (p-value 0.369), hypertension (p-value 0.704), dyslipidemia (p-value 0.575) and FBS levels.

As shown in Table VIII, when correlated with acanthosis nigricans grades, HOMA values revealed that there was a sensitivity of 81.58% and a specificity of 50% for the grading in identifying the high-risk population for IR. Table IX shows that there was a low sensitivity of 34.21% and high specificity of 100% for the textures in identifying IR.

Grades and texture of acanthosis nigricans axilla

Two hundred and eighty-eight subjects had acanthosis nigricans axilla grades I-IV, and 31.25% of those had IR. Fifty-two (17.3%) had grade I acanthosis nigricans of axilla, 144 (48%) had grade II, 54 (18%) had grade III and 38 (12.7%) had grade IV (p-value 0.00).

Table VIII: Acanthosis nigricans grading and homeostasis model assessment values in the insulin-resistant population

| Acanthosis nigricans | HOMA > 2.68 IR present | HOMA < 2.68 IR absent |
|----------------------|---------------------------|--------------------------|
| Higher grade | 62 | 8 |
| Lower grade | 14 | 8 |

HOMA: homeostasis model assessment, IR: insulin resistance
Sensitivity 81.58%, [95% CI: 71.03-89.54]
Specificity 50%, [95% CI: 24.71-75.29]
Positive predictive value 88.57%, 95% confidence interval: 78.71-94.92
Negative predictive value 36.36%, 95% confidence interval: 17.24-59.33

Table IX: Acanthosis nigricans textures and homeostasis model assessment values in the insulin-resistant population

| Acanthosis nigricans | HOMA > 2.68 IR present | HOMA < 2.68 IR absent |
|----------------------|---------------------------|--------------------------|
| High textures | 26 | 0 |
| Lower textures | 50 | 16 |

HOMA: homeostasis model assessment, IR: insulin resistance
Sensitivity 34.21%, [95% CI: 23.71-45.99]
Specificity 100%, [95% CI: 79.24-100]
Positive predictive value 100%, 95% confidence interval: 86.65-100
Negative predictive value 24.24%, 95% confidence interval: 14.54-36.36

Other sites of acanthosis nigricans

Acanthosis nigricans on the knuckles (p-value 0.033) and IR had a significant relationship, unlike IR and acanthosis nigricans on the knee and elbow, which was insignificant.

Analysis of the diagnostic tests performed on the cases and the controls revealed that OGTT at two hours, fasting serum insulin and HOMA were good indicators of IR as opposed to the FBS value [95% confidence interval (CI): 0.99-1.06].

The mean BMI was 32.36 kg/m² in the age- and sex-matched obese control group with 30 subjects (BMI 30.12-36.43 kg/m²). There was no significant occurrence of IR between acanthosis nigricans patients and controls. However, following a comparison of the obese groups with and without acanthosis nigricans using fasting serum insulin as the diagnostic test, it was demonstrated that patients with acanthosis nigricans were significantly more insulin resistant than the controls without acanthosis nigricans [95% CI: 0.93-0.99]. When using HOMA as a diagnostic test, the same conclusion was drawn [95% CI: 0.76-0.97]. It was found that BMI was significantly higher in patients with acanthosis nigricans. A strong correlation was present between the risk of IR and a history of obesity (p-value 0.006) in parents, grandparents, siblings, and in maternal and paternal aunts and uncles.

The ultrasonogram findings were insignificant (p-value 0.451). The food habits of the subjects had no bearing on their risk of acquiring IR (p-value 0.481). There was no consistent occurrence of thyroid dysfunction in the insulin-resistant population.

Other dermatoses

Acne grade (p-value 0.379), hirsutism (p-value 0.118), skin tags (p-value 0.415), male pattern baldness (p-value 0.131), striae (p-value 0.328), systemic disorders (p-value 0.242) and menstrual cycles (p-value 0.307) were insignificantly associated with IR.

There were significant problems in patients with IR like dermatoses, such as eczema and intertrigo (p-value 0.038). Other dermatological problems, such as alopecia areata, dermatophyte infections, lichen planus, psoriasis, polymorphous light eruptions, pityriasis versicolor, traumatic fissures, vitiligo and warts were not significantly associated.

Discussion

Higher grades of acanthosis nigricans on the neck and axilla are sensitive markers for IR. In our study, we also found axillary acanthosis nigricans severity to be a useful indicator. The drawback to this is accessibility to visual screening in populations who dress conservatively. Our study validates Burke's¹⁴ quantitative scale in the south Indian population.

The HOMA cut-off value in our study was 2.6859. In their study, Ramachandran et al demonstrated a HOMA value of 3.3 in children aged 14 years and younger, and a HOMA value of 3 in children aged 14 years and older.¹⁵ They substantiate our finding of lower HOMA values in an older age group. HOMA IR and fasting serum insulin are excellent diagnostic tools for IR. This study shows that the higher grades and textures of acanthosis nigricans on the neck correlated well with the two diagnostic tests.

An earlier study showed that the presence of acanthosis nigricans had lower sensitivity than BMI in identifying patients with IR,¹⁶ but it did not consider the acanthosis nigricans grades. This contradicts our finding that BMI did not relate to the presence of IR.

Fasting serum insulin and the two-hour OGTT are both good diagnostic tests for IR, but the OGTT is a cost-effective alternative in population-based screenings. FBS levels negatively correlated with serum insulin levels in our study. This is similar to the finding of another study conducted in 2011.¹⁷

Usually, patients' first consultation for acanthosis nigricans is with a dermatologist. High acanthosis nigricans neck grades (III and IV) and textures (II and III), as well as grade IV of axilla, correlate strongly with IR and can to help identify populations at risk in mass screening programmes.

This study had several strengths. We included a large number of participants and recorded their complete data. This is the first study of its kind to have correlated

the grades and textures of acanthosis nigricans with the risk of IR, and to have compared the reliability of acanthosis nigricans grading against that of other gold standards. However, the predominantly urban population and younger subjects were limitations of the study. This may not be representative of the Indian population.

Conclusion

Acanthosis nigricans, a clinical marker for IR when graded, can serve as a diagnostic tool in identifying populations at risk of developing diabetes. It is the test of choice for subjects and clinicians because of its cost-effectiveness, non-invasive nature and minimum interobserver variation. We conclude that acanthosis nigricans grading and texture analysis can help to select individuals for a further pre-diabetic workup, and has a sensitivity and specificity that parallels diagnostic tests, such as OGTT and fasting serum insulin, and even gold standards, such as HOMA IR. Acanthosis nigricans lesions are asymptomatic and are usually ignored by patients until they become of concern cosmetically. Thus, the dermatologist carries considerable responsibility in identifying populations at risk of type 2 diabetes mellitus and hence cardiovascular risk.

References

1. Martin B, Warram J, Krolewski A, et al. Role of glucose and insulin resistance in development of type 2 diabetes mellitus: results of a 25-year follow-up study. *Lancet*. 1992;340(8825):925-929.
2. Freedman D, Khan L, Serdula M, et al. Inter-relationships among childhood BMI, childhood height, and adult obesity: the Bogalusa Heart Study. *Int J Obes Metab Discord*. 2004;28(1):10-16.
3. Fagoi-Campagna A, Narayan KMV, Imperatore G. Type 2 diabetes in children. *BMJ*. 2001;322(7283):377-378.
4. Sadeghian G, Ziaie H, Amini M, Ali Nilfroushzadeh M. Evaluation of insulin resistance in obese women with and without acanthosis nigricans. *J Dermatol*. 2009;36(4):209-212.
5. Schwartz RA. Acanthosis nigricans. *J Am Acad Dermatol*. 1994;31(1):1-19; quiz 20-22.
6. Lopez-Alvarenga JC, Garcia-Hidalgo L, Landa-Anell MV, et al. Influence of skin color on the diagnostic utility of clinical acanthosis nigricans to predict insulin resistance in obese patients. *Arch Med Res*. 2006;37(6):744-748.
7. Stuart CA, Gilkison CR, Smith MM, et al. Acanthosis nigricans as a risk factor for non-insulin dependent diabetes mellitus. *Clin Pediatr (Phila)*. 1998;37(2):73-79.
8. Mohan V, Sandeep S, Deepa R, et al. Epidemiology of type 2 diabetes: Indian scenario. *Indian J Med Res*. 2007;125(3):217-230.
9. Mohan V, Shanthirani C, Deepa R. Glucose intolerance (diabetes and IGT) in a selected South Indian population with special reference to family history, obesity and lifestyle factors: the Chennai Urban Population Study (CUPS 14). *J Assoc Physicians India*. 2003;51:771-777.
10. Jonas JB, Panda-Jonas S, Nangia V, et al. Diabetes mellitus in rural India. *Epidemiology*. 2010;21(5):754-755.
11. Consultation W. Obesity: preventing and managing the global epidemic. Geneva: World Health Organization; 2000.
12. Stumvoll M, Mitrakou A, Pimenta W, et al. Use of the oral glucose tolerance test to assess insulin release and insulin sensitivity. *Diabetes Care*. 2000;23(3):295-301.
13. Matthews D, Hosker J, Rudenski A, et al. Homeostasis model assessment: insulin resistance and β -cell function from fasting plasma glucose and insulin concentrations in man. *Diabetologia*. 1985;28(7):412-419.
14. Burke JP, Hale DE, Hazuda HP, Stern MP. A quantitative scale of acanthosis nigricans. *Diabetes Care*. 1999;22(10):1655-1659.
15. Ramachandran A, Snehalatha C, Yamuna A, et al. Insulin resistance and clustering of cardiometabolic risk factors in urban teenagers in southern India. *Diabetes Care*. 2007;30(7):1828-1833.
16. Nsiah-Kumi PA, Beals J, Lasley S, et al. Body mass index percentile more sensitive than acanthosis nigricans for screening Native American children for diabetes risk. *J Natl Med Assoc*. 2010;102(10):944-949.
17. Srinivasa Nageswara Rao G, Prema G, Priya G, et al. Comparison between serum insulin levels and its resistance with biochemical, clinical and anthropometric parameters in South Indian children and adolescents. *Indian J Clin Biochem*. 2011;26(1):22-27.