

# Maxillary brown tumour: unusual presentation of parathyroid carcinoma

<sup>a</sup>Hannah T, MRCS, PGCE  
Specialist Surgical Registrar

<sup>b</sup>Jones JO, FRCR

Consultant Neuroradiologist

<sup>a</sup>Akoh JA, FRCSEd, FICS, FRCS(Gen)

Consultant General and Transplant Surgeon

<sup>a</sup>Department of Surgery and <sup>b</sup>Imaging Directorate, Plymouth Hospitals NHS Trust, Derriford Hospital, Plymouth, United Kingdom

Correspondence to: Mr JA Akoh, e-mail: [jacob.akoh@nhs.net](mailto:jacob.akoh@nhs.net)

Keywords: parathyroid carcinoma, brown tumour, primary hyperparathyroidism

## Abstract

This is a report of a maxillary brown tumour caused by primary hyperparathyroidism (HPT) secondary to parathyroid carcinoma. A 62-year-old man presented with a large swelling in the right maxilla, which caused right-sided nasal obstruction, intermittent bleeding and diplopia. A computed tomography scan demonstrated an expansible, destructive soft tissue mass centred on the right ethmoid sinus, extending from the maxilla to the orbital floor. Histology showed a central giant cell granuloma of bone, thought to be a brown tumour of HPT and this was supported by serum calcium of 3.0 mmol/l and serum parathyroid hormone of 880 ng/l (normal 7 to 40 ng/l). Parathyroid imaging was consistent with a left lower parathyroid adenoma. The patient underwent removal of the parathyroid gland, left hemithyroidectomy and central node dissection. Histology confirmed parathyroid carcinoma. Surgical removal of the brown tumour was offered but declined. The symptoms improved and the maxillary swelling gradually reduced in size. The management of brown tumours is controversial, but a pragmatic approach is essential to a successful outcome. The general consensus seems to be adequate treatment of the HPT and surgical excision of the brown tumour only if the mass effect of the lesion is troublesome.

Peer reviewed. (Submitted: 2011-01-08, Accepted: 2011-06-29)

JEMDSA 2011;16(2):111-114

## Introduction

Brown tumour, a giant cell granuloma occurring in osteitis fibrosis cystica, represents the terminal stage of the bone remodelling processes occurring as a result of peritrabecular fibrosis and osteoclastic activity.<sup>1</sup> Brown tumours may contain necrotic centres and haemosiderin deposition, which gives them their characteristic colour. The lesions tend to be found in areas of increased bone resorption, the most common sites being the femur, pelvis, ribs and mandible. Involvement of the maxilla is relatively rare, accounting for 4.5 to 11.8% of brown tumours.<sup>2-5</sup> Brown tumours have been reported to occur in approximately 4.5% of patients with primary hyperparathyroidism (HPT), but they very rarely are the presenting feature.<sup>6,7</sup> The presentation of parathyroid carcinoma with a brown tumour of the mandible or maxilla has been described in previous case reports.<sup>5,8,9</sup> We report an unusual case of parathyroid carcinoma presenting with HPT and a brown tumour in the maxilla.

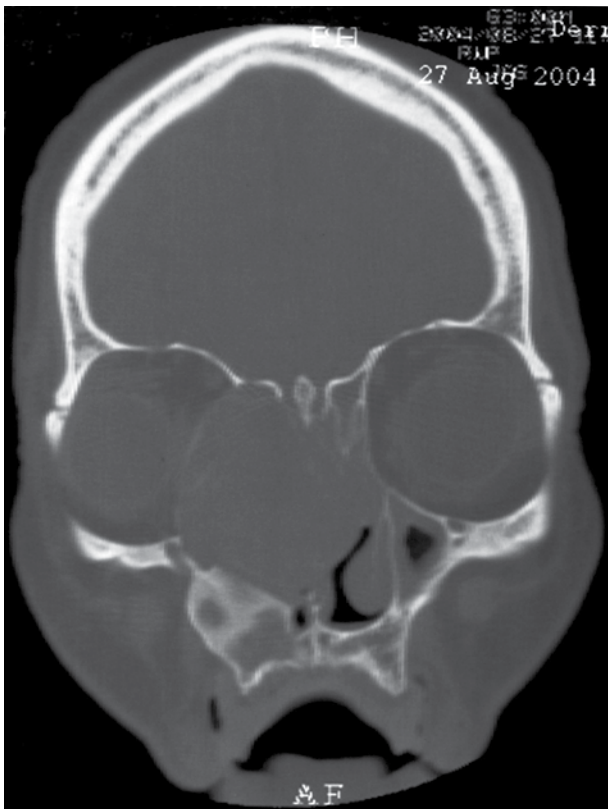
## Case report

A 62-year-old man with a long history of nasal polyposis and multiple polypectomies presented with a large swelling between the nose and the eye on the right side (Figure 1). The

swelling caused right-sided nasal obstruction, intermittent bleeding and diplopia. His past medical history included essential hypertension, transient ischaemic attacks, acute myocardial infarction and asthma. Bone mineral densitometry and a skeletal survey were not performed. A computed tomography (CT) scan (Figure 2) demonstrated an extensive, destructive soft tissue mass centred on the

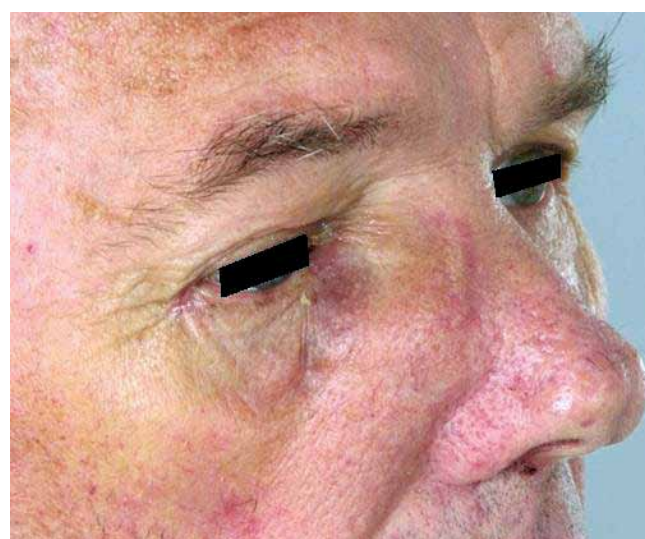

Figure 1: Photograph of patient's face showing mass between right eye and nose



**Figure 2:** Computerised tomography image of brown tumour shortly after presentation

right ethmoid sinus, extending from the maxilla to the orbital floor.

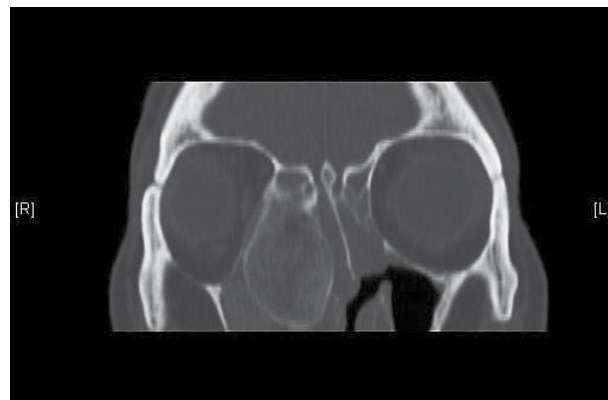
Under general anaesthesia, a biopsy was obtained for histological examination. This showed collections of multinucleated osteoclast-like giant cells in a richly vascular spindle cell stroma, with no features of malignancy. A central giant cell granuloma of bone was diagnosed, and HPT was suggested as a possible underlying cause.

Blood analysis revealed a raised total alkaline phosphatase of 191 IU/l (normal range 1 to 74 IU/l), serum calcium of 3.51 mmol/l, serum phosphate of 0.53 mmol/l, creatinine of 123  $\mu$ mol/l and serum parathyroid hormone (PTH) of 827 ng/l (normal range 7 to 40 ng/l). Urinary examination for calcium excretion and assessment of vitamin D status were not performed. A diagnosis of brown tumour due to primary HPT was made. Evaluation of the parathyroid glands was performed using ultrasound and technetium methoxyisobutylisonitrile (Tc MIBI) scan. While the former was normal, the latter showed intense uptake of tracer projected over the left lower thyroid lobe, consistent with a parathyroid adenoma.

The patient underwent removal of the parathyroid gland, left hemithyroidectomy and central node dissection. Histology confirmed parathyroid carcinoma with extensive capsular invasion, but clear margins (2 mm) and central lymph nodes.

Postoperatively the patient developed hypocalcaemia (1.94 mmol/l), which was managed with oral calcium. His serum PTH decreased to 115 ng/l. Surgical removal of the brown tumour was offered but declined.

Examination at one year postoperatively showed resolution of the diplopia, slight reduction in the size of the brown tumour and no evidence of recurrence on whole body Tc MIBI and neck ultrasound. Follow-up CT imaging three years postoperatively (Figure 3) demonstrated a dramatic decrease in the size of the lesion and its associated mass effects, but with an unusual “ground glass” appearance attributable to the secondary ossification of the large tumour, thought to be healing by fibrosis. Six years postoperatively he remained asymptomatic, but with only partial regression of the mass, as expected, due to the ossification of the lesion. There was no evidence of recurrence of the parathyroid carcinoma, and the PTH level was 41.44 ng/l (normal range 15 to 65 ng/l). Subsequent renal ultrasonography revealed two benign cysts in the right kidney.



**Figure 3:** Computerised tomography image of brown tumour three years after parathyroidectomy. The brown tumour can be seen invading the ethmoid air cells and medial wall of the orbit

## Discussion

The biochemical profile of HPT has evolved in recent times, such that the typical presentation is now of asymptomatic hypercalcaemia.<sup>10</sup> Patients with undiagnosed HPT presenting with severe bone disease such as a brown tumour are becoming increasingly less common as a result of earlier diagnosis and improved treatment.<sup>11</sup>

This case posed two diagnostic challenges. Firstly, identifying primary HPT as the cause of the tumour, and secondly, identifying parathyroid carcinoma as the cause of the primary HPT prior to surgery.

Histology alone is insufficient to establish a diagnosis of brown tumour of HPT, as the appearances are

similar to other giant cell lesions such as giant cell reparative granuloma, giant cell tumour, osteoblastoma, chondroblastoma, aneurysmal bone cyst and cherubism.<sup>12</sup> Radiological appearances of brown tumours in the facial bones (well-defined radiolucent osteolytic lesions) are not pathognomonic.<sup>12</sup> Diagnosis therefore is based on biochemical evidence of HPT and compatible histological and radiological features. Unless a brown tumour secondary to HPT is considered in the differential diagnosis of a giant cell bony lesion, its diagnosis would be delayed or missed. With brown tumours becoming less common, an increasingly high index of suspicion is required.

Identifying parathyroid carcinoma as a cause of primary HPT is notoriously difficult to establish, as it is both rare and presents with a clinical and biochemical profile similar to benign parathyroid disorders.<sup>9,13</sup> Therefore the diagnosis is often made intraoperatively or postoperatively.<sup>14</sup> The presence of markedly raised serum calcium and PTH levels, a palpable mass and severe clinical presentation should raise the suspicion of parathyroid carcinoma.<sup>13-15</sup> As there was no palpable parathyroid mass in the present case, and the radiological findings did not suggest carcinoma as a cause of HPT, the diagnosis was made intraoperatively and confirmed on histological examination. The diagnosis of parathyroid carcinoma in this case meets with the strict criteria recommended by DeLellis, as there was invasion of adjacent structures.<sup>16</sup>

In this unusual case the investigation of an uncommon maxillary bony lesion led to the diagnosis of primary HPT due to a parathyroid carcinoma.

This case demonstrates a compatible clinical picture of the hyperparathyroidism-jaw tumour (HPT-JT) syndrome<sup>17</sup> (hyperparathyroidism, parathyroid carcinoma, maxillary brown tumour and renal cysts), but the lack of analysis for the HRPT2 gene makes the diagnosis inconclusive.<sup>17,18</sup> Genetic studies of familial HPT have determined several subgroups of the disease: multiple endocrine neoplasia (MEN) 1, MEN 2, familial benign hypocalciuric hypercalcaemia, and the HPT-JT syndrome. HPT-JT syndrome, the least common and least well-known type of familial HPT, is an autosomal dominant disease caused by inactivating germline mutations of the HRPT2 gene with subsequent loss of parafibromin expression.<sup>19</sup> It is characterised by particularly marked hypercalcaemia and association with parathyroid carcinoma in 15% of the cases.<sup>19,20</sup> In the light of recent reports,<sup>17,18,20,21</sup> further investigation and possibly screening of family members would be helpful in confirming the syndrome and ensuring early diagnosis.

There is controversy regarding the appropriate management of brown tumours. Reporting on a series of 21 patients with brown tumours, Resendiz-Colosia and co-workers concluded that the natural history is spontaneous regression, either partial or complete after correction of HPT.<sup>22</sup> This position is supported by other case reports.<sup>23-25</sup> In certain circumstances, particularly where the tumour involves the facial bones or the spinal canal, this benign tumour can cause direct morbidity and mortality.<sup>24,26</sup> Proimos et al<sup>27</sup> advocated excision of brown tumour in case of continued growth in spite of parathyroidectomy or where tumour size caused incapacity. Others advocate the correction of HPT, as well as surgical removal of the bone lesion.<sup>28</sup> Although the patient in this case had significant symptoms of nasal obstruction, bleeding and diplopia, all related to the brown tumour, he declined surgical removal. Follow-up over six years after parathyroidectomy and the correction of HPT confirmed a partial response, suggesting that even those cases with a significant mass effect are likely to regress over time and that surgical removal may not be necessary.

## Conclusion

This report adds another case of parathyroid carcinoma with a maxillary brown tumour to the literature. A high index of suspicion and thorough diagnostic workup are required to make a timely diagnosis of both parathyroid carcinoma and brown tumour. The management of brown tumours is controversial, but a pragmatic approach is essential to a successful outcome. The general consensus seems to be adequate treatment of the HPT and surgical excision of the brown tumour only if the mass effect of the lesion is troublesome.

## Declarations

There is no conflict of interest that could be perceived as prejudicing the impartiality of the research reported.

This research did not receive any specific grant from any funding agency in the public, commercial or not-for-profit sector.

Permission was obtained from the patient to produce this case report.

## References

1. Nicola DD, Stefano C, Michele F, et al. Brown tumour in a patient with secondary hyperparathyroidism resistant to medical therapy: case report on successful treatment after subtotal parathyroidectomy. *Int J Endocrinol* [serial online]. 2009. Available from: <http://www.hindawi.com/journals/ije/2009/827652/>
2. Triantafyllidou K, Zouloumis L, Karakinaris G, et al. Brown tumors of the jaws associated with primary or secondary hyperparathyroidism. A clinical study and review of the literature. *Am J Otolaryngol*.

- 2006;27:281-286.
- Gurney E, Yigitbasi OG, Bayram F, et al. Brown tumour of the maxilla associated with primary hyperparathyroidism. *Auris Nasus Larynx* 2001;28:369-372.
  - Lehnerdt G, Metz KA, Kruger C, Dost P. A bone-destroying tumour of the maxilla. Reparative giant cell granuloma or brown tumour [Article in German]? *HNO* 2003;51:239-244.
  - Raue F, Haag C, Frank-Raue K. Hyperparathyroidism-jaw tumour syndrome. A hereditary form of primary hyperparathyroidism with parathyroid carcinoma [Article in German]. *Dtsch Med Wochenschr* 2007;132:1459-1462.
  - Keyser JS, Postma GN. Brown tumor of the mandible. *Am J Otolaryngol*. 1996 Nov-Dec;17(6):407-410.
  - Khan A. Primary hyperparathyroidism: diagnosis and management. *Endocr Pract*. 1997;3:22-26.
  - Masson EA, MacFarlane IA, Bodmer CW, et al. Parathyroid carcinoma presenting with a brown tumour of the mandible in a young man. *Br J Oral Maxillofac Surg*. 1993;31:117-9.
  - Pahlavan PS, Severin MC. Parathyroid carcinoma: a rare case with mandibular brown tumor [Article in German]. *Wien Klin Wochenschr* 2006;118:175-179.
  - Bilezikian JP, Silverberg SJ, Shane E, et al. Characterization and evaluation of asymptomatic primary hyperparathyroidism. *J Bone Miner Res*. 1991;6:S85-9.
  - Parisien M, Silverberg S. Bone disease in primary hyperparathyroidism. *Endocrinol Metab Clin North Am*. 1990;19:19-34.
  - Murphey MD, Nomikos GC, Flemming DJ, et al. Imaging of giant cell tumor and giant cell reparative granuloma of bone: radiologic-pathologic correlation. *Radiographics* 2001;21:1283-1309.
  - Chen Q, Kaji H, Nomura R, et al. Trial to predict malignancy of affected parathyroid glands in primary hyperparathyroidism. *Endocr J*. 2003;50:527-534.
  - Clayman GL, Gonzalez HE, El-Naggar A, et al. Parathyroid carcinoma: evaluation and interdisciplinary management. *Cancer* 2004;100:900-905.
  - Shortell CK, Andrus CH, Phillips CE Jr., et al. Carcinoma of the parathyroid gland: a 30-year experience. *Surgery* 1991;110:704-708.
  - DeLellis RA. Parathyroid carcinoma: an overview. *Adv Anat Pathol*. 2005;12:53-61.
  - Chen JD, Morrison C, Zhang C, et al. Hyperparathyroidism-jaw tumour syndrome. *J Intern Med*. 2003;253:634-642.
  - Haven CJ, Wong FK, Van Dam EWCM, et al. A genotypic and histopathological study of a large Dutch kindred with hyperparathyroidism-jaw tumour syndrome. *J Clin Endocrinol Metab*. 2000;85:1449-1454.
  - Lacobone M, Masi G, Barzon L, et al. Hyperparathyroidism-jaw tumour syndrome: a report of three large kindred. *Langenbecks Arch Surg*. 2009;394:817-825.
  - Kelly TG, Shattuck TM, Reyes-Mugica M, et al. Surveillance for early detection of aggressive parathyroid disease: carcinoma and atypical adenoma in familial isolated hyperparathyroidism associated with a germline *HRPT2* mutation. *J Bone and Min Res*. 2006;21:1666-1671.
  - Falchetti A, Marini F, Giusti F, et al. DNA-based test: when and why to apply it to primary hyperparathyroidism clinical phenotypes. *J Intern Med*. 2009;266:69-83.
  - Reséndiz-Colosia JA, Rodríguez-Cuevas SA, Flores-Díaz R, et al. Evolution of maxillofacial brown tumors after parathyroidectomy in primary hyperparathyroidism. *Head Neck*. 2008;30:1497-504.
  - Jebasingh F, Jacob JJ, Shah A, et al. Bilateral maxillary brown tumours as the first presentation of primary hyperparathyroidism. *Oral Maxillofac Surg*. 2008;12:97-100.
  - Benjelloun M, Tarrass F, Alaoui L, et al. Marked facial enlargement in secondary hyperparathyroidism. *Nephrol Dial Transplant*. 2007;22:3082-3083.
  - Fernandez-Bustillo AJ, Martino Gorvea R, Murillo Cortes J, et al. Primary hyperparathyroidism. Presenting as brown tumors in the maxilla. *Med Oral*. 2000;5:208-213.
  - Karabekmez FE, Duymaz A, Keskin M, et al. Huge deforming brown tumour at the maxilla and mandible in a patient with secondary hyperparathyroidism. *J Plast Reconstr Aesthet Surg*. 2008;61:1404-1405.
  - Proimos E, Chimona TS, Tamiolakis D, et al. Brown tumor of the maxillary sinus in a patient with primary hyperparathyroidism: a case report. *J Med Case Reports*. 2009;3:7495.
  - Martínez-Gavidia EM, Bagán JV, Milián-Masanet MA, et al. Highly aggressive brown tumour of the maxilla as first manifestation of primary hyperparathyroidism. *Int J Oral Maxillofac Surg*. 2000;29:447-449.