

A patient with multiple pheochromocytomas and visual loss

Kemp T, MBChB, MMed(IntMed), Cert in Endocrinology and Metabolism(SA) Ascott-Evans BH, MBChB, FCP(SA)
Department of Endocrinology, Faculty of Health Sciences, Stellenbosch University, South Africa

Correspondence to: Dr Tanja Kemp, e-mail: tkemp@sun.ac.za

Keywords: multiple pheochromocytomas, visual loss

Introduction

A young man was diagnosed with Von Hippel-Lindau (VHL) disease. We report the details of his case and review the relevant literature.

JEMDSA 2009;14(2):96-98

Case description

A 23-year-old male patient was referred to the Department of Ophthalmology at Tygerberg Academic Hospital (TAH) after failing a routine driver's licence eye test. He had noticed gradual visual deterioration of his right eye over the preceding months down to a visual acuity of 6/20 but was otherwise asymptomatic. Detailed eye examination detected bilateral retinal haemangioblastomas.

In 1999 the patient was diagnosed at TAH with a pheochromocytoma, after presenting with a hypertensive crisis. A single right adrenal pheochromocytoma was localised with the use of computed tomography (CT) and metaiodobenzylguanidine (MIBG) scanning. Total right adrenalectomy was performed, and histology confirmed the presence of two discrete pheochromocytomas in the same adrenal gland. The patient became normotensive after surgery and was lost to follow-up.

At the current presentation he was again found to be hypertensive, with fluctuating blood pressure measurements between 110/60 mmHg and 180/110 mmHg. In addition, left ventricular hypertrophy was found to be present by echocardiogram. Three 24-hour urine collections for catecholamine determination showed consistent elevation of normetadrenaline (NMA) and vanillylmandelic acid (VMA). A MIBG scan confirmed the presence of a pheochromocytoma in his left adrenal (see Figure 1). A CT scan demonstrated the presence of a large left adrenal mass (see Figure 2) of 65 mm by 25 mm; no other tumours in his abdomen or chest cavity could be demonstrated.

The presence of haemangioblastomas with multiple pheochromocytomas suggested the diagnosis of VHL disease, and further investigations were performed to search for other components of this disease. On magnetic resonance imaging (MRI) of the patient's brain, a small midbrain haemangioblastoma (see Figure 3) was found but no tumours of the endolymphatic sac of his middle ear. Nine asymptomatic spinal cord haemangioblastomas from C2 to L1 were also detected. No epididymal tumours were detected with ultrasound scanning, and a CT scan of his kidneys and pancreas failed to show any cystic or solid lesions.

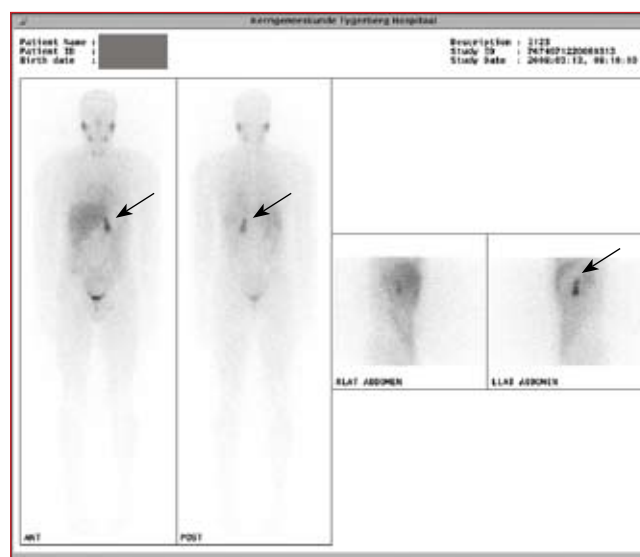


Figure 1: MIBG scan confirming a single left pheochromocytoma (arrows)

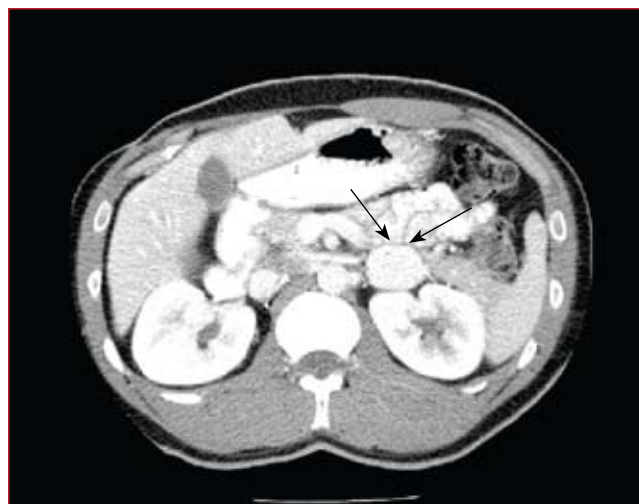


Figure 2: CT scan demonstrating the large left adrenal mass (arrows)

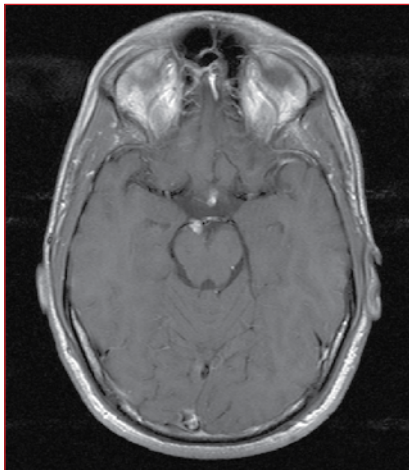


Figure 3: MRI of brain demonstrating a small midbrain haemangioblastoma (arrows)

Blood pressure control was achieved by the initial use of doxazosin, with subsequent addition of propranolol. Elective laparoscopic left total adrenalectomy was performed. Once stable the patient was changed to maintenance oral hydrocortisone and fludrocortisone.

The patient was discharged, with advice to attend follow-up that will involve annual screening for the development of other components of VHL disease. This includes a CT scan of his kidneys and pancreas, measurement of urinary catecholamines and MRI of his brain and whole spinal cord. Surgical management of the right retinal haemangioblastoma was successful; the left retinal haemangioblastoma underwent spontaneous resolution with the formation of fibrosis. Management of the midbrain and spinal cord haemangioblastomas is conservative at present.

The patient was referred for genetic counselling and genetic testing and was informed about the heredity of this condition. Genetic testing confirmed the presence of a germ-line mutation on chromosome 3 (VHL gene) with an in-frame 3 base-pair (GAT) insertion in exon 2 at codon 378. His family members are being tested for this mutation. His father (aged 60) was found to have multiple spinal cord and retinal haemangioblastomas, in keeping with familial VHL disease.

Review of the literature

Several diseases are associated with hereditary pheochromocytomas including VHL disease, multiple endocrine neoplasia (MEN) types 2A and B, and neurofibromatosis type 1.¹ A genetic cause should be considered in young patients presenting with sporadic pheochromocytomas; in patients with a positive family history; in the case of multiple, bilateral or malignant pheochromocytomas; in the case of clinical features suggestive of one of the familial diseases associated with pheochromocytoma; or in the case of sympathetic paragangliomas.¹

VHL disease is an autosomal dominant syndrome associated with a variety of benign and malignant tumours.² Characteristic tumours are haemangioblastomas of the eyes or the central nervous system; clear cell renal carcinomas; pheochromocytomas; endolymphatic sac tumours of the middle ear; serous cysts, cyst adenomas and neuroendocrine tumours of the pancreas; and papillary cystadenomas of the epididymis and broad ligament.^{2,3}

Diagnostic criteria for VHL disease^{2,3}

Positive family history, with one of the following:

- CNS or retinal haemangioblastoma
- Pheochromocytoma
- Clear cell renal carcinoma

Negative family history, with one of the following:

- Two or more haemangioblastomas (CNS or retina)
- One haemangioblastoma + a visceral tumour (excluding renal and epididymal cysts)

The VHL gene abnormality is present in 1/36 000 births and has a high penetrance.^{2,3} Initial manifestations can occur at any age, with a mean age at presentation of 26 years.⁴ The VHL gene has been mapped to the short arm of chromosome 3 (3p25–26). The product, Von Hippel-Lindau protein (pVHL), is a tumour suppressor protein.²⁻⁴ Hypoxia-inducible factor (HIF) plays an important role in the pathogenesis of the vascular tumours in VHL disease.⁴⁻⁷ Hypoxic cells or cells lacking pVHL accumulate high levels of HIF, leading to production of several growth factors, including vascular endothelial growth factor, platelet-derived growth factor beta, transforming growth factor alpha and erythropoietin. This is an important step in the development of highly vascular tumours.^{2,5,7}

Central nervous system (CNS) and retinal haemangioblastomas are usually the first presenting lesions in VHL disease.³ CNS haemangioblastomas are well-circumscribed, vascular, benign tumours that cause symptoms through local pressure or through haemorrhage and can be a major cause of morbidity and physical disability. CNS haemangioblastomas are usually infra-tentorial, the majority occurring in the spinal cord and in the cerebellum; less common sites are the brain stem and supratentorial.⁸ Small lesions can be managed with careful surveillance, with surgery reserved for symptomatic lesions.⁹ Stereotactic radiosurgery and conventional fractionated radiation therapy are also used, but long-term outcome is unknown.⁸

Retinal angiomas or haemangioblastomas affect up to 70% of patients; they are often multifocal and bilateral and may haemorrhage, leading to retinal detachment, glaucoma, cataracts, uveitis, macular oedema or loss of vision.^{2,3} Treatment of retinal lesions includes laser photocoagulation or cryotherapy, with the exception of haemangioblastomas of the optic nerve.²⁻⁴ Vitrectomy or external beam radiotherapy can be utilised for certain indications, and vascular endothelial growth factor receptor inhibitors are gaining ground as novel therapy for this condition.^{2,10}

Pheochromocytomas occur on average in 10–20%² of patients with VHL disease.¹¹ They are often multiple, bilateral or extra-adrenal (12%), and VHL patients tend to be younger than patients with sporadic pheochromocytomas (mean age of presentation is 30 years).² Pheochromocytomas in VHL disease are less likely to

be associated with symptoms and are less likely to be biochemically active than sporadic pheochromocytoma; up to 35% of VHL patients are asymptomatic.^{11,12} Prior to any surgery or pregnancy, all patients with VHL disease have to undergo preoperative screening for occult pheochromocytomas to avoid the risk of a perioperative hypertensive crisis.² Surgical excision is preferably laparoscopic with an attempt made to perform cortical-sparing surgery.^{2,3,8}

Several surveillance strategies for patients with VHL disease have been published.^{3,8} Genetic counselling is important for affected families and especially for those where the index case has an identifiable VHL disease gene mutation.^{3,8} The progress in genetic testing has resulted in members of the family without the gene mutation now being exempted from the rigorous screening protocols.⁸

Acknowledgements

Special thanks to Prof Lizette van Rensburg in Pretoria for genetic testing and the Department of Ophthalmology, Tygerberg Academic Hospital, for their assistance with the patient.

References

1. Gimenez-Roqueplo AP, Lehnert H, Mannelli M, et al. Pheochromocytoma, new genes and screening strategies. *Endocrinol (Oxf)* 2006;65(6):699–705.
2. Lonser RR, Glenn GM, Walther M, et al. Von Hippel-Lindau disease. *The Lancet* 2003;361:2059–2067.
3. Choyke PL, Glenn GM, Walther MM, Patronas NJ, Linehan WM, Zbar B. Von Hippel-Lindau disease: genetic, clinical, and imaging features. *Radiology* 1995;194:629–642.
4. Shuin T, Yamasaki I, Tamura K, Okuda H, Furihata M, Ashida S. Von Hippel-Lindau disease: molecular pathological basis, clinical criteria, genetic testing, clinical features of tumors and treatment. *Jpn J Clin Oncol* 2006;36(6):337–343.
5. George DJ, Kaelin WG. The Von Hippel-Lindau protein, vascular endothelial growth factor, and kidney cancer. *NEJM* 2003;349:419–421.
6. Sufan RI, Jewett MAS, Ohh M. The role of Von Hippel-Lindau tumor suppressor protein and hypoxia in clear cell carcinoma. *Am J Physiol Renal Physiol* 2004;287:F1–6.
7. Pugh CW, Ratcliffe PJ. Regulation of angiogenesis by hypoxia: role of the HIF system. *Nat Med* 2003;9:677–684.
8. Leung RS, Biswas SV, Duncan M, Rankin S. Imaging features of Von Hippel-Lindau disease. *RadioGraphics* 2008;28:65–79.
9. Conway JE, Chou D, Clatterbuck RE, Brem H, Long DM, Rigamonti D. Hemangioblastomas of the central nervous system in Von Hippel-Lindau syndrome and sporadic disease. *Neurosurgery* 2001;48:55–63.
10. Girmens J-F, Erginay A, Massin P, Scigalla P, Gaudric A, Richard S. Treatment of Von Hippel-Lindau retinal hemangioblastoma by the vascular endothelial growth factor receptor inhibitor SU5416 is more effective for associated macular edema than for hemangioblastomas. *Am J Ophthalmol* 2003;136:194–196.
11. Walther MM, Reiter R, Keiser HR, et al. Clinical and genetic characterization of pheochromocytoma in Von Hippel-Lindau families: comparison with sporadic pheochromocytoma gives insight into natural history of pheochromocytoma. *J Urol* 1999;162:659–664.
12. Eisenhofer G, Walther MM, Huynh T, Li S, Bornstein SR, Pacak K. Pheochromocytomas in Von Hippel-Lindau syndrome and multiple endocrine neoplasia type 2 display distinct biochemical and clinical phenotypes. *J Clin Endocrinol Metab* 2001;86:1999–2008.