



# A Study of Some Rostrofacial Indices Related to Regional Anaesthesia of the Porcine: Implications as an Animal Model for Dental Research

**Olopade J.O\* and Okandeji, M.E**

*Comparative Anatomy and Environmental Neuroscience Unit, Department of Veterinary Anatomy  
University of Ibadan, Nigeri*

**Summary:** There has been a widespread use of pigs in medical and biomedical training and research due to many similarities in the morphophysiology of tissues between swine and humans. The aim of this study was to measure some rostrorfacial indices of some indigenous pigs in Nigeria, with a view to providing basic information on some clinically important parameters. Using 26 pigs, the mean values for the mandibular lengths MDL-1 and MDL-2 were  $16.74 \pm 1.76$  cm and  $15.98 \pm 2.32$  cm for the males and  $18.03 \pm 3.04$  and  $17.07 \pm 2.54$  for the females. The mean distance of the infraorbital foramen to the root of the alveolus of premolar three was relatively constant between sexes and age group however, significant differences were found in the distance between the medial mental foramen and the mandibular foramen, between age group within sexes. Several lateral foramina were observed on either side of the bodies of the mandibles, with an average of 6 in the males and 7 in the females with the implications for anaesthesia discussed. With increasing use of the porcine species as experimental models for improvement of human dental implants, this work will further aid the knowledge of the regional anaesthesia of this species in dental implant studies and could be of value in the surgical intervention of priced animals.

**Keywords:** Rostrofacial, Regional anaesthesia, Nerve block, Mastication, Morphophysiology, Pigs

©Physiological Society of Nigeria

\*Address for correspondence (Current address): Unit of Experimental Neurosurgery, Dept. of Neurosurgery Julius Maximilians University of Wurzburg, Germany. [jkayodeolopade@yahoo.com](mailto:jkayodeolopade@yahoo.com); Phone: +234 8023860829

Manuscript Accepted: December, 2010

## INTRODUCTION

Pigs have been described as one of the most prolific and fast growing livestock that can convert food waste to valuable products. Despite its imposing economic importance, the pig occupies a subordinate position in veterinary anatomical instruction. The reasons for this are to be found in the restriction of surgical procedures to a few regions of the body, and in the way that most pigs are kept today (Dyce *et al*, 2002). However, detailed information on porcine anatomy is becoming increasingly important.

The many similarities in the morphophysiology of tissues between swine and humans have resulted in the wide spread use of pigs in medical and biomedical training and research (Vodicka *et al*, 2005; Lunney, 2007,). Recently, some metals like titanium have been considered as universal materials for permanent endosseous dental implants (Soares *et al*, 2010); while most of the research on these

materials are in vitro, a few have been used in vivo on animal models. A crucial prerequisite for the development of safe preclinical protocols in biomedical dental research is a suitable animal model that would allow for human-related validation of gathered valuable research information (Vodicka *et al*, 2005). However baseline research data on the animal species must be updated.

In this present work, we are providing basic information on some clinically important parameters of the rostrorfacial region of the pig that could be of importance in aiding the regional anaesthesia of the head of the animal and dental research.

## MATERIALS AND METHODS

For this study, a total of 26 skulls (14 females and 12 males) of indigenous Nigerian pigs (*Sus scrofa*) were used. The live animals were first selected during ante-mortem examination at an abattoir in Ibadan, South

Western Nigeria. Selection was based on parameters of apparent good health and absence of skeletal deformities in the head. Each animal's age was estimated through dental eruption and the ages varied between 6 and 17 months.

The pigs were restrained and slaughtered by quick decapitation at the occipito-atlantal joint. The severed heads were frozen at -20°C and later prepared according to a modification of the hot water maceration technique, as described (Onar,1999; Olopade, 2003; Olopade and Onwuka, 2006). A total of 19 mandibular and maxillofacial indices were obtained as adapted from Endo *et al*, (1998); Olopade and Onwuka, (2007) and shown in Figures 1 – 10. Measurements were taken using metric rule, vernier caliper and a pair of dividers.

Data obtained were analyzed using the Student “t” test ( $p < 0.05$ ) and Pearson correlation ( $p < 0.05$  and  $p < 0.01$ ). All analyses were done using the SPSS version 15 and presented as mean  $\pm$  S.D.

### Definitions of Measured parameters

Weight of head: **(WOH)**

Distance between the most medial points of the most rostral mental foramina: **(RMF)**

Distance between the two medial mental foramina, just dorsal to the mental angle: **(MMF)**

Distance between the alveolar border of incisor 3 and the most ventral point of the most rostral mental foramen: **(IRMF)**

Length along a horizontal line, from the ventral limit of the mandibular foramen to the caudal border of the mandible: **(MFCB)**

Length, along a vertical line, from the ventral limit of the mental foramen, to the ventral border of the mandibular foramen: **(MFMF)**

Length, along a vertical line, from the ventral limit of the mandibular foramen, to the base of the mandible: **(MFMB)**

Length of the lower jaw from the top of the dental bone to the most caudal projection of the mandibular condyle: **(MDL-1)**

Length of the lower jaw, from the top of the dental bone to the caudal most projection of the angle of the mandible: **(MDL-2)**

Height of the mandibular body between the mid-point of premolar 1 and 2 and the mandibular base: **(HMP)**

Thickness of mandible at molar 1: **(TM-1)**

Thickness between the medial and lateral parts of the ramus at the caudal angle :**(TR)**

Length (diagonal) of the ramus of the mandible between the cranial and caudal angles: **(RAM)**. The cranial angle of the ramus of the mandible is located caudal to the last molar tooth while the caudal angle is located ventral to the caudal border.

Distance from the rostral tip of the nasal bone to the rostral tip of the incisive bone: **(NIL)**

Distance between the caudal limit/rim of the infraorbital foramen and the medial canthus of the orbit: **(IFMO)**

Distance from the ventral limit of the infraorbital foramen to the alveolar border between P3 and P4: **(IFP)**.

Distance, along a horizontal line, between the caudal rim of the infraorbital foramen and the cranial tip of the facial crest: **(FCIF)**

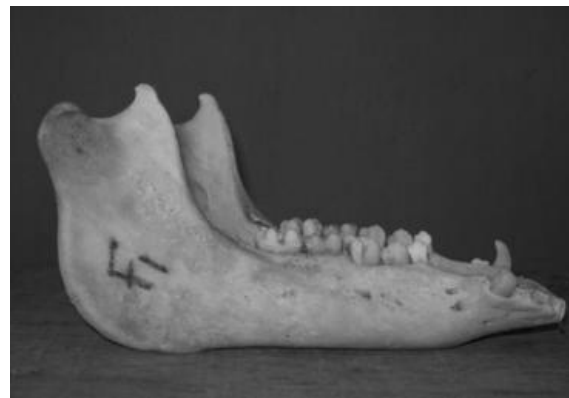Vertical Diameter of the infraorbital foramen: **(DIFv)**

Horizontal Diameter of the infraorbital foramen: **(DIFh)**.

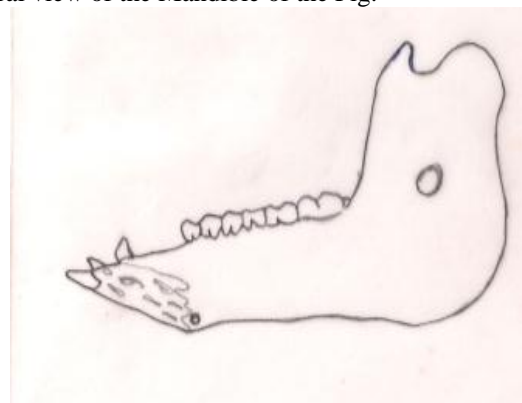
### RESULTS

The mean values and standard deviations of some mandibular measurements are as stated in Table 1.

Of the total 19 parameters measured, dimensions were greater in the females than the males except the MMF and IFP. However, it was only the TR that was significantly ( $p < 0.05$ ) greater in females.



**Figure 1:**  
Lateral view of the Mandible of the Pig.



**Figure 2:**  
Schematic Diagram of the medial view of the Mandible of the Pig.

**Table 1:**  
Some rostrcranial measurements of the Skull of the Pig (cm)

INDICES	Males(Total)	> 1yr	<1yr	Females(Total)	>1yr	<1yr
WOH <sup>∞</sup>	1.96± 0.56	2.28± 0.39	1.80± 0.58	2.00± 0.51*	2.34± 0.40	1.74± 0.45
RMF	1.47± 0.25	1.69± 0.13	1.36± 0.23	1.67± 0.19	1.79± 0.16	1.57± 0.16
MMF	0.63± 0.10	0.71± 0.11	0.59± 0.73	0.61±0.11*	0.69± 0.94	0.55± 0.09
IRMF	1.07± 0.76	1.16± 0.19	1.02± 0.23	1.13± 0.36	1.28± 0.18	1.00± 0.42
MFMF	9.34± 0.95* <sup>ϕ</sup>	9.89± 0.23	8.52± 0.69	9.34±0.95*	10.06± 0.46	8.72± 0.81
MFCB	2.83± 0.34	2.96± 0.17	2.76± 0.39	3.78± 0.58	3.43± 0.79	2.81±0.43
MFMB	3.50± 0.48	3.68± 0.38	3.41± 0.53	3.78±0.58*	4.20± 0.47	3.41± 0.37
HMP	3.07± 0.29*	3.26± 0.21	2.87± 0.22	3.27± 0.47	3.45± 0.42	3.15± 0.49
MDL-1	16.74± 1.76* <sup>©</sup>	18.33± 0.59	16.14± 1.68	18.03± 3.04*	19.97± 3.22	16.36± 1.68
MDL-2	15.98± 2.32*	18.03± 0.59	14.95± 2.16	17.07± 2.54 *	18.72± 2.44	15.66±1.71
TR	0.50± 0.76**	0.48± 0.03	0.52± 0.91	0.55± 0.12	0.62± 0.12	0.49± 0.08
RAM	5.26± 0.45	5.53± 0.25	5.12± 0.48	5.41± 0.59	5.79± 0.49	5.13± 0.53
NIL	1.74± 0.20	1.84± 0.12	1.68± 0.22	1.86± 0.16	1.85± 0.18	1.86± 0.15
IFP	1.36± 0.16	1.44± 0.16	1.31± 0.16	1.30± 0.17	1.31± 0.22	1.30± 0.15
IFMO	4.50± 0.56*	4.89± 0.22	4.28± 0.58	4.71± 0.72	5.10± 0.49	4.41± 0.75
FCIF	0.78± 0.80	0.78± 0.79	0.78± 0.87	0.82± 0.19	0.78± 0.80	0.86± 0.24
DIF <sub>v</sub>	0.78± 0.14	0.86± 0.13	0.74± 0.13	0.93± 0.15	0.91± 0.11	0.94± 0.18
DIF <sub>h</sub>	1.03± 0.24*	1.27± 0.12	0.87± 0.13	1.07± 0.25	1.15± 0.24	1.00± 0.26
TM-1	1.72± 0.25	1.74± 0.40	1.7± 0.13	1.89± 0.19	1.98± 0.19	1.82± 0.17

<sup>∞</sup> Measurement in Kg

\* Significant difference (p<0.05) between age groups within this gender.

\*\*Significant difference (p<0.05) between males and females of both age groups.

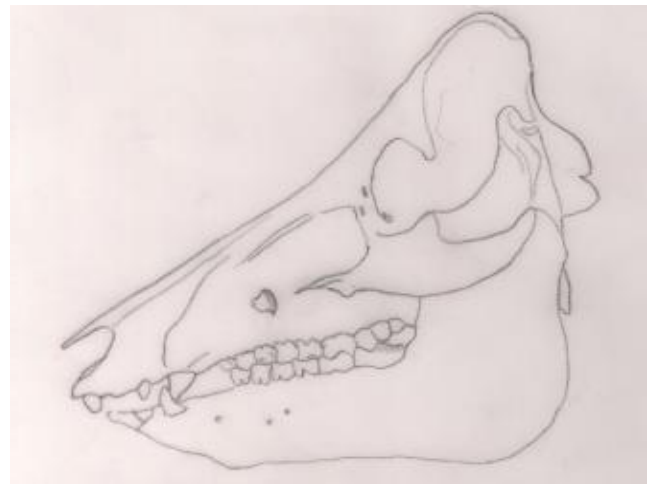
N.B: There was no significant difference between the total males and females.

© Significant positive correlation (p<0.01) between MDL-1 and MDL-2

ϕ Significant positive correlation (p<0.01) between MFMF, and MDL-1 and MDL-2



**Figure 3:**  
Ventral view of the Mandible of the Pig

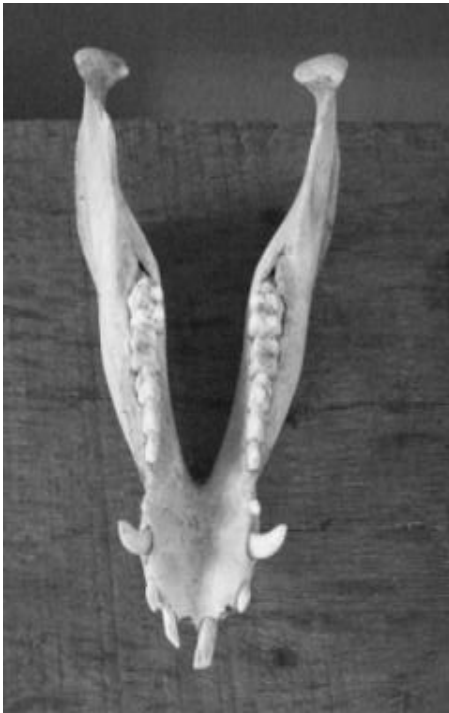

**Figure 4:**  
Schematic diagram of the lateral view of the complete skull of the Pig

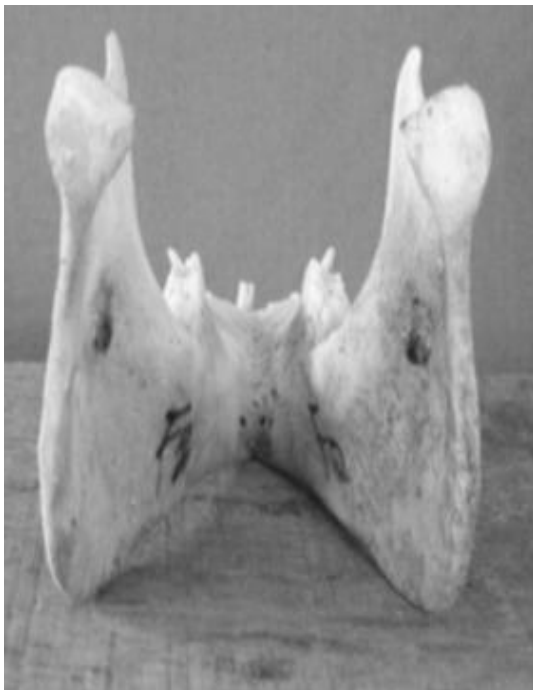Within the females however, significant differences were seen between age groups in the values of WOH, MFM, MFMF, MFMB, MDL1 and MDL 2 while in the males the same pattern was seen in MFMF, HMP, MDL1, MDL 2, IFMO and DIF<sub>h</sub>. A significant positive correlation (p<0.01) was observed between MDL-1 and MDL-2; MFMF and MDL-1 and between MFMF and MDL-2

## DISCUSSION

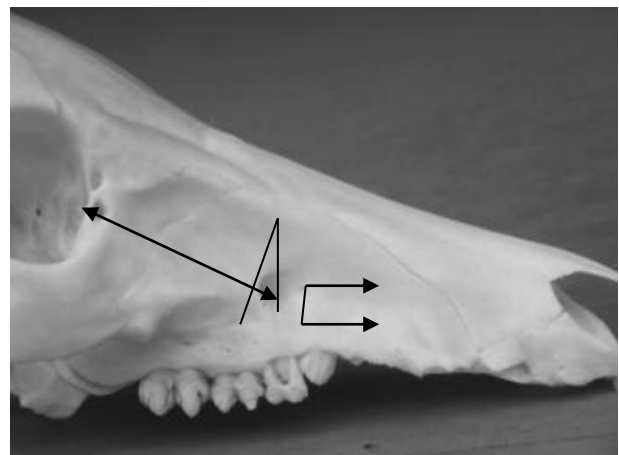
The mean values for the mandibular lengths MDL-1 and MDL-2 were  $16.74 \pm 1.76$ cm and  $15.98 \pm 2.32$ cm for the males and  $18.03 \pm 3.04$ cm and  $17.07 \pm 2.54$ cm for the females, indicating that the females used in this study had higher values for the mandibular lengths compared to the males. This finding is similar to that reported in armadillos where females had relatively longer mandibles and the total length of the mandible was the most important variable to discriminate sexes (Squarcia *et al*, 2010). These mean values in the pigs were higher than the equivalent values in the Red Sokoto and West African Dwarf goats found in North-western, South-western and South-eastern Nigeria, which were 12.7cm, 12cm and 11.81cm respectively (Olopade and Onwuka, 2007). Although females had significantly longer lower jaws when compared to the males, as evident by their higher MDL-1 and MDL-2 values, there was however a significant difference in these indices between pigs below and above 1 year, for each sex. There was also a significant positive correlation ( $p < 0.01$ ) between MDL-1 and MDL-2. This significant difference could be attributed to the differences in the age and sizes of the pigs. The difference between ages may thus be related to the differences in the dentition pattern between the young and the old.



**Figure 5:** Dorsal view of the Mandible of the Pig.



**Figure 6:** Caudal view of Mandible showing the medial mental foramina in the Pig



**Figure 7:** Rostrofacial view of the skull (without the Mandible) of the Pig

The infraorbital nerve block ensures the desensitization of the skin of the lip, nostril and face on that side of the level of the foramen. In the horse, the incisors and first two molars of that same side are also desensitized, while in the pig, its rostral alveolar branch innervating the canine, incisor teeth and the corresponding portion of the gum (Getty, 1975) is also desensitized. The mean distances from the infraorbital foramen to the facial crest, the medial canthus of the orbit and the root of the caudal margin

of the alveolus of the third premolar ranged between 0.78-0.86, 4.20-5.10, and 1.30-1.44cm respectively.

The facial crest in the pig is less prominent than in the horse (Getty, 1975), thus, this information coupled with the observed distance between the medial canthus of the orbit and the infraorbital foramen and the distance between the latter and the root of the teeth would prove a vital guide to the tracking of the infraorbital nerve for regional anaesthesia in the live animal. Though the distance between the caudal limit of the infraorbital foramen and the medial canthus of the orbit revealed significant differences between age groups in males, the distance between the infraorbital foramen and the root of the premolar teeth (IPM) was relatively constant in both sexes and between age groups, suggesting that the upper teeth eruption does not affect the position or location of the foramen. Similarly, the distance of the facial crest to the infraorbital foramen showed no significant sex and age-related difference. Thus, with skull growth and elongation, this index remains relatively constant, and can thus be used as a guide to location the infraorbital nerve for desensitization.

The mandibular nerve block is important for desensitization of all the teeth in the lower jaw of the side of the block. The distances of the mandibular foramen to the base of the mandible and that from the caudal border of the mandible to the ventral limit of the mandibular foramen are clinically important landmarks that will aid regional anaesthesia of this nerve (Hall *et al*, 2000). This nerve block can also be aided by the knowledge of the distance of the caudal border of the mandible to the middle of the mandibular foramen ventrally and that of the distance from the mandibular foramen to the base of the mandible. The mean values in this study were 2.83cm and 3.78 cm, and 3.50cm and 3.78cm, in the males and females respectively. From the study, statistical analysis revealed a significant difference in the distance between the medial mental foramen and the mandibular foramen, between age group within sexes. There was also a strong positive correlation between MFMF AND MDL-1 and MDL-2. Thus, with an increase in the mandibular length, there is a proportionate increase in the MFMF values in both sexes.

The mental nerve supplies tissues of the lower lip and chin. In the pig, several branches exit through as many foramina (Dyce *et al*, 2002). Injection can be made through the mental foramen to desensitize the mental aspect of the mandibular nerve. This will ensure the loss of sensation of the lower incisors, premolars and lower lip on that side (Hall *et al*, 2000). In this study, several lateral foramina were

observed on either side of the bodies of the mandibles, with an average of 6 in the males and 7 in the females. In addition, there were 2 rostral foramina ventral to the lower incisor teeth. Though the distance between the ventral end of the incisor 3 and the most ventral point of the rostral mental foramen did not show any sexual dimorphism or age difference and can be used for a accurate location of the foramina for the desensitization of the lower incisors and lower lip, the multiple lateral foramina may create a challenge in executing a successful nerve block because of accessory mental nerves that may arise through them. According to Balcioglu and Kocaelli (2009), the probability of the existence of an accessory mental foramen should be kept in mind in order to avoid neurovascular complications during implant placement, regional anaesthesia, surgical correction of jaw deformities and periapical surgery.

With increasing use of the porcine species as experimental models for improvement of human dental implants, this work will further aid the knowledge of the regional anaesthesia of this species in dental implant studies and could be of value in the surgical intervention of priced animals.

#### **Acknowledgement:**

We thank the technical staff of Faculty of Veterinary Anatomy for their assistance. This work was supported by University of Ibadan Senate Research Grant UI/FVM/2006/14A to Olopade JO

#### **REFERENCES**

- Balcioglu HA, Kocaelli H. (2009). Accessory Mental Foramen. *North Am J. Med Sci* 1: 314-315.
- Dyce K.M., Sack W.O. and Wensing C.J.G (2002). Textbook of Veterinary Anatomy 3rd edition. W. B. Saunders Company, Philadelphia.
- Endo H., Hayashi Y., Sasaki M., Kurosawa Y., Tanaka K., Yamazaki K. (2000). Geographical Variation of the Mandible Size and Shape in the Japanese Wild Pig (*Sus scrofa leucomystax*). *J. Vet. Med. Sci*; 62(8): 815-820.
- Getty R in Sisson S, Grossman JD (eds). The Anatomy of the Domestic Animals. 5th edition. W.B. Saunders Company. 1975.
- Hall L.W., Clarke K.W., Trim C.M. (2000). Wright's Veterinary Anaesthesia and Analgesia. 10th edition. ELBS and Baillière Tindall, London.
- Lunney J.K. (2007). Advances in Swine Biomedical Model Genomics. *International Journal of Biological Sciences*. 3:179-184.
- Olopade J.O. (2003). The Morphometry of the craniofacial and maxillofacial regions of the West African Dwarf Goats (*Capra hircus*). M. Sc. thesis, Department of Veterinary Anatomy, University of Ibadan, Ibadan, Nigeria.

- Olopade J.O., Onwuka S.K. (2006). An Osteometric study of the skull of the West African Dwarf goat from South Eastern Nigeria: Mandibular and maxillofacial features. *Nig. Vet. J* 27:66-70.
- Olopade J.O., Onwuka S.K.(2007). Osteometric studies of the skull of Red Sokoto (Maradi) goats (*Capra hircus*): Implications for regional anaesthesia of the head. *Int. J. Morphol* 25: 407-410.
- Onar V. (1999). A Morphometric study of the skull of the German Shepherd Dog (Alsatian).*Anat. Hist. Embryol.* 28: 253-256.
- Soares P.B, Magalhães D., FernandesNeto A.J, Castro C.G, Santos Filho P.C, Soares C.J. (2010). Effect of periodontal therapies on indirect restoration: a scanning electron microscopic analysis *Braz Dent J.*21(2):130-6
- Squarcia S.M., Sidorkewicz N.S., Camina R., Casanave E.B.(2010).Sexual dimorphism in the mandible of the armadillo *Chaetophractus villosus* (Desmarest, 1804) (Dasypodidae) from northern Patagonia, Argentina . *Braz. J. Biol* 69:347-352
- Vodicka P., Smetana K, Jr., Dvorankova B., Emerick, T., Xu Y.Z, Ourednik J., Ourednik V. and Motlick J (2005). The miniature pig as an animal model in biomedical research.*Ann NY Acad Sci.*1049:161–171