

Post-laparotomy haemoptysis due to broncho-abdominal fistula caused by retained abdominal surgical swab

Georg EA Jacobs** , Carl S Buss^b and Ross Hofmeyr^c

^aPrivate Practice, Richards Bay, South Africa

^bPrivate Practice, Empangeni, South Africa

^cDepartment of Anaesthesia and Perioperative Medicine, University of Cape Town, Cape Town, South Africa

*Corresponding author, email: georg@iafrica.com

The case presented describes the migration of a surgical swab across the left hemidiaphragm over four years. The patient had at least two episodes of haemoptysis in that period and was misdiagnosed and treated for Pulmonary Tuberculosis. When the proper diagnosis was made and a lobectomy was planned for removal of the swab, the act of anaesthesia revealed a major bronchoabdominal fistula that was resolved by simply isolating that lung with an endobronchial tube. According to our search, such a left-sided broncho-abdominal fistula has, to date, not been described in the literature.

Keywords: broncho-abdominal fistula, gossypiboma

Introduction

A retained swab or sponge after a surgical operation is referred to as a gossypiboma. The word is derived from the Latin '*gossypium*' meaning cotton, and suffixes '-oma' meaning mass, or Kiswahili '*boma*' meaning 'place of concealment'.¹ Another term used in the literature is *textiloma*.² The quoted incidence is approximately 1 in 3000–5000 surgical procedures.³ Medico-legal concerns, however, may lead to significant under-reporting and make this figure uncertain. Most swabs (80%) are found in the abdomen, and symptoms may not appear for months or even years following surgery.⁴ Two broad reactions of the body occur: infection with inflammation, or a sterile inflammatory response with adhesions and eventual encapsulation.⁵ Migration of the gossypiboma has been well described in the literature. Most migration occurs within, around, and even extrudes out of the abdomen.⁶ The authors found only one case of an abdominal surgical sponge migrating through the diaphragm into the chest and presenting as a right-sided lung abscess.⁶ Broncho-abdominal fistula (BAF) is similarly rare with a search yielding two reports involving single cases and one other report involving three cases.^{7–9} All aforementioned BAF cases refer to the right hemi-diaphragm being breached by biliary pathology. No case of BAF has thus far been related to the migration of a surgical swab from the abdomen into the left thorax.

Note: The words 'sponge' and 'swab' are used interchangeably.

Case report

A 34-year-old man sustained an abdominal gunshot wound in 2011, requiring laparotomy at another hospital. Unfortunately, no perioperative records or details for that encounter are known. He presented to our hospital four years later complaining of episodic haemoptysis of one month's duration. Further history spanning the past year included a chronic productive cough, weight loss, left-sided chest pain, shortness of breath and occasional haemoptysis. He denied dyspepsia or epigastric pain.

He described similar symptoms for the previous four years, and had seen numerous doctors. Despite negative sputum tests, he

had undergone full treatment for pulmonary tuberculosis (PTB) twice without improvement. Allegedly, previous doctors told him that a 'cage' seen on chest radiograph (CXR) had been placed around his spleen during laparotomy in 2011 to protect the organ.

Examination on admission revealed a thin (55 kg, 1.63 m, BMI 20.7), pyrexia (38.8°C) man, with moderate shortness of breath at rest. His respiratory rate and peripheral oxygen saturation on room air were 22 per minute and 98% respectively. No fingernail clubbing was noted. Coarse crackles were heard bilaterally on lung auscultation, with markedly diminished air entry at the left lung base. Cardiovascular examination was unremarkable except for a heart rate of 114 beats per minute and haemoglobin of 9.9 g/dl. His blood pressure was 115/57 mmHg.

Abdominal examination revealed a large, elliptical, thin-walled incisional hernia in the midline, extending from the upper abdomen to just below the umbilicus. The spleen was palpable.

The patient's admission CXR showed partial left lower lobe collapse and loss of clear outline of the left hemidiaphragm, with a pleural collection (Figure 1). Radio-opaque threads compatible with a surgical swab were seen in the left upper abdominal quadrant. A computed tomography (CT) scan was requested. The chest and abdomen CT confirmed the diagnosis of gossypiboma situated above the left hemidiaphragm, with an adjacent abscess traversing from above the spleen through the disrupted hemidiaphragm, connecting to a left basal pleural effusion/empyema and consolidated left lower lobe (Figure 2).

An upper midline laparotomy was planned, with extension into the left chest at the level of the ninth–tenth intercostal rib space.

After prophylactic antibiotic administration, induction of anaesthesia was performed using propofol and remifentanyl. Rocuronium was given for neuromuscular blockade. A 37-French left-sided double-lumen endobronchial tube was placed without difficulty. Anaesthesia was maintained with desflurane in nitrous oxide and oxygen. Morphine was added for analgesia. Lung

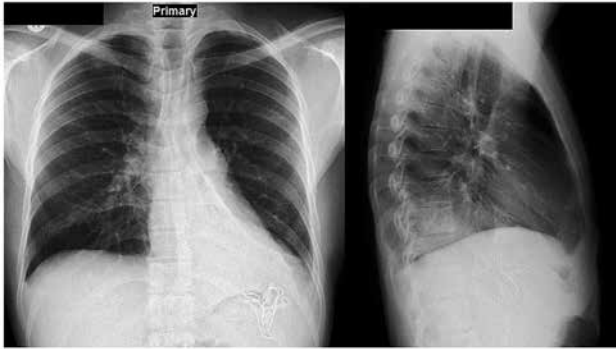

Figure 1: Admission CXR showed partial left lower lobe collapse and loss of clear outline of the left hemidiaphragm, with a pleural collection.

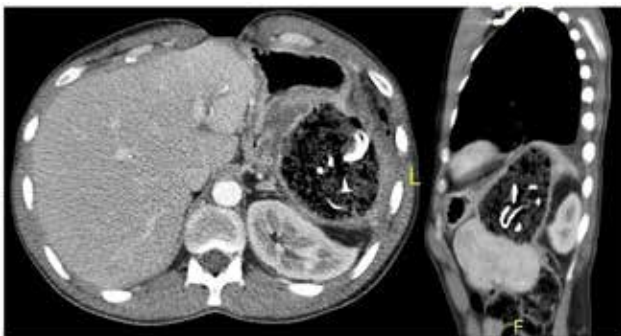


Figure 2: Chest and abdomen CT confirming the diagnosis of gossypiboma situated above the left hemidiaphragm, with an adjacent abscess traversing from above the spleen through the disrupted hemidiaphragm, connecting to a left basal pleural effusion/empyema and consolidated left lower lobe.

isolation and endobronchial cuff position were confirmed with flexible fibre-optic bronchoscopy. A left radial arterial cannula (20G) and a left internal jugular central venous catheter were placed under ultrasound guidance.

Initially, ventilation of both lungs through the tracheal lumen proceeded without difficulty, but over the 30 minutes' post-intubation it became increasingly difficult, requiring increasing airway pressures. Progressive distension of the abdomen was not relieved by the nasogastric tube. The thin-walled abdominal incisional hernia visibly ballooned outwards, and oxygenation began to decrease. Copious quantities of blood-stained secretions were drained from the endobronchial tube.

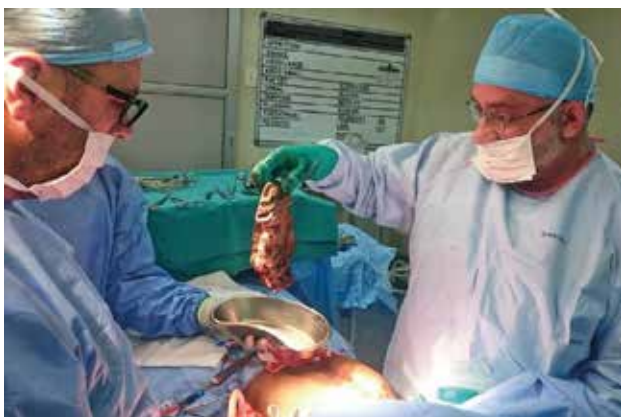

Figure 3: Abdominal swab being removed from chest.

A 'tension pneumoperitoneum' situation was recognised, with abdominal contents compressing the diseased lung through the diaphragm. A broncho-abdominal fistula was diagnosed, with gas moving through the swab-related defect in the diaphragm. Once this was recognised, isolation of the left lung immediately rectified the situation, as the right lung was uninvolved and ventilated easily.

Surgery started in the upper abdomen and was extended into the chest. An old, offensive abdominal swab was removed from above the left hemidiaphragm inside the left chest (Figure 3). The pus-filled cavity communicated above and below the hemidiaphragm across a well-defined defect.

A partial left lower lobectomy was performed; the diaphragmatic hole was repaired; and the area around the spleen debrided with some difficulty. The adjacent stomach was noted to have an 8 cm perforation in the fundal area, with free communication to the abscess cavity. This was repaired primarily, intestine freed from the previous ventral scar, and the medial borders of the rectal sheath mobilised and closed, thus reconstructing the abdominal wall. Chest and abdominal drains were inserted before closure of the incisions.

In the postoperative period, the patient was ventilated in ICU through a single-lumen tracheal tube with morphine analgesia and midazolam sedation. Ventilation was weaned over two days. Oxygenation and ventilation (monitored by blood gas analysis) was normal throughout. Total parenteral nutrition (TPN) was initiated on postoperative day 2, and the patient successfully extubated on day 3. A barium swallow on postoperative day 6 revealed no leakage from the gastric repair.

The patient was discharged after a total of 14 days in hospital. At a one-month follow-up visit, he had good exercise tolerance and no further haemoptysis. Haematological parameters had all returned to normal.

Histological examination of the lung and abscess cavity showed granulation tissue, extensive fibrosis, and abnormally dilated bronchi. Viable *Schistosoma* ova were seen within the wall. No granulomas, acid-fast bacilli, fungi or viral inclusions, or any evidence of malignancy, were observed. The pus from the abscess grew *Escherichia coli* with resistance only to ciprofloxacin.

Discussion

This case highlights the pervasive problem of retained surgical swabs. The effect of migration and resulting damage over five years is shown. All practitioners must be very aware of the typical radiographic appearance of a retained swab on CXR and CT.

To prevent the situation of retained swabs, they should be counted:

- (1) before the procedure starts to establish a baseline;
- (2) before closure of a cavity within a cavity;
- (3) before wound closure begins;
- (4) at skin closure or end of procedure;
- (5) at the time of permanent relief of the scrub person.¹⁰

Lone *et al.* described an incident where a gauze sponge was left in the abdominal cavity for 25 years before presenting as a right-sided lung abscess, resulting in a thoracotomy.⁶ Their report is

similar to that of this patient, although the initial surgery was a cholecystectomy in that instance. Their patient also presented with scanty haemoptysis 13 years after surgery, and twice received treatment for presumed pulmonary tuberculosis. Unlike this case, however, the diaphragmatic defect of that patient was less well defined, and had healed spontaneously, with a thin membrane noticed at time of surgery.

The management of tension pneumoperitoneum or 'abdominal tamponade' following endobronchial intubation of a broncho-abdominal fistula (BAF) is described here. BAF is a rare condition with no reported incidence figures.⁷ Management strategies adopted to treat such cases have been drawn from experience of treating broncho-pleural fistulae (BPF), which are more common and better understood.⁷ Strategies used successfully include differential lung ventilation using double-lumen endotracheal tubes, high-frequency oscillatory ventilation (HFOV), high-frequency jet ventilation (HFJV), and extra-corporeal membrane oxygenation (ECMO). The case presented by Cook *et al.* was initially managed by conventional pressure-controlled synchronised intermittent mandatory ventilation (P-SIMV). After nine days, the amount of gas leaking through the BAF became so problematic that underwater drains had to be used to vent the positive pressure. Subsequent use of HFOV halted the gas loss completely within four days, and the patient recovered on conservative treatment without needing surgery.⁷

The use of sampling tracers such as Xenon-133 or methylene blue were previously used to diagnose BAF. Cook *et al.* also reported the ingenious use of nitrous oxide (N₂O) and a standard anaesthetic gas analyser attached to the abdominal drain to diagnose postoperatively the communication between bronchus and abdominal cavity in the intensive care unit, thereby using N₂O as the tracer.⁷ This test can easily be performed in resource-limited settings. In our case, the BAF was clinically obvious, with abdominal distension occurring soon after intubation and initiation of ventilation. The 8 cm perforation of the gastric fundus was thought to be a result of the damage inflicted by the swab abscess complex in the left upper quadrant.

The practice of treating haemoptysis as TB without bacteriological support or radiographic confirmation until otherwise proven needs careful consideration.

Acknowledgement – Acknowledgement is made to Professor Justiaan Swanevelder of the Department of Anaesthesia and Perioperative Medicine, University of Cape Town, for assistance in preparation of this document.

References

1. Williams RG, Bragg DG, Nelson JA. Gossypiboma—the problem of the retained surgical sponge. *Radiology*. 1978;129(2):323–6. <http://dx.doi.org/10.1148/129.2.323>
2. Kopka L, Fischer U, Gross AJ, et al. CT of retained surgical sponges (textilomas): pitfalls in detection and evaluation. *J Comput Assist Tomogr*. 1996;20(6):919–23. <http://dx.doi.org/10.1097/00004728-199611000-00009>
3. Kiernan F, Joyce M, Byrnes CK, et al. Gossypiboma: a case report and review of the literature. *Ir J Med Sci*. 2008;177(4):389–91. <http://dx.doi.org/10.1007/s11845-008-0197-0>
4. Manzella A, Filho PB, Albuquerque E, et al. Imaging of gossypibomas: pictorial review. *AJR Am J Roentgenol*. 2009;193(6 Suppl):S94–101. <http://dx.doi.org/10.2214/AJR.07.7132>
5. Kim HS, Chung TS, Suh SH, et al. MR imaging findings of paravertebral gossypiboma. *AJNR Am J Neuroradiol*. 2007;28(4):709–13.
6. Lone GN, Bhat AH, Tak MY, et al. Transdiaphragmatic migration of forgotten gauze sponge: an unreported entity of lung abscess. *Eur J Cardiothorac Surg*. 2005;28(2):355–7. <http://dx.doi.org/10.1016/j.ejcts.2005.04.025>
7. Cook C, Weston A, McCallum D. Broncho-abdominal fistula: making the diagnosis and managing the patient. *J Intens Care Soc*. 2009;10(3):220–2. <http://dx.doi.org/10.1177/175114370901000316>
8. Fischer JD. Bronchobiliary fistula: a case report. *Can J Surg*. 1998;41(6):470–2.
9. Eryigit H, Oztas S, Urek S, et al. Management of acquired bronchobiliary fistula: 3 case reports and a literature review. *J Cardiothorac Surg*. 2007;2:1088–52. <http://dx.doi.org/10.1186/1749-8090-2-52>
10. Recommended practices for sponge, sharp, and instrument counts. AORN Recommended Practices Committee. Association of periOperative Registered Nurses. *AORN J*. 1999;70(6):1083–9.

Received: 04-02-2016 Accepted: 23-08-2016