

Another method to maintain positive-pressure ventilation through the Montgomery® T tube

Saroa R, MD, Assistant Professor, Department of Anaesthesia and Critical Care

Singhal S, MS, Associate Professor, Department of ENT

Palta S, MD, Associate Professor, Department of Anaesthesia and Critical Care

Government Medical College and Hospital, Chandigarh, India

Correspondence to: Richa Saroa, e-mail: richajayant@rediffmail.com

Keywords: Montgomery® T tube, positive-pressure ventilation

Abstract

We describe airway management in a patient who had a Montgomery® T tube in situ. The main concern pertaining to these patients is the inadequate depth of anaesthesia and ventilation, in view of loss of volume of air and gases, as well as dilution through the proximal end of the Montgomery® T tube. To circumvent these problems, we describe another method of providing ventilation, through the extraluminal horizontal limb of the Montgomery® T tube by introducing an uncuffed endotracheal tube and minimising the loss of carrier gases to the larynx, together with a review of literature for the same.

© Peer reviewed. (Submitted: 2013-02-18. Accepted: 2013-06-03.) © SASA

South Afr J Anaesth Analg 2013;19(5):274-276

Introduction

The Montgomery® T tube was introduced by William Montgomery in 1965 to provide support to the trachea in laryngotracheoplasty procedures, and is available in sizes of 4.5 mm-16 mm (external diameter), with smooth tapered ends to prevent injury to the tracheal mucous membrane.^{1,2} It is an uncuffed T-shaped silicone tube device with a vertical limb that is inserted into the trachea and a horizontal limb that protrudes through the tracheostomy stoma (Figure 1).

The Montgomery® T tube poses unique anaesthetic challenges, particularly with respect to delivery of the carrier gases and positive-pressure ventilation. These stents are seldom used for long-term positive-pressure ventilation

because of their propensity for displacement and or total loss of airway, as a result of obstruction because of crusting and inspissated mucous plugs. However, short-term positive-pressure ventilation may be required for periodic assessment of the airway in a patient with the Montgomery® T tube in situ. We hereby discuss a method of maintaining ventilation, as well as preventing the dilution of gases (a matter of great concern when induction is carried out) in patients with the Montgomery® T tube in situ.

Case summary

The patient's guardian has consented for the clinical details of the case to be published in the medical journal.

A 15-year-old male patient with a Montgomery® T tube no. 14 in situ was scheduled to undergo airway assessment to decide on removal of the same. The Montgomery® T tube had been inserted six months back for subglottic stenosis following a head injury, resulting in endotracheal intubation in the intensive care unit. There were no reports of any tube displacement or obstruction following its insertion.

The clinical history of the patient was unremarkable. The haematological and biochemical investigations were normal. The patient fasted for eight hours, and oral ranitidine 150 mg, together with alprazolam 0.25 mg, was administered a night before surgery, and early in the




Figure 1: Montgomery® T tubes of different sizes

morning. In the operating room, after the monitors had been attached, glycopyrrolate 0.2 mg and midazolam 1 mg were administered intravenously. Anaesthesia was induced with fentanyl 2 µg/kg and propofol 2 mg/kg in titrated dosages to avoid apnoea. Air and oxygen with fraction of inspired oxygen (FiO₂) 0.6 and sevoflurane (1.5-2%) were maintained in the patient through a face mask, keeping the extraluminal segment of the Montgomery® tube obliterated with the plug.

With the patient on spontaneous respiration, a 5 mm internal diameter uncuffed polyvinyl chloride (PVC) endotracheal tube (ETT) was introduced through the extraluminal limb of the Montgomery® T tube, with the bevel of the tube facing the trachea (Figure 2). The ETT was inserted until resistance was encountered with the tip of the ETT positioned against the Montgomery® T tube wall. The ETT that was introduced through the short limb of the Montgomery® T tube was attached to the anaesthesia machine.

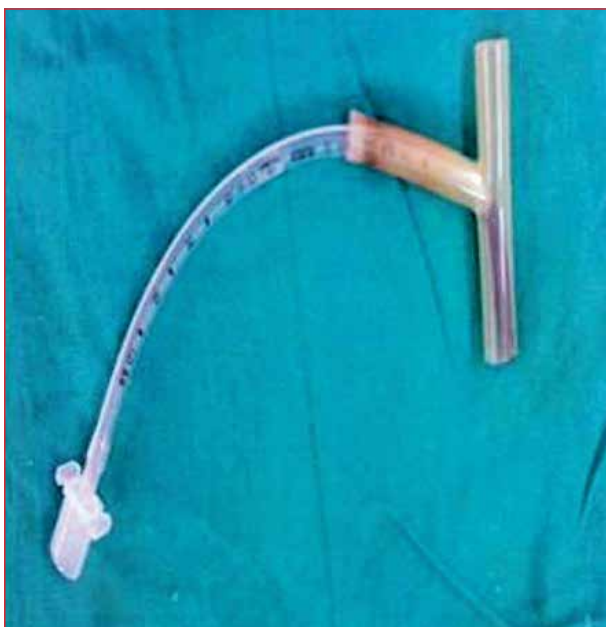

Figure 2: Final position of the distal end of the endotracheal tube through the Montgomery® T tube

Adequacy of ventilation was confirmed by capnography and bilateral auscultation of the chest. After confirming adequate ventilation, neuromuscular blockade was achieved with atracurium 0.3 mg/kg and positive-pressure ventilation was instituted. Direct laryngoscopic assessment through endoscopy was allowed to start, and positive-pressure ventilation was applied manually. The patient was not connected to the mechanical ventilator for fear of high pressure owing to the small diameter of the ETT, and to enable a better feel of the ventilation with our hands. The ETT minimised the escape of carrier gases to the larynx as well, eliminating the need for pharyngeal packing. The procedure lasted for 40 minutes. The haemodynamic and ventilatory parameters of the patient remained within normal

limits throughout the procedure. Upon completion thereof, thorough suctioning was carried out under vision in the oropharynx, and through the upper end of the Montgomery® T tube up to the ETT. Subsequently, the patient was reversed with glycopyrrolate 0.2 mg and neostigmine 2.5 mg. The ETT that was inserted through the short limb was removed once spontaneous breathing was resumed, and the patient was allowed to breathe through a face mask via a tracheal limb, while the short limb was obliterated at the same time. The patient was transferred to the post-anaesthesia care unit and discharged after 48 hours without any complications.

Discussion

Use of airway stents is becoming a common procedure as they can be left in situ for prolonged periods to relieve major airway obstruction for the majority of causes.³ The silicone Montgomery® T tube is a device that is used as a tracheal stent, as well as an airway, after laryngotracheal surgery. Although the Montgomery® T tube serves a dual purpose of acting as a stent and tracheostomy, it poses unique anaesthetic challenges to the anaesthesiologist. It has the disadvantage of not fitting to a standard catheter connector through the side port, and requires modification with a tracheal tube 15 mm connector for attachment to the anaesthesia circuit. Several anaesthetic techniques have been described for Montgomery® T tube insertion.

However, few reports have addressed anaesthetic concerns with regard to the management of patients with a Montgomery® T tube in situ. Guha et al proposed inhalational induction with spontaneous respiration via a face mask.⁴ The success of inhalational induction through the extraluminal limb is unlikely, owing to the entrainment of air during inspiration with the resultant dilution of gases. In the same article, Guha et al proposed a possible method of combined induction through the extratracheal limb and face mask, with high fresh gas flow delivered via the Y-connector into the modified anaesthesia circuit.⁴

Reliable administration of anaesthetic gases and controlled ventilation is troublesome, especially if the ventilation is to be maintained through the extraluminal limb. The escape of the gases to the pharynx through the intraluminal limb leads to both inadequate ventilation and an unreliable depth of anaesthesia. The introduction of a Fogarty catheter or Shiley's embolectomy tube passed upward through the extraluminal limb, with subsequent inflation of the balloon, has been described to isolate the upper and lower segment and facilitate controlled ventilation.¹

Alternatively, the escape may be prevented by the use of pharyngeal packs inserted orally or a laryngeal mask with occluded lumen.^{5,6} However, in the case where airway assessment is mandatory, this might not be possible leading to loss of gases and inadequate depth of anaesthesia. The

placement of an ETT through the intratracheal lumen, with the cuff inflated distal to the Montgomery® T tube, provides positive-pressure ventilation, but would again not allow for airway assessment, if required.⁷ Finally, high-frequency jet ventilation has been employed for ventilation through the extraluminal limb, but it may not be possible at all centres.²

In the present case, the introduction of the endotracheal tube, with the bevel towards the carina, through the extraluminal limb, prevented the escape of gases to the pharynx, thus allowing positive-pressure ventilation, while maintaining adequate depth of anaesthesia at the same time. This procedure can be aptly called a modification to the original technique described by Montgomery, where the upper intraluminal limb of the T tube was blocked by a Fogarty catheter to prevent loss of gases, although it was not suitable for long-term ventilation.¹

Our technique can be extended to similar circumstances, but essential knowledge of relevant internal and external diameters and an appropriate-sized PVC ETT is mandatory, to be inserted through the extraluminal limb of the Montgomery® T tube for adequate ventilation. Increased airway pressure and resistance is a concern because of the narrow calibre of the ETT that is introduced through the extraluminal limb, thereby requiring manual ventilation to prevent excessive pressure. Aspiration is definitely a concern, as with other techniques used for positive-pressure ventilation, and is therefore a potential disadvantage of the abovementioned technique. Even though pharyngeal packing may provide some protection against aspiration, it is pertinent to mention that it is not a foolproof method and care should be taken to provide aspiration prophylaxis to patients.

A similar technique has been described using a flexometallic ETT, introduced into the tracheal limb. However, the smaller internal diameter of the flexometallic tube for the same-sized PVC ETT would add to more resistance theoretically, and may still lead to loss of gases around the intraluminal limb of the tube.⁸

When dealing with patients with the Montgomery® T tube in situ, presenting for either laryngeal or nonlaryngeal surgery in the elective or emergency setup, it is prudent to discuss and formulate the airway management plan with the ear, nose and throat specialist beforehand. An alternative plan must be kept in mind to deal with any unforeseen or unintentional removal, or displacement of the Montgomery® T tube perioperatively. In case of lack of expertise, the safest alternative would be to remove the Montgomery® T tube and insert a cuffed or an armoured endotracheal tube in its place, and to proceed with the surgery.

In conclusion, we recommend the use of an uncuffed, small-sized paediatric PVC ETT, introduced through the extratracheal or extraluminal limb, with the bevel towards the carina, to prevent the escape of gases to the pharynx, and hence facilitate positive-pressure ventilation and maintenance of an adequate depth of anaesthesia owing to non-dilution of the anaesthetic agents.

References

1. Montgomery WW. Manual for care of the Montgomery silicone tracheal T-tube. *Ann Otol Rhinol Laryngol*. 1980;89(4 Pt 5):1-8.
2. Montgomery WW, Montgomery SK. Manual for use of Montgomery laryngeal, tracheal and esophageal prosthesis: update 1990. *Ann Otol Rhinol Laryngol Suppl*. 1990;150:2-28.
3. Filler RM, Forte V, Chait P. Tracheobronchial stenting for the treatment of airway obstruction. *J Pediatr Surg*. 1998;33(2):304-311.
4. Guha A, Mostafa SM, Kendall JB. The Montgomery T-tube: anaesthetic problems and solutions. *Br J Anaesth*. 2001;87(5):787-790.
5. Agrawal S, Payal YS, Sharma JP, et al. Montgomery T-tube: anesthetic management. *J Clin Anesth*. 2007;19(2):135-137.
6. Uchiyama M, Yoshino A. Insertion of the Montgomery T tube. *Anaesthesia*. 1995;50(5):476-477.
7. Wouters KMA, Byreddy R, Gleeson M, Morley AP. New approach to anaesthetising patients at risk of pulmonary aspiration with Montgomery T tube in situ. *Br J Anaesth*. 2008;101(3):354-357.
8. Al- Kaisy AA, Kent AP, Watt JWH. Maintaining ventilation through the Montgomery T tube. *Can J Anesth*. 1997;44(3):340.