

Cervical plexus block for thyroidectomy

IK Kolawole

Consultant Anaesthetist, Department of Anaesthesia, University of Ilorin Teaching Hospital, Ilorin, Nigeria.

GA Rahman

Consultant General Surgeon, Department of Surgery, University of Ilorin Teaching Hospital, Ilorin, Nigeria.

ABSTRACT

Objective: Thyroidectomy is traditionally performed under general anaesthesia with endotracheal intubation. However, cervical plexus block has also been found useful for this operation in some parts of the world. This particular anaesthetic option has never been reported in our environment. The aims of this study were to assess the feasibility, safety, effectiveness and patients' acceptability of bilateral superficial cervical plexus block for thyroidectomy in our hospital. **Design:** This is a prospective study of all consenting adult patients who presented with goiter and had thyroidectomy done in a Nigerian Teaching Hospital, between May 1998 and September 1999. **Setting:** The study was carried out at the University of Ilorin Teaching Hospital, which is a tertiary health institution. **Subjects:** The study included seventeen (17) Patients above the age of 18 years who presented with goiter and had elective thyroidectomy done within the study period. **Outcome Measures/Results:** The 17 patients represented 65% of all those who underwent thyroidectomy in our hospital within the study period. There were 15 females and 2 males, giving a female to male ratio of 7.5:1. The median age of the patients was 44 (range 20-80) years. Types of goiter included 13 simple multinodular or nodular goiters, 3 diffuse toxic goiters and 1 malignant goiter. Sixteen (16) patients had subtotal thyroidectomy, while one had total thyroidectomy. Varying degrees of pressure symptoms during mobilization of the gland, and postural aches were some of the intra-operative problems encountered. These problems were described by the patients as tolerable. Fifteen (88%) of the patients found the anaesthesia satisfactory and would not mind recommending or having the same anaesthetic technique for similar procedure. Two (12%) of the patients expressed dissatisfaction with the anaesthesia and would not want it for similar procedure. In one of the two, the surgery was completed under general anaesthesia with endotracheal intubation when the block was found to be ineffective. The second patient became extremely apprehensive during surgery, although she denied experiencing any significant pain and refused conversion to general anaesthesia. **Conclusion:** Bilateral superficial cervical plexus block is a useful anaesthetic option for thyroidectomy in temperamentally suited patients. Although the number was small, we can conclude that the block is feasible, safe, effective and easy to perform. It was acceptable to our patients.

Key words: Cervical Plexus, Superficial, block, and thyroidectomy.

Thyroidectomy is traditionally performed under general anaesthesia with endotracheal intubation. This in most cases reflects surgeon's and anaesthetist's preference, as local or regional anaesthetic option is rarely offered to patients. However, neither general anaesthesia nor endotracheal intubation is an absolute requirement for thyroidectomy. For selected patients and in certain circumstances, local or regional anaesthesia may be preferred. There are few reports of successful use of local infiltration anaesthesia for thyroidectomy in Nigeria.^{1,2} The indication for use of this anaesthetic option have in most cases been the lack of anaesthetic facilities/or personnel, and surgeon's preference, though with the consent of the patient. Other indications elsewhere in the world are

patient's preference and associated cardiac or pulmonary disease. Cervical plexus block has also been found useful for thyroidectomy in some parts of the world.^{3,5} This particular anaesthetic option has not been reported in this environment.

The aims of the study were:

1. To assess the feasibility, safety and effectiveness of bilateral superficial cervical plexus block for thyroidectomy in our hospital.
2. To assess the level of acceptability of superficial cervical plexus block for thyroidectomy amongst our patients.
3. To assess any associated complications specifically related to the procedure.

Materials and methods

The ethical and research committee of the University of Ilorin Teaching Hospital, Ilorin, approved the study. The study included seventeen (17) patients above the age of eighteen (18)

Correspondence:

Dr IK Kolawole

email: ikolawole@infoweb.com.ng

years who presented with goiter and had elective thyroidectomy done by one of the authors who is a surgeon. Informed consent was obtained from the patients after the authors had explained the procedure to them. Criteria for exclusion from the study included patients' refusal, allergy to local anaesthetic, patients who were excessively anxious and apprehensive, deafness in the patient, recurrent laryngeal nerve palsy, local sepsis in the area of the block, significant upper airway obstruction due to pressure or narrowing of the trachea, and recurrent goiters.

All patients were premedicated with oral diazepam 5-10mg, two hours before being transferred to the theatre. In the pre-operative holding area, the patients were sedated with intravenous midazolam 2mg and pentazocine 15-25mg. This was followed by bilateral superficial cervical plexus block performed by the consultant anaesthetist under aseptic conditions.

Fig. 1: Cutaneous distribution of the cervical plexus

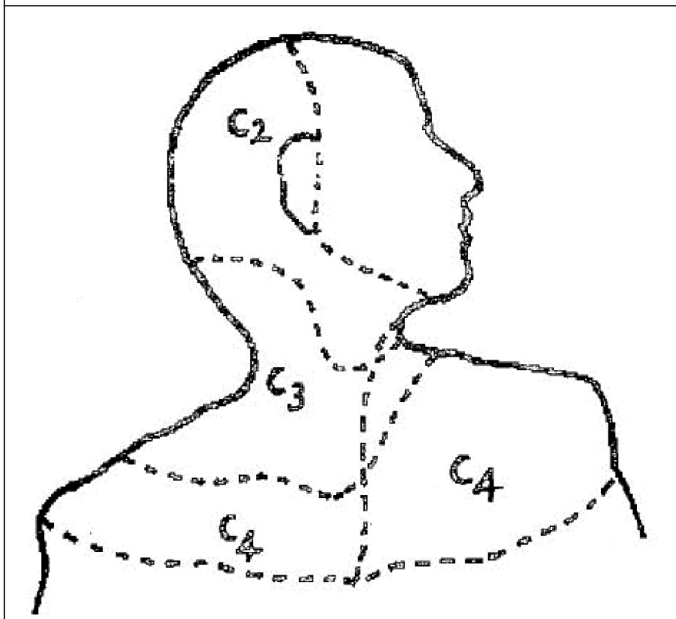


Fig. 2: Superficial Branches of the Cervical Plexus

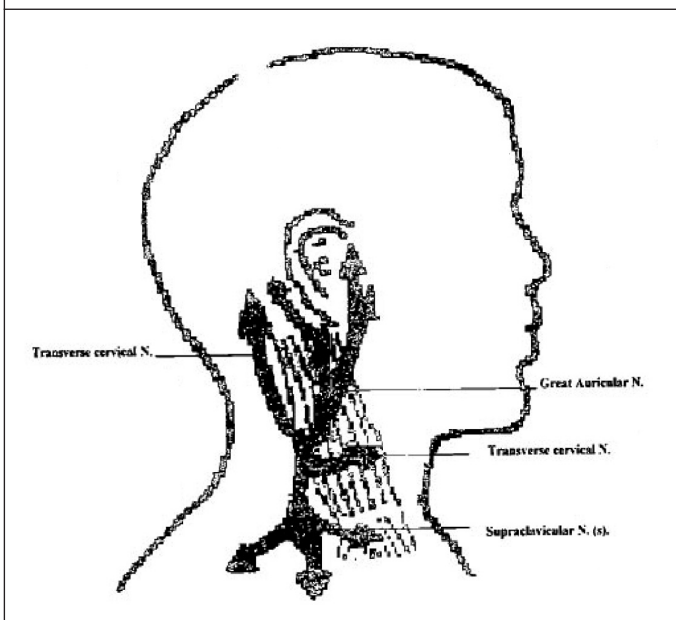
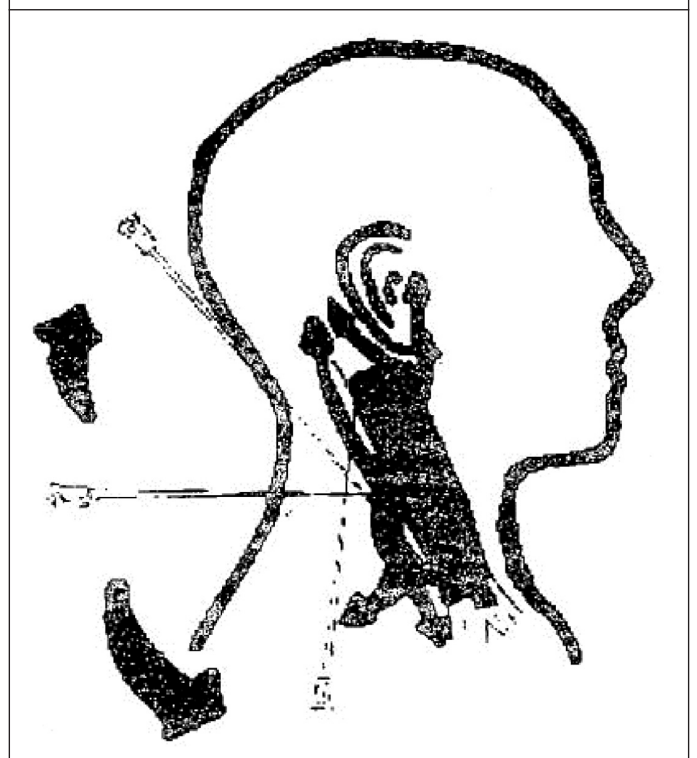


Fig. 3: Needle Placement for Superficial Cervical Plexus Block



Relevant anatomy

The Cervical Plexus is formed from the ventral rami of the first four cervical nerves. The components of the plexus are:

1. The cutaneous (superficial) branches of the plexus
2. The Ansa Cervicalis
3. The Phrenic nerve
4. Contributions to the accessory nerve.
5. Direct muscular branches.

By blocking only the superficial branches of the plexus, (C2, C3, and C4), (Fig 1), the phrenic nerve is spared, while anaesthesia is effected in the neck. The cutaneous (superficial) branches of the plexus are: greater occipital, greater auricular, transverse cervical and supraclavicular nerves. (Fig 2).

Technique of the Block

Superficial Cervical Plexus block: -

The midpoint of the posterior border of the sternomastoid was identified. From this point, 12-15ml of the local anaesthetic (a mixture of 20ml 0.5% bupivacaine + 10ml 2% Lignocaine with adrenaline or 1% Lignocaine with adrenaline), was infiltrated along the border of the muscle 3cm cephalad and caudad (Fig. 3). A further 3-5ml of the solution was also infiltrated superficially above the muscle to block the transverse cervical branch of the plexus. The block was performed on both sides of the neck using a size 21 gauge hypodermic needle.

Superficial cervical plexus block is a field block, requiring all the branches of the plexus to be bathed in local anaesthetic solution. It thus relies on local anaesthetic 'volume' to be effective. Since thyroidectomy is a superficial procedure which do not demand significant muscle relaxation, dilute solutions of local anaesthetic agents like 0.375% bupivacaine or 1.5% lignocaine block may be used to prevent overdosage with the large volume. Where a mixture of 0.5% bupivacaine and 2%

TABLE 1: PATIENTS, AGE, SEX, DIAGNOSIS AND PROCEDURE

S/N	Patient	Age (Yrs)	Sex	Diagnosis	Procedure
1.	OF	25	F	Simple solitary nodular goiter	Subtotal thyroidectomy
2.	OY	32	F	Toxic multinodular goiter	Subtotal thyroidectomy
3.	OE	31	F	Toxic multinodular goiter	Subtotal thyroidectomy
4.	AL	37	F	Simple multinodular goiter	Subtotal thyroidectomy
5.	AB	47	F	Simple multinodular goiter	Subtotal thyroidectomy
6.	AK	42	M	Simple nodular goiter	Subtotal thyroidectomy
7.	AR	40	F	Simple multinodular goiter	Subtotal thyroidectomy
8.	OT	38	F	Simple multinodular goiter	Subtotal thyroidectomy
9.	AJ	38	F	Toxic multinodular goiter	Subtotal thyroidectomy
10.	IA	80	F	Malignant giant goiter	Total thyroidectomy
11.	SO	63	F	Simple multinodular goiter	Subtotal thyroidectomy
12.	SS	35	F	Simple multinodular goiter	Subtotal thyroidectomy
13.	AH	49	F	Simple multinodular goiter	Subtotal thyroidectomy
14.	DO	28	M	Simple multinodular goiter	Subtotal thyroidectomy
15.	MR	20	F	Simple giant multinodular goiter	Subtotal thyroidectomy
16.	GB	75	F	Simple nodular goiter	Subtotal thyroidectomy
17.	AA	30	F	Simple multinodular goiter	Subtotal thyroidectomy

lignocaine was used, the final concentrations of the individual drug will be lower than 0.5% and 2% respectively.

Any local anaesthetic agent suitable for major nerve blocks can be used for superficial cervical plexus block.

Transtracheal block

This block is useful to provide topical anaesthesia to the airway mucosa, supplied by branches of the vagus nerve (i.e. the internal branch of the superior laryngeal nerve, which provides sensation to both surfaces of the epiglottis and laryngeal structures to the level of the vocal cords, and the recurrent laryngeal nerve which provides sensation to the mucosal surface distal to the vocal cords). With the patient's head absolutely straight and the neck extended, the cricoid cartilage was palpated. A 25 gauge needle attached to a syringe containing 4ml of 2% plain lignocaine was inserted in the midline, just above the cricoid, and advanced gently through the cricothyroid membrane. The aspiration of air confirmed the position of the needle tip in the trachea. The patient was then instructed to take a deep breath and then to cough. At peak inspiration, the drug was injected rapidly and the needle withdrawn. The cough would ensure that the local anaesthetic spread to the area above the cords supplied by the internal laryngeal nerve. Transtracheal block was not possible in two of the patients due to a significantly enlarged isthmus lobe of the thyroid gland, which made identification of landmarks difficult.

Intraoperative management

Patients were positioned supine with a shoulder pad to extend the neck, and the head was supported on a head ring. Drapings were applied in such a way to leave a portion above the chin free to facilitate intubation if required, and to allow proper facial aeration and prevent a feeling of suffocation. During surgery, patients were sedated with intermittent intravenous administration of midazolam and pentazocine as required. The doses of these drugs were titrated to ensure a minimally depressed patient who was able to maintain airway independently and responded appropriately to verbal command. The anaesthetist maintained communication with the patient through

out the surgery. The surgeon was aware of the intact swallowing reflex, and the need for gentle manipulation and dissection to minimize traction on the trachea. The pulse rate and oxygen saturation were monitored continuously and the non-invasive blood pressure every 5 minutes, using a Nellcor puritan Bennett five parameter monitor.

Postoperative assessment

At the end of the operation, the duration of the surgery was recorded and the patients were transferred to the recovery ward. A proforma was administered to each patient by a member of the surgical team who was not part of the study during the post-anaesthetic round, about 24 hours after the surgery, to find out if there were postoperative complications specific to the procedure and, the acceptability of the procedure by the patient.

Results

The seventeen (17) patients represented 65% of those who underwent thyroidectomy in our hospital within the study period (May 1998 to Sept. 1999). There were 15 females and 2 males giving a female to male ratio of 7.5:1. The median age of the patients was 44 years, with a range of 20 to 80 years (Table I). Types of goiter included 13 simple multinodular or nodular goiters, three (3) diffuse toxic goiters, and 1 malignant goiter. Sixteen (16) patients had subtotal thyroidectomies, while one had a total thyroidectomy (Table. II). The duration of surgery ranged from 1 hour 10 min. to 3 hours 48 min (mean duration was 2 hours 34 min).

Fifteen (88%) of the patients found the anaesthesia satisfactory and would not mind recommending or having the same anaesthetic technique for a similar procedure. Two (12%) of the patients expressed dissatisfaction with the anaesthesia, and would not want it for a similar procedure. In one of the two, the surgery was completed under general anaesthesia with endotracheal intubation when the block was found to be ineffective. The second patient was probably a product of wrong patient selection. He became extremely apprehensive during the surgery, although he denied experiencing any significant pain and refused conversion to general anaesthesia. Incidentally,

S/N	Patient	Preoperative Sedation	Local Anaesthetic used for Cervical block	Other Intraoperative drugs used
1.	OF	Midazolam 2mg Pentazocine 15mg	Bupivacaine 0.375% 30ml	Midazolam 6mg Pentazocine 20mg
2.	OY	Midazolam 2mg Pentazocine 20mg	Lignocaine 1% with adrenaline 32ml	Midazolam 4mg Pentazocine 40mg
3.	OE	Midazolam 1 mg Pentazocine 5 mg	Lignocaine 1% with adrenaline 32ml	Midazolam 3mg Pentazocine 35mg
4.	AL	Midazolam 1mg Pentazocine 15mg	Lignocaine 1% with adrenaline 34ml	Midazolam 2mg Pentazocine 10m
5.	AB	Midazolam 2mg Pentazocine 15mg	Lignocaine 1% with adrenaline 30ml	Midazolam 3mg Penazocine 20mg
6.	AK	Midazola 1mg Pentazocine 20mg	Bupivacaine 0.5% 20ml + Lignocaine 2% 10ml with adrenaline	Midazolam 2mg Pentazocine 30mg
7.	AR	Midazolam 2mg Pentazocine 10mg	Lignocaine 1% with adrenaline 35ml	Midazolam 3mg Pentazocine 40mg
8.	OT	Midazolam 2mg Pentazocine 25mg	Bupivacaine 0.5% 20ml + Lignocaine 2% 10ml with adrenaline	Midazolam 7mg Pentazocine 35mg
9.	AJ	Midazolam 2mg Pentazocine 20mg	Lignocaine 1% 32ml with adrenaline	Midazolam 5mg Pentazocine 30mg
10.	IA	Midazolam 2mg Pentazocine 10mg	Bupivacaine 0.5% 20ml + Lignocaine 2% 15ml with adrenaline	Midazolam 3mg Pentazocaine 40mg
11.	SO	Midazolam 2mg Pentazocine 25mg	Bupivacaine 0.5% 20ml +Lignocaine 2% with adrenaline 10ml	Atropine 0.8mg Ephedrine 15mg
12.	SS	Midazolam 3mg Pentazocine 20mg	Lignocaine 1% with adrenaline 32ml	Midazolam 6mg Pentazocine 20mg
13.	AH	Midazolam 2mg Pentazocine 20mg	Bupivacaine 0.5% 20ml +Lignocaine 2% with adrenaline 10ml	Midazolam 7mg Pentazocine 65mg
14.		Midazolam 2mg Pentazocine 20mg	Bupivacaine 0.5% 20ml + Lignocaine 2% with adrenaline 10ml	Midazolam 6mg Pentazocine 35mg
15.		Midazolam 2mg Pentazocine 20mg	Lignocaine 1% with adrenaline 36ml	Midazolam 2mg Pentazocine 30mg
16.	GB	Midazolam 2mg Pentazocine 15mg	Lignocaine 1% with adrenaline 35ml	*Conversion GA Midazolam 5mg Pentazocine 60mg
17.	AA	Midazolam 2mg Pentazocine 25mg	Lignocaine 1.5% with adrenaline 32ml	Midazolam 5mg Pentazocine 25mg
				Midazolam 8mg Pentazocine 30mg

S/N	Patient	Age (Yrs)	Sex	Diagnosis	Intraoperative Problems	Post-operative Complication
1.	OF	25	F	Simple solitary nodular goiter	Pressure, Postural aches/discomfort	Nil
2.	OY	32	F	Toxic multinodular goiter	Frequent coughing & spitting	Nil
3.	OE	31	F	Toxic multinodular goiter	Pressure, frequent spitting	Nil
4.	AL	37	F	Simple multinodular goiter	Nil	Nil
5.	AB	47	F	Simple multinodular goiter	Postural body aches	Hoarseness of the voice, mild stridor when asleep. Transient paralysis of left vocal cord
6.	AK	42	M	Simple nodular goiter	Very apprehensive, pressure postural aches	Nil
7.	AR	40	F	Simple multinodular goiter	Pressure, postural aches	Nil
8.	OT	38	F	Simple multinodular goiter	Apprehension, pressure Postural aches	Nil
9.	AJ	38	F	Toxic multinodular goiter	Apprehension, pressure Postural aches	Hypocalcaemia
10.	IA	80	F	Malignant giant goiter	Laryngeal spasm, Hypotension, Bradycardia, Large Blood Loss	Nil
11.	SO	63	F	Simple multinodular goiter	Pressure, minor pain on the left side where the block appeared inadequate	Nil
12.	SS	35	F	Simple multinodular goiter	Postural aches, pressure mild pain towards end of surgery	Nil
13.	AH	49	F	Simple multinodular goiter	Postural aches Desire to void	Nil
14.	DO	28	M	Simple multinodular goiter	Severe pain, Conversion to GA	Nil
15.	MR	20	F	Simple giant multinodular goiter	Pressure, Postural aches	Transient Hoarseness of the voice
16.	GB	75	F	Simple nodular goiter	Pressure, Postural aches	Nil
17.	AA	35	F	Simple multinodular goiter	Pressure, Postural aches	Nil

these two patients were the only males in the series. Varying degrees of pressure symptoms during mobilization of the gland, and postural aches were common intra-operative problems encountered (Table III). These problems were described by the patients as tolerable. The patient with a malignant goiter had transient laryngeal spasm with accompanying arterial desaturation to a SaO_2 of 75%. This responded to administration of 100% oxygen by facemask. The patient was one of the two in whom a transtracheal block was not done because of a significantly enlarged isthmus lobe of the thyroid gland. The patient also suffered intra-operative hypotension, which responded to fluid infusion and ephedrine therapy. Two patients developed clinical features of recurrent laryngeal nerve palsy

in the postoperative period. They were subsequently confirmed by indirect laryngoscopic examination to have left recurrent laryngeal nerve paresis. They both recovered within 6 to 8 weeks of conservative management.

DISCUSSION

It has always been appreciated that thyroidectomy is not very stimulating to patients.⁶ Therefore a deep plane of anaesthesia is not necessary and no significant muscle relaxation is required. This conforms to the superficial nature of a straightforward thyroidectomy. In fact, when the needs for laryngoscopy and endotracheal intubation are removed, the two greatest stimuli in thyroidectomy are skin incision and manipulation of the

gland around the larynx and trachea.

Since the superficial branches are sensory and the remainder of the cervical plexus is motor, a block of the superficial cervical plexus alone has been found adequate for thyroidectomy.^{4,5} The block takes care of the pain of skin incision and the necessary tissue dissection. Superficial cervical plexus block is easier and safer than the combined superficial and deep cervical plexus block which has been used by some other authors.^{3,4} Deep cervical plexus block is often accompanied by at least subtotal phrenic nerve block⁷, which might be dangerous in a technique of bilateral block. Furthermore, the block places the needles near the vertebral artery, which may be affected by the local anaesthetic.^{9,10} The technique of local anaesthetic infiltration has also been used successfully by few authors in Nigeria.^{1,2} However, this technique places a dual responsibility on the surgeon, as he needs to repeat the infiltration many times during surgery. Many surgeons may find this inconvenient and time consuming. Furthermore, The technique may be uncomfortable and not tolerated well by most patients. Compared with superficial cervical plexus block, local infiltration technique runs a risk of using too much drug.

Surgical operation on the neck in an awake patient can cause anxiety, amounting to fear and a feeling of panic, especially when it involves manipulation around the airway. Thorough preoperative psychotherapy, careful patient selection and judicious use of sedative drugs in the perioperative period were relied upon to minimize anxiety in our patients. Apart from anxiolysis, the amnesia provided by midazolam was also desirable for these patients.

The classical thyroidectomy position requires significant neck extension to guarantee optimal surgical access. This puts a considerable strain on the cervical spine and results in varying degrees of discomfort. This, combined with the prolonged immobility on the hard operating table is more than enough to account for the varying degrees of postural aches and pain encountered in a large number of our patients. It is surprising to note that this problem was not highlighted in any of the previous studies.^{4,5} The analgesic effect of pentazocine was relied upon to relieve postural aches and pain in our patients. Since the dose had to be titrated to prevent a deep state of anaesthesia, enough could not be administered to completely prevent the postural discomfort. A trial with non-steroidal anti-inflammatory analgesic (NSAID), like piroxicam, given at the time of premedication may be worthwhile for subsequent cases. Adequate padding of all bony prominences may also help minimize the postural discomfort.

Too much traction on the trachea during surgical manipulation and pressure effect of retractors are bound to stimulate the airway resulting in discomfort, coughing, choking, and even laryngeal spasm. Careful tissue handling, dissection and retraction, as well as gentle mobilization of the thyroid gland, ensured minimal traction and pressure on the trachea during surgery. Several methods are available to obtund airway sensitivity. A few earlier authors have found topical anaesthesia by transtracheal injection of local anaesthetic useful.^{5,11} We also employed transtracheal block for our patients. The fact that we still encountered this problem in our patients could be attributable to the short duration of action of the transtracheal lignocaine due to rapid absorption from the airway mucosa. A repeat of the block has been suggested in a prolonged procedure⁵, although this was not done for any of our patients. An

alternative method for producing anaesthesia of the upper airway is to nebulise 3-4ml of lignocaine 4% through an oxygen facemask. This process takes a longer time to work but is simpler, requires less expertise and may be better tolerated by patients.¹² Although anaesthesia of the upper airway increases the risks of pulmonary aspiration, this was not a significant problem in our patients since they were all fasted elective patients with low risks of vomiting and regurgitation. It is worthy to note that the only patient who had a laryngeal spasm during surgery was not given a transtracheal block due to technical difficulty. This serves to further emphasize the role of the transtracheal block as an important adjunct in superficial cervical plexus block for thyroidectomy.


While regional anaesthesia may not be considered in competition with general anaesthesia, the technique has become a reasonable alternative in a number of surgical procedures. We now know that there are many patients for whom a correctly chosen and well-managed regional technique has much to offer, especially if the anaesthetist is prepared to combine it with sedation. The technique of combining local anaesthesia with sedation has been referred to as sedoanalgesia¹³ or conscious sedation.¹⁴ This is a form of monitored anaesthesia care which ensures a level of sedation that retains the patient's ability to maintain an airway independently and continuously, and to respond appropriately to physical stimulation and verbal commands.¹⁵ Preservation of consciousness is a desirable end in itself for the rare patient who is terrified of being made unconscious. The technique allows the patient to be alert and able to warn the surgeon of any trespass on the recurrent laryngeal nerve. Hoarseness, crowing or respiratory obstruction during the operation provide early signs which may suggest encroachment on the integrity of the recurrent laryngeal nerve. However two of our patients developed features of recurrent laryngeal nerve palsy postoperatively, even though none of them demonstrated an obvious feature of nerve damage during the operation. We believe the transient nature of the dysfunction would suggest a probable inflammatory reaction mainly after the surgery.

The duration of surgery appeared long in some of the patients. This is a reflection not necessarily of the quality of anaesthesia, but of the need to ensure gentleness in tissue handling and dissection, and manipulation of the gland in an awake patient, especially in those with huge goitres with retrosternal extension. Fortunately the duration of the local anaesthetic agents used was long enough to cover the extended period of surgery as we did not need to supplement the anaesthesia in any of the patients. It is however not unlikely that residual analgesic effect of the narcotic drugs used for the sedation may have augmented the residual cutaneous analgesic effect of the local anaesthetic to ensure pain relief to the end of the procedure.

Finally, we wish to conclude that superficial cervical plexus block is well suited for thyroidectomy. The technique is simple, safe, effective and cheap when compared to general anaesthesia, and patients' acceptability as shown by our study, was satisfactory. The overall quality of operating condition as assessed by the surgeon was satisfactory. Careful patient selection is important to exclude those that are temperamentally unsuitable. The role of adequate sedation to relieve fear and anxiety and minimize the discomfort caused by prolonged immobility on hard operating table cannot be overemphasized. Gentle

execution of the surgical procedure is also essential to minimize unnecessary pressure effects and traction on the trachea.

References

1. Ajao OG: Thyroidectomy under local anaesthesia. *Tropical Doctor*. 1979; 9:73-75.
2. Umunna J.I: Thyroidectomy in a rural private practice. *Nig. Med. Practitioner*. 1988; 16:121-124.
3. Fernandez FH: Cervical plexus block anaesthesia in thyroidectomy. *Int. Surg.* 1984; 69:309-311.
4. Saxe AW, Brown E and Harmburger SW: Thyroid and Parathyroid surgery performed with patient under regional anaesthesia. *Surgery* 1988; 102:415-420.
5. Klein SM, Greengrass RA, Knudsen N, Leight G and Warner DS: Regional anaesthesia for thyroidectomy in two patients with Amiodarone-induced Hyperthyroidism. *Anesth. Analg.* 1997; 85: 222-224.
6. Christoperson R. Anaesthesia for endocrine surgery: In Rogers. MC, Covino. B.G, Tinker. JH and Longnecker. DE (eds). *Principles and Practice of Anesthesiology*. Mosby- Year Book. 1993; 2:2038-2048.
7. Castresana MR, Masters RD, Castresana EJ, Stefansson S, Shaker. IJ and Newman. WH: Incidence and clinical significance of hemidiaphragmatic paresis in patients undergoing carotid endarterectomy during cervical plexus block anaesthesia. *J. Neurosurg Anesthesiol.* 1994; 6:21-23.
8. Kozody R, Ready LB, Barsa JE and Murphy TM: Dose requirements of local anaesthesia to produce grand mal seizure during stellate ganglion block. *Can. Anaesth. Soc. J.* 1982; 29:489-491.
9. Norris D, Klahsen A and Milne B: Delayed bilateral spinal anaesthesia following interscalene brachial plexus block. *Can J. Anaesth.* 1996; 43:303-305.
10. Scammell SJ: Inadvertent epidural anaesthesia as a complication of interscalene brachial plexus block. *Anaesth. Intensive Care.* 1979;7:56-57.
11. Cunningham IGE and Lee YK: The management of solitary thyroid nodule under local anaesthesia *Aust. NZJ. Surg.* 1975; 45:285-289.
12. Turner DAB: Emergency anaesthesia In: Aitkenhead AR and Smith G. (eds). *Textbook of Anaesthesia 2nd ed.* Longman Group UK Ltd 1990; 527-539.
13. Birch BRP, Anson KM and Miller RA: Sedoanalgesia in Urology: a safe, cost effective alternative to general analgesia. A review of 1020 cases. *Br. J Urol.* 1990; 66:342 B350.
14. Scamman FL, Klein SL and Choi WW: Conscious sedation for procedures under local or topical anaesthesia. *Ann Otol Rhinol Laryngol* 1985;94:21-24.
15. Chung F. Which is the best anaesthetic technique. Symposium on outpatient anaesthesia. *Can J. Anaesth.* 1991;38:880-894. 

SASA Golf Day

Venue:

Randpark Golf Club (Windsor Course)

Date:

15 March 2004

For further information contact:

Andrew Thomas on 082 604 5038 or

Renni Rouncivell on 082 441 6904

!! Great prizes to be won !!