

CLINICAL MANIFESTATIONS IN SHEEP WITH PLASTIC BAGS IN THE RUMEN

OTSYINA^{1*}, H. R., NGUHIU-MWANGI², J. MOGOA², EGM, MBUTHIA³, P. G. & OGARA⁴, W.O.

(¹School of Veterinary Medicine, College of Basic and Applied Sciences, University of Ghana, Legon; ²Department of Clinical Studies, Faculty of Veterinary Medicine, University of Nairobi, Kenya; ³Department of Veterinary Pathology, Microbiology and Parasitology, Faculty of Veterinary Medicine, University of Nairobi, Kenya; ⁴Department of Public Health, Pharmacology and Toxicology, Faculty of Veterinary Medicine, University of Nairobi, Kenya)
*Corresponding author's email: rhotsyina@ug.edu.gh /hotsyina64@yahoo.com

Abstract

Sixteen 1-year-old castrate Dorper sheep were used for the study. The animals were divided into four groups of four animals (n = 4). Three groups were implanted with 129 g, 258 g and 387 g of thin plastic bags into the rumen through rumenotomy, while the fourth group was subjected to rumenotomy without implanting plastic bags, and served as control. All the animals were monitored daily for 6 weeks following implantation. Presence of plastic bags in the rumen was characterized by anorexia, severe depression, discomfort, dehydration, firmness and asymmetrical distension of the abdomen, ruminal hypomotility and diarrhoea with intermittent constipation, weight loss, terminal recumbency and death. Severity of these clinical manifestations increased with increased quantities of plastic bags and their duration in the rumen. Sheep implanted with 258 g and 387 g lost 7.8 per cent and 14.2 per cent of their initial mean body weight, respectively, by the end of 6 weeks. Presence of plastic bags in the rumen could interfere with digestion, with gradual loss in body weight, productivity and occasional mortality. Plastic bags in the rumen should be considered as a differential diagnosis in sheep presenting the observed clinical signs, especially in urban and peri-urban areas.

Introduction

Sheep contribute to food security, reduction in poverty, improved soil fertility for crop production and overall improvement of livelihoods in low income households, particularly in developing countries (Lebbie, 2004). Poor health is a major constraint to small ruminant production under the traditional smallholder production systems, in which animals mainly roam and seek their own feed (Devendra, 1999). Roaming and scavenging for feed expose the animals to many health hazards including ingestion and accumulation of indigestible foreign materials in the rumen (Remi-Adewunmi, Gyang & Osunowd, 2004). The rumen is the largest compartment of the fore-stomachs of sheep (Radostitis *et al.*,

2009). Over 80 per cent of the energy supply for sheep is obtained through fermentation of feed materials in the rumen (Randall, Burgren & French, 2002). When the process of fermentation and absorption of volatile fatty acids is interfered with as a result of accumulation of indigestible foreign bodies in the rumen, the animal is deprived of valuable nutrients for its survival (Igbokwe, Kolo & Egwu, 2003).

Impaction of the rumen resulting from indigestible foreign bodies is one of the common causes of gastrointestinal disorders in sheep and the root cause of various problems in different organs of the animal (Radostitis *et al.*, 2009). Presence of indigestible foreign bodies in the rumen compromises ruminal space and leads to

many complications depending on the nature of the foreign body (Calfee & Manning, 2002). A number of factors have been implicated as risk factors for ingestion and accumulation of indigestible foreign materials in the rumen of sheep. These include starvation during long periods of feed scarcity (Igbokwe *et al.*, 2003), mineral and nutritional deficiencies (Radostitis *et al.*, 2009), depraved appetite (Radostitis *et al.*, 2009; Vijaya, Reddy & Sasikala, 2012) and increased environmental pollution with non-biodegradable materials, which prevail in the developing world (Ghurashi *et al.*, 2009).

Clinical signs of indigestible foreign body impaction of the rumen of small ruminants vary widely from mild indigestion to life threatening systemic signs (Gyang, 1991). Some reported clinical presentations, associated with indigestible rumen foreign bodies, include anorexia, depression, reduced milk yield, distension of the rumen, absence of ruminal motility and defaecation, hypoglycaemia and reduced rate of fattening (Igbokwe *et al.*, 2003; Remi-Adewunmi *et al.*, 2004; Vanitha *et al.*, 2010; Vijaya *et al.*, 2012). However, the types and quantities of foreign bodies, degree of obstruction, as well as their duration in the rumen in relation to the observed clinical effects, are not documented. There has not been any reported comparison of clinical manifestations in sheep, from natural ingestion or experimental implantation of plastic bags.

Studies on waste generation have shown that plastic bags or polyethylene bags are the largest component of solid waste generated, especially in urban and peri-urban areas, and, hence, the most prevalent in polluting pastures and grazing areas (NEMA, 2003; Mangizvo, 2012). Thus, they are the most commonly ingested foreign bodies found in the rumen of sheep (Roman & Hiwot, 2010; Omid *et al.*, 2012; Sileshi *et al.*, 2013, Otsyina *et al.*, 2014; 2015). However, effect of the presence of plastic bags in the rumen on the physiological and nutritional aspects of sheep has not been fully elucidated and remains largely speculative. Most cases of plastic materials in the rumen of sheep are subclinical, only

being encountered as incidental findings at necropsy examination or at slaughter (Hailat *et al.*, 1998; Otsyina *et al.*, 2015). The study reports on the clinical manifestations in sheep experimentally implanted with plastic bags into their rumen for a period of 6 weeks.

Experimental

The experimental animals included 16 one-year-old castrated Dorper sheep. The sheep had a mean body weight of 26.8 ± 0.3 kg with body condition score of 3.5 ± 0.5 (on a scale of 1-5). The animals were housed in groups of four for the whole period of the experiment and allowed 6 weeks to acclimatize to the environment and feed. They were fed on chopped Rhodes grass hay and supplemented with commercially produced small stock concentrate meal (UNGA® AFYA Meal, UNGA Farm Care Ltd, Nairobi, Kenya). Feed and drinking water were provided *ad libitum*. They were treated against endoparasites with 2.5 per cent Albendazole (Alfabas® Norbrook, Kenya) administered at a dose rate of 4 ml/kg of body weight and ectoparasites with 1 per cent Ivermectin at a dose rate of 1 ml/50 kg of body weight. All the animals were administered 20 per cent injectable Oxytetracycline HCl (Alamycin LA 20®, Norbrook, Ireland) intramuscularly, at a dosage of 20 mg/10 kg of body weight as a prophylactic measure against transportation stress and bacterial infection. The animals were subjected to routine physical examination over the acclimatization period.

The animals were assigned to four experimental groups ($n = 4$), using stratified random sampling on the basis of weight of the animals, such that the mean weight of animals in each of the experimental groups was not statistically different. The four groups of sheep were designated SE1, SE2, SE3 and SC4. Three groups (SE1, SE2 and SE3) were implanted with 129 g, 258 g and 387 g of plastic bags, respectively, into the rumen. Implantation of the plastic bags into the rumen was done through rumenotomy as previously described by Hendrickson (2007). The fourth group (SC4) served as control on which rumenotomy was done but no plastic bags

were implanted. Both test and control sheep were monitored daily for a period of 6 weeks (42 days), and all the observed clinical manifestations were recorded.

Results

Clinical manifestations

Clinical manifestations in sheep implanted with 129 g, 258 g and 387 g of plastic bags into the rumen are presented in Tables 1–3. The temperature, respiratory and heart rates remained within normal range in all the animals, except for those that died during the period of the experiment.

Sheep implanted with 129 g did not show distension or firmness of the abdomen. They had initial inappetence but their appetite significantly improved 2 weeks after implantation, with feed and water intake being restored to pre-implantation levels from week 3 onwards. They were not depressed or dehydrated and their ruminal movements remained 2 - 3 per min throughout the study period as compared to the control. Sheep implanted with 129 g also retained normal pelleted faeces similar to the control throughout the study period. They also retained their body weight and did not regurgitate any of the implanted plastic bags (Table 1).

However, the sheep implanted with 258 g plastic bags had distended abdomen with firmness on the left flank. Reduced appetite, as well as reduced water intake, were observed in all sheep in this group. They fed scantily, with little water intake, occasionally. Severe depression, dehydration, rough hair coat, reduced ruminal movements (1-2 per min) and severe weight loss were observed in all the animals implanted with 258 g of plastic bags. They also showed occasional grinding of the teeth with salivation, and regurgitation of some of the implanted plastic bags (Table 2).

The sheep implanted with 387 g plastic bags also had distended abdomen with firmness on the left flank but this was more severe than those implanted with 258 g. Feed as well as water intake were markedly reduced in this group of sheep, and this trend continued over the entire

period of the study. Diarrhoea with intermittent constipation was observed in three of four sheep in the group implanted with 387 g, while the fourth sheep had no faeces after day 15, following implantation of plastic bags. Persistent grinding of teeth and increased foamy saliva were observed in all the sheep implanted with 387 g plastic bags. These animals also showed severe weight loss and pale mucous membranes. They occasionally regurgitated some of the implanted plastic bags (Table 3).

Effect of plastic bags in the rumen on body weight

Mean body weights of sheep implanted with varying quantities of plastic bags into the rumen over the 6 week period as well as the control are presented in Fig. 1. There was an initial weight loss for all the groups of sheep in the first week. Mean body weight of the control increased by 1.8 kg while those implanted with 129 g increased by 0.2 kg. The sheep implanted with 258 g and 387 g had their mean body weights reduced from the initial weight of 26.8 kg to 24.7 kg (-2.1 kg) and 23.0 kg (-3.8 kg), respectively, at 6 weeks. Significant differences were observed between the mean body weight of sheep in the control group and those implanted with 258 g ($P < 0.001$) and 387 g ($P < 0.001$) of plastic bags. Mean body weight of sheep implanted with 258 g was also significantly ($P < 0.01$) higher than that of sheep implanted with 387 g of plastic bags.

Discussion

Normal body temperature, respiratory and heart rates of both sheep implanted with various quantities of plastic bags into the rumen observed in the current study is consistent with previous findings in small ruminants impacted with ingested indigestible rumen foreign bodies (Ghurashi *et al.*, 2009; Mozaffari, Olomi & Vosouh, 2009; Debaris & Mousami, 2010; Pitroda *et al.*, 2010; Raoofi *et al.*, 2012). Similar findings have also been reported in cattle (Suthar *et al.*, 2011) and buffaloes (Boodur, 2010). Presence of foreign bodies in the rumen does not

appear to exert significant pressure on the diaphragm to interfere with respiration or heart functioning.

The asymmetrical distension of the abdomen with firmness on the left side as observed in all sheep is attributed to rumen impaction with the implanted plastic bags. This is in agreement with previous reports in cases of rumen impaction (Igbokwe *et al.*, 2003; Bakhiet, 2008; Mozaffari *et al.*, 2009; Debaris & Mousami, 2010). The pale mucous membranes observed in animals implanted with higher quantities of plastic bags may be due to interference with rumen microbial activity and mineral imbalance, thus, influencing vitamin B12 production, which could affect haemoglobin production and result in anaemia.

Reduced feed intake and inappetence observed in sheep implanted with 258 g and 387 g of plastic bags is similar to previous findings in ruminants with indigestible foreign bodies in the rumen (Igbokwe *et al.*, 2003; Baillie & Anzuino, 2006; Ghurashi *et al.*, 2009; Debaris & Mousami, 2010). Factors that determine feed intake by ruminants are related to the capacity of the gastro-intestinal tract, digestibility of the feed and the rate of passage through the gastro-intestinal tract (Conrad, 1966). Intake of roughages is also reported to be related to the amount of fatty acid production in the rumen in ruminants (Blaxter, Wainman & Wilson, 1961). The presence of plastic bags in the rumen may have hindered effective fermentation and functioning of the rumen microflora (Radostitis *et al.*, 2009), thus, reducing feed intake. In addition, the extent of stretching of the ruminal wall and the reduced ruminal motility due to the presence of 258 g and 387 g of plastic bags in the rumen may have stimulated the hypothalamus and satiety centre leading to loss of appetite or inappetence (Haupt & Reece, 2004; Mozaffari *et al.*, 2009).

The dehydration observed in the current study concurs with previous findings in sheep (Abdullahi, Usman & Mshelia, 1984; Igbokwe *et al.*, 2003) and goats (Debaris & Mousami, 2010) whose rumens were impacted with indigestible foreign bodies. The dehydration may have resulted from reduced water intake and

possibly sequestration of fluid in the forestomach due to the obstructive effect of the impacted plastic bags in the rumen as well as stress. Drinking is associated with feed intake (Rossi & Scharrer, 1994), therefore, reduction in feed intake would also lead to decreased water intake, hence, the dehydration observed.

Severe depression, persistent grinding of teeth, arching of the back, rigidity of the limbs and reluctance to move suggested discomfort which could possibly have been due to pain in the abdomen. Such observations have been reported in ruminants with rumen impaction (Igbokwe *et al.*, 2003; Reddy *et al.*, 2004; Radostitis *et al.*, 2009; Debaris & Mousami, 2010). It is possible that impaction and distension of the rumen with the implanted plastic bags resulted in stretching of the ruminal wall causing pain, hence, the signs of discomfort. The persistent grinding of teeth seen in these animals supports this position. The foamy saliva observed in animals implanted with 258 g and 387 g of plastic bags may be a consequence of the persistent grinding of teeth as a result of the pain in the rumen, this has not been previously reported in sheep.

The change in character of faecal materials with intermittent diarrhoea and constipation has been reported previously in sheep and goats with indigestible rumen foreign bodies (Igbokwe *et al.*, 2003; Debaris & Mousami, 2010). These findings may have resulted from irritation and enteritis, probably caused by chemical irritants released from the implanted plastic bags or due to hepatic complications, leading to a syndrome that caused both diarrhoea and constipation (Radostitis *et al.*, 2009). Constipation and dry pelleted faeces could also be attributed to reduced or lack of water intake, hence, dry contents in the colon.

Ruminal hypomotility of 1 - 2 weak contractions per min is consistent with ruminants having rumen impaction (Igbokwe *et al.*, 2003; Reddy *et al.*, 2004). The hypomotility of the rumen may have been caused by either a reduction in excitable drive to the gastric centres or an increase in inhibitory inputs (Grunberg & Cons-

table, 2009). Inhibitory inputs to the gastric centres can be caused by excessive distension of the rumen, as well as some degree of hypocalcaemia (Daniel, 1983). Excessive distension of the rumen was a main feature of sheep implanted with 258 g and 387 g of plastic bags, and may have resulted in fatigue of rumen wall musculature, hence, the hypomotility and reduced strength of contractions.

Loss of body weight in sheep implanted with quantities of plastic bags in the current study is corroborated by reports of Igbokwe *et al.* (2003), Ghurashi *et al.* (2009), Mozaffari *et al.* (2009) and Debaris & Mousami (2010). However, these authors did not report on the quantities of foreign bodies or the duration of their presence in the rumen. The weight loss in sheep in the current study can be attributed to drastic reduction in feed and water intake leading to reduction of fermentable ingesta in the rumen and possible disturbances in microbial fermentation and reduced fatty acid production and absorption (Randall *et al.*, 2002). Loss of body water as well as reduction in feed intake, is associated with weight loss (Abdalla, Salwa & Yahia, 2010). The higher weight loss with increased quantities of plastic bags in the rumen over time suggests greater interference with fermentative and physiological activities in the rumen.

Conclusion

Results of the current study show that presence of plastic bags in the rumen of sheep is charac-

terized by anorexia, depression, reduced feed and water intake, abdominal distension, ruminal hypomotility, lack of rumination and weight loss. Furthermore, these animals showed dehydration and altered faecal characteristics, with some animals having dry hard and pelleted faeces, or loose pasty or watery faeces. Other clinical signs included grinding of teeth and arched back, recumbency and death. Severity of the clinical symptoms, however, depended on the degree of impaction, and quantity and duration of plastic bags in the rumen. These have implications on overall production and productivity of the affected animal. It is recommended that plastic bags in the rumen of sheep be considered as a differential diagnosis in sheep presenting with the aforementioned clinical manifestations, especially in urban and peri-urban areas.

Acknowledgment

The authors are grateful to Transdisciplinary Training for Resource Efficiency and Climate Change Adaptation in Africa (TRECCAfrica) and the University of Ghana for providing the funds for this work, the research assistants who assisted in data collection and the University of Nairobi for providing structures and equipment for the work.

TABLE 1*Clinical findings in sheep implanted with 129 g of plastic bags into the rumen for 6 weeks*

<i>Parameters</i>	<i>Clinical observations / Duration of implantation</i>					
	<i>Week 1</i>	<i>Week 2</i>	<i>Week 3</i>	<i>Week 4</i>	<i>Week 5</i>	<i>Week 6</i>
General body condition	1	1	1	1	1	1
Abdominal distension	1	1	1	1	1	1
Mucous membrane colour	0	0	0	0	0	0
Demeanor	0	0	0	0	0	0
Conformation	0	0	0	0	0	0
Gait	0	0	0	0	0	0
Appetite	1	1	0	0	0	0
Water intake	0	0	0	0	0	0
Dehydration	0	0	0	0	0	0
Rumen motility/min	2 - 3	2 - 3	2 - 3	2 - 3	2 - 3	2 - 3
Rumen consistency	0	0	0	0	0	0
Defaecation	1	1	1	1	1	1
Character of faeces	0	0	0	0	0	0
Appearance of hair coat	1	1	1	1	1	1
Grinding of teeth	0	0	0	0	0	0
Foamy saliva	0	0	0	0	0	0
Regurgitation of plastic bags	0	0	0	0	0	0

Key

General body condition: Good=1, fair =2, poor =3, very poor =4; Abdominal distension: none =0, moderate =1, Severe =2; Mucous membrane colour: normal =0, mildly pale =2, pale =3; Demeanor: bright/alert =0, slightly depressed =1, depressed =2, severely depressed =3; Conformation: normal =0, slightly ached back =1, ached back =2; Gait: normal =0, ataxia =1; Appetite: normal =0, moderately reduced =1, reduced =2, markedly reduced =3, anorexia =4; Water intake: normal =0, reduced =1, markedly reduced =2; Dehydration: none =0, slight =1, moderate =2, marked =3; Rumen consistency: doughy =0, firm =1, very firm =2; Defaecation: present =1, occasional =2, absent =3; Character of faeces: normal pellets =0, hard pellets =1, loose =2, pasty =3, diarrhoea =4, no faeces =5; Appearance of hair coat: glossy =1, rough =2; Grinding of teeth: absent =0, occasional =1, continuous =2; Foamy saliva: absent =0, present =1; Regurgitation of plastics bags: absent =0, present =1.

TABLE 2*Clinical findings in sheep implanted with 258 g of plastic bags into the rumen for 6 weeks*

<i>Parameters</i>	<i>Clinical observations / Duration of implantation</i>					
	<i>Week 1</i>	<i>Week 2</i>	<i>Week 3</i>	<i>Week 4</i>	<i>Week 5</i>	<i>Week 6</i>
General body condition	1	2	2	2	2	2
Abdominal distension	2	2	2	2	2	2
Mucous membrane colour	0	1	1	1	1	1
Demeanor	1	2	2	2	1	1
Conformation	1	1	1	1	1	1
Gait	0	0	1	1	1	1
Appetite	3	3	3	3	2	2
Water intake	2	2	2	1	1	1
Dehydration	1	2	2	2	2	2
Rumen motility/min	1-2	1-2	1-2	1-2	1-2	1-2
Rumen consistency	0	1	1	1	1	1
Defaecation	1	2	3	2	2	2
Character of faeces	0	3	5	1	1	3
Appearance of hair coat	1	2	2	2	2	2
Grinding of teeth	0	1	2	2	1	1
Foamy saliva	0	1	1	1	1	1
Regurgitation of plastic bags	0	0	1	1	1	1

Key

General body condition: Good = 1, fair = 2, poor = 3, very poor = 4; Abdominal distension: none = 0, moderate = 1, Severe = 2; Mucous membrane colour: normal = 0, mildly pale = 2, pale = 3; Demeanor: bright/alert = 0, slightly depressed = 1, depressed = 2, severely depressed = 3; Conformation: normal = 0, slightly ached back = 1, ached back = 2; Gait: normal = 0, ataxia = 1; Appetite: normal = 0, moderately reduced = 1, reduced = 2, markedly reduced = 3, anorexia = 4; Water intake: normal = 0, reduced = 1, markedly reduced = 2; Dehydration: none = 0, slight = 1, moderate = 2, marked = 3; Rumen consistency: doughy = 0, firm = 1, very firm = 2; Defaecation: present = 1, occasional = 2, absent = 3; Character of faeces: normal pellets = 0, hard pellets = 1, loose = 2, pasty = 3, diarrhoea = 4, no faeces = 5; Appearance of hair coat: glossy = 1, rough = 2; Grinding of teeth: absent = 0, occasional = 1, continuous = 2; Foamy saliva: absent = 0, present = 1; Regurgitation of plastics bags: absent = 0, present = 1.

TABLE 3*Clinical findings in sheep implanted with 387 g of plastic bags into the rumen for 6 weeks*

<i>Parameters</i>	<i>Clinical observations / Duration of implantation</i>					
	<i>Week 1</i>	<i>Week 2</i>	<i>Week 3</i>	<i>Week 4</i>	<i>Week 5</i>	<i>Week 6</i>
General body condition	1	2	2	2	3	3
Abdominal distension	2	2	2	2	2	2
Mucous membrane colour	0	1	2	2	2	2
Demeanor	3	3	3	3	3	3
Conformation	2	2	2	2	2	2
Gait	1	1	1	1	1	1
Appetite	3	3	3	3	3	3
Water intake	0	2	2	2	1	1
Dehydration	0	2	3	3	3	3
Rumen motility/min	1-2	1-2	1-2	1-2	1-2	1-2
Rumen consistency	2	2	2	2	2	2
Defaecation	2	2	3	3	2	2
Character of faeces	0	4	5	5	1	1
Appearance of hair coat	1	2	2	2	2	2
Grinding of teeth	1	2	2	2	2	2
Foamy saliva	1	1	1	1	1	1
Regurgitation of plastic bags	1	1	1	1	1	1

Key

General body condition: Good = 1, fair = 2, poor = 3, very poor = 4; Abdominal distension: none = 0, moderate = 1, Severe = 2; Mucous membrane colour: normal = 0, mildly pale = 2, pale = 3; Demeanor: bright/alert = 0, slightly depressed = 1, depressed = 2, severely depressed = 3; Conformation: normal = 0, slightly ached back = 1, ached back = 2; Gait: normal = 0, ataxia = 1; Appetite: normal = 0, moderately reduced = 1, reduced = 2, markedly reduced = 3, anorexia = 4; Water intake: normal = 0, reduced = 1, markedly reduced = 2; Dehydration: none = 0, slight = 1, moderate = 2, marked = 3; Rumen consistency: doughy = 0, firm = 1, very firm = 2; Defaecation: present = 1, occasional = 2, absent = 3; Character of faeces: normal pellets = 0, hard pellets = 1, loose = 2, pasty = 3, diarrhoea = 4, no faeces = 5; Appearance of hair coat: glossy = 1, rough = 2; Grinding of teeth: absent = 0, Occasional = 1, Continuous = 2; Foamy saliva: absent = 0, present = 1; Regurgitation of plastics bags: absent = 0, present = 1.

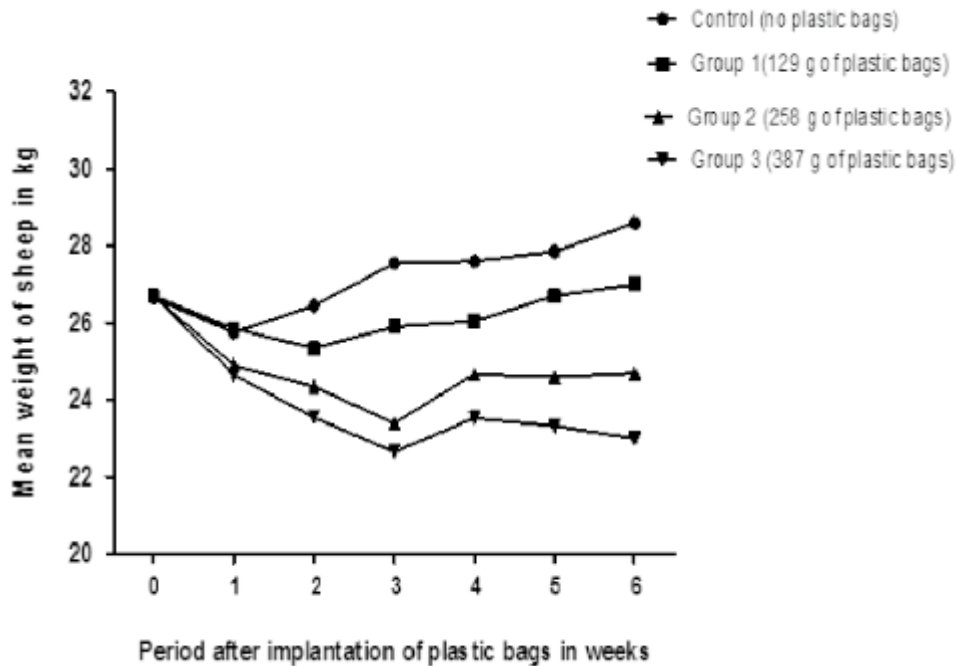


Fig. 1. Mean weights of control sheep and sheep ($n=4$) implanted with 129 g, 258 g and 387 g of plastic bags into the rumen for a period of 6 weeks.

References

- ABDALLA, M.A., SALWA, A.E, & YAHIA, M.H. (2010) Effect of state of hydration on body weight, blood constituents and urine excretion in Nubian goats (*Capra hircus*). *World Journal of Agricultural Sciences* **6** (2), 178-188.
- ABDULLAHI, U.S., USMAN, G.S.H., & MSHELIA, T.A. (1984) Impaction of the rumen with indigestible garbage in cattle and sheep reared within urban and sub-urban environment. *Nigerian Veterinary Journal* **13**, 89-95.
- BAILLIE, S & ANZUINO, A. (2006) Hairball as a cause of anorexia in angora goats. *Goat Veterinary Society Journal* **22**, 53-55.
- BAKHJET, A. O. (2008) Studies on the rumen pathology of Sudanese desert sheep in slaughter house. *Scientific Research and Essay* **3** (7), 294-298.
- BLAXTER, K.L., WAINMAN, F. W & WILSON, R.S. (1961) The regulation of feed intake by sheep, *Animal Production* **3**, 51.
- BOODUR, P., SHIVAPRAKASH, B., KASARALIKAR, V.R. & DILIPKUMAR, D. (2010) Rumen impaction in bovines with indigestible foreign bodies and its surgical and therapeutic management. *Intas Polivet* **2** (II), 184-188.
- CALFEE, T & MANNING, T. O. (2002) Non-healing subcutaneous wound in the cats and proposed in the surgical management techniques. *Clinical Techniques. Small Animal Practice* **17** (4), 167-167.
- CONRAD, H.R. (1966) Symposium on factors affecting the voluntary intake of herbage by ruminants: Physiological and physical factors limiting feed intake. *Journal of Animal Science* **25**, 227-235.

- DANIEL, R.C.W (1983) Motility of rumen and abomasum during hypocalcemia. *Canadian Journal of Comparative Medicine* **47**, 276–80.
- DEVENDRA, C. (1999) Goats: Challenges for increased productivity and improved livelihoods *Outlook on Agriculture* **28** (4), 215–226.
- DEBARIS, J. & MOUSAMI, J. (2010). Non Metallic Foreign Body Syndrome in a Garole ewe. *Intas Polivet*, **2** (II), 253-255.
- GYANG, E.O. (1991) *Introduction to Large Animals Surgery*. Ahmadu Bello University Press, Zaria, Nigeria. 120–125 pp.
- GHURASHI, M.A H., SERI, H I., BAKHEIT, A.H & ASHWAG, E.A.M. (2009) Effect of surgical removal of foreign body from goat's rumen with special reference to the prevalence of foreign body in goats in Southern Dafur. *Australian Journal of Basic and Applied Science* **3**(2), 664-668.
- GRUNBERG, W & CONSTABLE, P.D. (2009) Function and dysfunction of the ruminal forestomach. In *Food Animal Practice*. D.E Anderson and D.M Rings, (ed). Saunders Elsevier, St Louis, Missouri, USA. pp. 12-19.
- HAILAT, N., AL-DARRAJI, A., LAFI, S., BARAKAT, S.A.F., AL-ANI. F., EL-MAGRABY, H., AL-QUDAH K., GHARAIBEH, S., ROUSAN, M & AL-SMADI, M. (1998). Pathology of the rumen in goats caused by plastic foreign bodies with reference to its prevalence in Jordan. *Small Ruminant Research* **30**, 77-83.
- HENDRICKSON, D.A. (2007) *Techniques in large animal surgery*, 3rd edn., Blackwell Publishing Ltd, Oxford, England, pp. 223-226.
- HOUP, K.A & RECEE, W.O. (2004) *Behavioral physiology*, 12th edn. pp. 952-961. Dukes Physiology of Domestic Animals,
- IGBOKWE, I.O., KOLO, M.Y., & EGWU, G.O. (2003) Rumen impaction in sheep with indigestible foreign body in the semi-arid region of Nigeria. *Small Ruminant Research*, **49**, 141-147.
- LEBBIE, S.H.B. (2004) Goats under household conditions. *Small Ruminant Research* **51**, 131-136.
- MANGIZVO, R.V. (2012) The incidence of plastic waste and their effects in Alice, South Africa. *Online Journal of Social Sciences Research* **1**(2), 49-53.
- MOZAFFARI, A.A., OLOMI, M.M & VOSOUI, D. (2009) Unusual and severe ruminal impaction in a goat-kid: clinical and radiographic findings. *Iranian Journal of Veterinary Surgery* **4**(1,2), 115-118.
- NEMA (2003) *State of the environment report for Kenya 2003*. National Environment Management Authority (NEMA), Nairobi, Kenya.
- OMIDI, A., NAEEMPOOR, H & HOSSEINI, M. (2012). Plastic Debris in the Digestive Tract of Sheep and Goats: An Increasing Environmental Contamination in Birjand, Iran. *Bulletin of Environmental Contamination and Toxicology* **88**, 691–694.
- OTSYINA, H. R., J. NGUHIU-MWANGI., E. G. M. MOGOA, P. G. MBUTHIA & W. O. OGARA (2014) A Retrospective Study on the Prevalence of Plastic Materials in the Rumen of Sheep and Goats in Nairobi, Kenya. *Bulletin of Animal Health and production in Africa* **62**, (3) 197-205.
- OTSYINA, H.R., NGUHIU-MWANGI, J., MOGOA E.G.M MBUTHIA, P.G. & OGARA W.O. (2015) Prevalence of Indigestible Rumen Foreign Bodies in Sheep and Goats at Dagoretti and Kiserian Abattoirs, Kenya. *International Journal of Veterinary Medicine* **3** (2) 75-80.
- [PITRODA, A.H.](#), [TIWARI, D.K.](#), [MEHRAJ-U-DIN DAR](#) & [PARIKH, P.V.](#) (2010). Ultrasonographic diagnosis and treatment of rumen impaction in a goat. *Intas Polivet* **2** (2), 251-252.
- RADOSTITIS, O.M., GRAY, C.C., BLOOD, D.C & HINCHELIPT, K.W. (2009) *Veterinary Medicine: A Textbook of the diseases of cattle, sheep, pig, goats and horses*, 10th edn New York, USA: Saunders Elsevier. Pp. 189-382, 296 and 313.

- RANDALL, D., BURGGREN, W & FRENCH, K. (2002) *Eckert animal physiology: Mechanisms and adaptations*. 5th ed. W.H. Freeman and Compan, New York, NY pp. 78-93.
- RAOOFI A, NAMJOO A, KARIMI A.H & ESFAHANI, M. A. (2012) A study of clinical signs, hematological changes and pathological findings of experimental ingestion of soft foreign body (plastic rope) in goats. *Small Ruminant Research* **105**, 351-354.
- REDDY, Y.R., RAO, S.T.V., NAIDU, P.T & SUNDER, N.S. (2004) Foreign bodies in rumen and reticulum of Punganur cattle. *Indian Veterinary Journal* **81**(9), 1063.
- REMI-ADEWUNMI, B.D., GYANG, E.O., & OSINOWO, A. O. (2004). Abattoir survey of foreign body rumen impaction in small ruminants. *Nigerian Veterinary Journal* **25**, 32-38.
- ROMAN, T. & Y. HIWOT. (2010) Occurrence of rumen foreign bodies in sheep and goats slaughtered at the Addis Ababa Municipality. *Ethiopia Veterinary Journal* **14**(1), 91-100.
- ROSSI, R. & SCHARRER, E. (1992) Circadian patterns of drinking and eating in pygmy goats. *Physiology and Behaviour* **51**, 895-897.
- SILESHI, N., RAMASWAMY, V., CHANDRASHEKHAR, U. & RAJA, N. (2013) Studies on Foreign Body Ingestion and their Related Complications in Ruminants Associated with Inappropriate Solid Waste Disposal in Gondar Town, North West Ethiopia. *International Journal of Animal and Veterinary Advances* **5**(2), 67-74.
- SUTHAR, D.N., JHALA, S.K., BHATT, R H., PATEL, J.B. & JOY, N. (2011). Surgical management of ruminal impaction due to non-penetrating foreign body syndrome in Kankrej cattle. *International Journal for Agro Veterinary and Medical Sciences* **5** (5), 477-480. doi:10.5455/ijavms. 2011081712 3628
- TAN, C.M., (1988) *Utilization of low quality roughage by goats and sheep*. (Ph.D. Thesis.) University of Canterbury, New Zealand.
- VANITHA, V., NAMBI, A.P., GOWRI, P & KAVITHA, S. (2010). Rumen impaction of cattle with indigestible foreign bodies. *Tamilnadi Journal of Veterinary and Animal Sciences* **6**, 138-140.
- VIJAYA, M., REDDY, B. & SASIKALA, P. (2012). A review of foreign bodies with special reference to plastic pollution threat to livestock and environment in Tirupati rural areas. *International Journal of Scientific and Research Publications* **2** (12), 1-8.