

*Full Length Research Paper*

## Histomorphometry aspect of thyroid gland and biochemical profile in pregnant and non-pregnant dromedary camels

Yousef F. Ahmed<sup>1</sup>, Karima Gh. M. Mahmoud<sup>1\*</sup>, Mohamed M. M. Kandiel<sup>2</sup>, Nawito M. F.<sup>1</sup> and AbdelRazik, A. M. A.<sup>1</sup>

<sup>1</sup>Department of Animal Reproduction and A.I, National Research Centre, Dokki, Giza, Egypt.

<sup>2</sup>Department of Theriogenology, Faculty of Veterinary Medicine, Benha University, Egypt.

Received 21 August, 2015; Accepted 10 December, 2015

**Modulation of body physiology and metabolism is a prerequisite for successful pregnancy in camels, which is about a year and few months. The present study was carried out to verify the effect of pregnancy on histomorphometry and functional traits of thyroid gland, as well as some biochemical indices of liver and kidney functions and mineral profile in one humped camels, under Egyptian climatic conditions or desert conditions. The thyroid tissues were fixed in 10% formalin solution and processed following routine histological techniques after gross examination and biometric assessment. Serum levels of thyroid hormones (triiodothyronine, thyroxine and thyroid stimulating hormone), serum blood metabolites (total bilirubin, blood urea nitrogen and creatinine), liver enzymatic activity (aspartate transaminase (AST), alanine transaminase (ALT) and alkaline phosphatase (ALP)), and minerals (sodium, potassium, calcium and phosphorus) were estimated in pregnant (n=30) and non-pregnant (n=30) camels. There were no significant differences between the right and left thyroid lobes between pregnant and non-pregnant camel. Pregnant status in camels had insignificant influence on histological and functional traits of thyroid as well as serum blood metabolites, liver enzymes and minerals levels, as compared with non-pregnant animals during the first six months of pregnancy. Therefore, reproductive status (during early pregnancy) has no substantial effect on camel physiological mechanisms or metabolic activity.**

**Key words:** Biochemical, dromedary, histology, thyroid gland, thyroid hormones.

### INTRODUCTION

Camel, the desert ship, is considered as one of the most adapted animals to live in the deserts. This adaptation depends on the changes in the activity of some endocrine glands, such as the thyroid which is implicated in

numerous important functions. The thyroid is an endocrine gland of a unique feature characterized by its ability to concentrate large amount of iodine for the synthesis of thyroxin from triiodothyronine (Banks, 1993).

\*Corresponding author. E-mail: karima\_mahmoud@hotmail.com. Tel: 002 01001563339. Fax: 002 02 33370931.

Author(s) agree that this article remains permanently open access under the terms of the [Creative Commons Attribution License 4.0 International License](http://creativecommons.org/licenses/by/4.0/)

Thyroid hormones are crucial for development of the fetal brain, as well as for many other aspects of pregnancy and fetal growth. Thyroxin is essential for proper body metabolism and it plays significant role in the development and differentiation of all body cells (Choksi et al., 2003). So far, numerous morphological variations of this gland are still undiscovered. Moreover, compared to studies on other domestic animals such as cattle, sheep, and goats, literature is scanty on the physiological and hormonal changes during pregnancy in camel. Camels have a long gestation period (~ 13 months) and it is anticipated that energy requirements surge promptly during pregnancy. This might impact the levels of some biochemical indices.

Camel thyroid gland shared the same morphological characterization of those of mammalian species, with exception for the presence of apocrine secretion (Atoji et al., 1999). The thyroid gland consists of follicles of varied sizes separated by interfollicular connective tissue. The large follicles are lined by very low cuboidal or flattened squamous follicular cells whereas the small ones are lined by high cuboidal or low columnar follicular cells (Abdel-Magied et al., 2000).

In the available literature, there are no studies that correlated the histomorphometrical aspects of the thyroid gland and reproductive status (pregnant vs. non-pregnant) in camels. The purpose of this study was to provide baseline data on the biometric, histological and biochemical of the thyroid gland of the one humped pregnant camel under Egyptian climatic conditions that could complement other information available on this species.

## MATERIALS AND METHODS

### Experimental animals and blood sampling

Thyroid glands were recovered from 30 pregnant and 30 non-pregnant one-humped camel (aged between 8 to 10 years) of unknown breeding history at Cairo slaughter houses. Fetal age which ranged from 30 to 180 days was determined according to the formula (age in days = Crown - Vertebral - Rump length; CVRL (cm) + 23.99 / 0.366) as specified by El-Wishy et al. (1981). Blood samples were collected aseptically into vacutainers from the jugular vein before camels were slaughtered. They were centrifuged at 750 g for 15 min, and the separated sera were maintained at -20°C until analysis.

### Biometric and histological analysis

The left and right lobe of the thyroid gland from pregnant and non-pregnant camels were removed and the weight (g), length (cm), width (cm) and thickness (cm) were assessed. Immediately after gross examination, the collected tissue samples of the thyroid gland were fixed in 10% neutral buffered formalin for histological examination. The samples were then dehydrated in graded ethanol and embedded in paraffin wax.

Sections of 5 µm thickness were stained with Hematoxylin and Eosin (H&E) and then examined under microscope (Bancroft et al., 1996).

### Biochemical analysis

The concentrations of serum total bilirubin, urea and creatinine were assessed colorimetrically according to Harold (1988) and Henry (1974). Aspartate transaminase (AST) and alanine transaminase (ALT) were evaluated according to Reitmann and Frankel (1957). Alkaline phosphatase (ALP) was measured according to the method of Anonymous (1972). Serum phosphorus concentration was estimated using the colorimetric method as described by Tietz (1990). Serum concentrations of sodium, potassium and calcium were measured by the colorimetric method as described by Trinder (1951), Sunderman and Sunderman (1958) and Trinder (1964), respectively.

### Hormone assays

Quantitative determination of circulating total T4 (Cat. No. 10302), T3 (Cat. No. 10301), and TSH (Cat. No. 10303) in she-camel sera samples was performed with the use of commercial Enzyme Immunoassay Test Kits (BIOS<sup>®</sup>, ChemuxBioScience Inc., South San Francisco, USA). Assays were realized according to the manufacturer's instruction.

### Statistical analysis

Data were tabulated and presented as mean ± SE (n = 30 per group). Independent student *t*-test was applied using statistical package for social sciences (SPSS) Statistics (versions 16.0) to find the significant difference between the mean of the data in pregnant and non-pregnant at level 0.05% (Al-Mohammed et al., 1986).

## RESULTS

### Biometric findings

The values of weight, length, width and thickness of right thyroid lobe were 14.0 ± 1.2 and 15.6 ± 1.2 g, 8.3 ± 0.5 and 9.8 ± 0.5 cm, 2.9 ± 0.2 and 3.04 ± 0.2 cm, 1.1 ± 0.1 and 1.0 ± 0.02 cm in pregnant and non-pregnant camel, respectively. The corresponding values of left thyroid lobe in pregnant and non-pregnant camel were 13.1 ± 1.4 and 14.3 ± 1.3 g, 8.3 ± 0.4 and 8.7 ± 0.6 cm, 1.1 ± 0.1 and 1.0 ± 0.02 cm, 2.8 ± 0.4 and 3.1 ± 0.1 cm, respectively (Table 1).

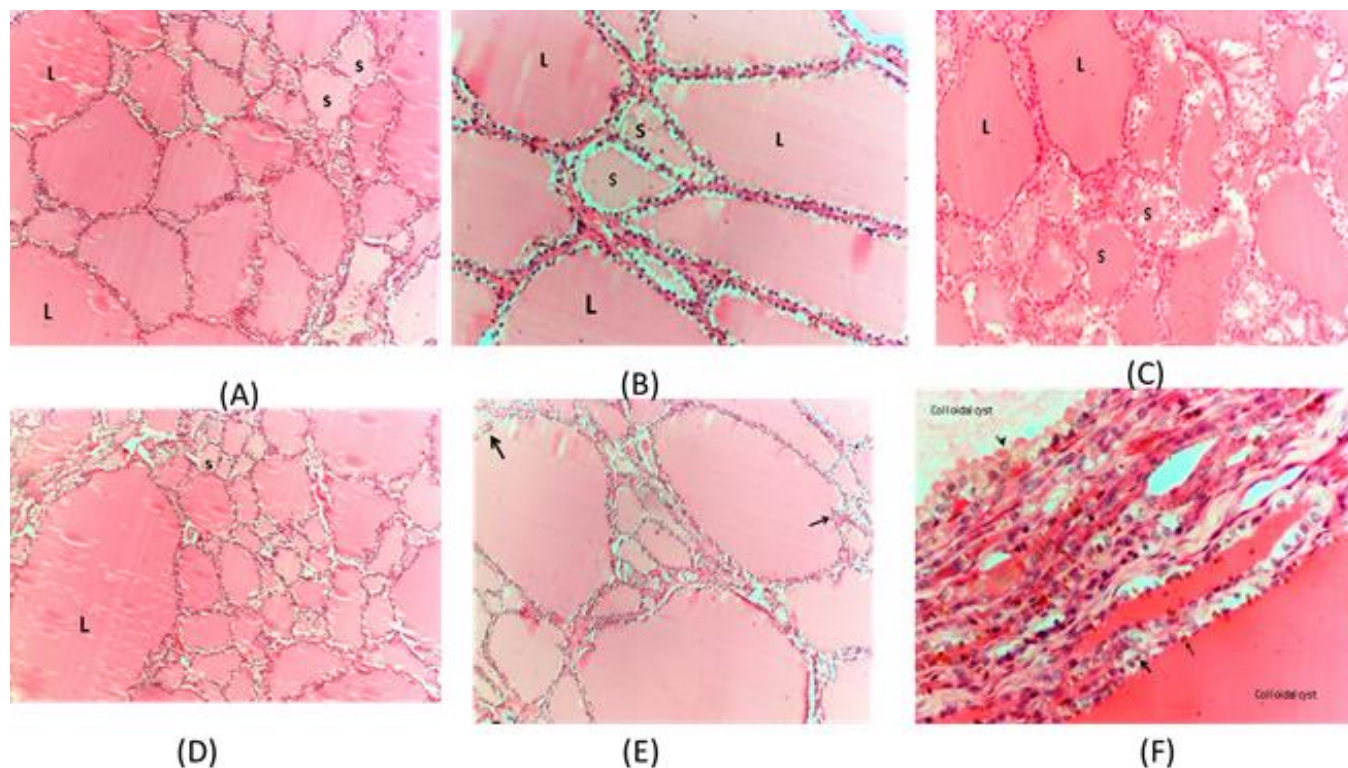
The statistical analysis revealed non-significant difference in aforementioned parameters between the two groups for both left and right lobes. Moreover, there were no significant differences between the right and left lobe in pregnant and non-pregnant camel.

### Histological findings

The general histological structure of the thyroid gland of one humped female camel was observed to consist of a connective tissue capsule of coarse and fine collagenous fibers, from which trabeculae extended into the parenchyma of the gland and divided it into lobules. Each lobule consisted of aggregations of follicles. A thin network of interfollicular connective tissue elements and

**Table 1.** Weight and dimensions of thyroid gland lobes in pregnant and non pregnant one-humped camel under Egyptian climates (Mean  $\pm$  SE).

Parameter	Pregnant		Non -pregnant	
	Right lobe	Left lobe	Left lobe	Right lobe
Weight (g)	13.1 $\pm$ 1.4	14.0 $\pm$ 1.2	14.3 $\pm$ 1.3	15.6 $\pm$ 1.2
Length (cm)	8.3 $\pm$ 0.4	8.3 $\pm$ 0.5	8.7 $\pm$ 0.6	9.8 $\pm$ 0.5
Width (cm)	2.8 $\pm$ 0.4	2.9 $\pm$ 0.2	3.1 $\pm$ 0.1	3.04 $\pm$ 0.2
Thickness (cm)	1.10 $\pm$ 0.10	1.10 $\pm$ 0.10	1.00 $\pm$ 0.02	1.00 $\pm$ 0.02



**Figure 1.** Histological section of thyroid gland of camel stained with H&E showing the follicles are rounded irregular size and shape: small (S) and large (L) follicles were seen ( $\times 200$ , A and  $\times 400$ , B). The small (S) follicles are active and the large (L) follicles are inactive ( $\times 200$ , C), Moderate active or inactive of small (S) and large (L) follicles ( $\times 200$ , D). Papillary projections of epithelial cells into the follicular lumens ( $\times 200$ , E). Two large colloid cysts lined with single layer of columnar cell (arrowhead), also intra cytoplasmic lipofuscin pigment were seen (arrows) ( $\times 400$ , F).

blood capillaries surrounded each follicle. Two main types of follicles were identified; large and small follicles, lined with single or multiple layers of epithelial cells. All follicles had minute peripheral vacuoles and follicular colloid, all follicles possessed peripheral colloid vacuoles within the colloid lumen - anything peripheral cannot be between cells which indicate the metabolic activity of the follicles (Figure 1A). Nearly all the small follicles appeared active because of colloid vacuoles (Figure 1B), but the large follicles were lined with less or inactive cells in most of the cases (Figure 1C and D).

The epithelial cells of large follicles in some cases

formed papillary projections into the lumens (another evidence of activity: endocytosis) (Figure 1E). In the meantime, the large follicles formed very large cystic nodules in many cases (Figure 1F) which compress to the adjacent follicles and change their shape to a flat shape. The follicular cystic nodules, its fibrosis of the epithelium due to age, may contain colloid and lined with single columnar active epithelial cells (Figure 1F). An intracytoplasmic lipofuscin pigment was seen in the epithelial lining of many follicles (Figure 1F). There was no significant variation between pregnant and non-pregnant camels in terms of the histological structure of

**Table 2.** Changes in circulating hormones, blood metabolites, liver enzymes and electrolytes in pregnant and non-pregnant one-humped camel under Egyptian climates (Mean  $\pm$  SE).

Parameter	Pregnant	Non-pregnant
<b>Circulating hormones</b>		
T4 ( $\mu$ g/dl)	14.8 $\pm$ 2.4	17.9 $\pm$ 1.9
T3 (ng/dl)	1.8 $\pm$ 0.5	1.9 $\pm$ 0.5
TSH ( $\mu$ IU/dl)	1.5 $\pm$ 0.0	1.5 $\pm$ 0.1
<b>Blood metabolites</b>		
Blood urea nitrogen (mg/dl)	14.6 $\pm$ 1.5	16.0 $\pm$ 1.8
Creatinine (mg/dl)	1.3 $\pm$ 0.1	1.4 $\pm$ 0.1
Total bilirubin (mg/l)	0.13 $\pm$ 0.02	0.12 $\pm$ 0.02
<b>Serum liver enzymes</b>		
AST (U/L)	164.9 $\pm$ 17.9	166.6 $\pm$ 16.1
ALT (U/L)	21.5 $\pm$ 3.2	17.5 $\pm$ 1.9
ALP (U/L)	74.5 $\pm$ 9.9	93.3 $\pm$ 9.5
<b>Serum electrolytes</b>		
Sodium (mole/L)	143.2 $\pm$ 7.9	150.7 $\pm$ 8.5
Potassium (mole/L)	3.9 $\pm$ 0.2	3.7 $\pm$ 0.3
Calcium (mg/l)	8.9 $\pm$ 0.4	9.1 $\pm$ 0.2
Phosphorus (mEq/l)	4.9 $\pm$ 0.4	5.1 $\pm$ 0.2

thyroid gland.

### Hormonal levels and biochemical indices

The mean levels of thyroid hormones (T3, T4 and TSH) were lower in pregnant than those of non-pregnant camels; however, the difference was not statistically significant (Table 2). There was no significant difference between pregnant and non-pregnant camels in the concentrations of blood metabolites (total bilirubin, urea nitrogen and creatinine), Liver enzymes (AST, ALT and ALP) and serum electrolytes (sodium, potassium, calcium and phosphorus) as presented in Table 2.

### DISCUSSION

Gestation is concomitant with physiological changes which are required for fetal growth, survival and preparation for parturition. In camel, the morphological variations of thyroid differ according to the changes in the environmental condition and thus bring about the necessary physiological adjustment to the changing environment (Rejeb et al., 2011). However, the effect of pregnancy on thyroid morphometric properties still is not clear.

In the current study, biometric analysis revealed the insignificant effect of neither pregnancy nor lobe direction on female camels' thyroid gland measures, with special emphasis to the stage from 30 to 180 days of gestation period. It is suggested that fetal development and its requirements during this stage does not modify the thyroid gland status of female camel. Generally, the thyroid mass increases within the normal range during gestation in iodine deficient regions, while not in those with plenty iodine. Moreover, during pregnancy, the thyroid gland mass and function acclimatize in a physiological way to meet the increasing demands for iodine and energy (Berghout and Wiersinga, 1998). However, it is expected that this relation can be changed and thyroid activity increased during late pregnancy (Tibary and Anouassi, 1997), probably due to the increasing camel requirement in preparing for calving.

Histological analysis of thyroid structures in this study revealed the sharing of common properties of one humped camel to that of other domestic animals (Hussin and Al-Taay, 2009) with exception for the presence of minute peripheral vacuoles between the epithelial cells and follicular colloid in all follicles which indicate their metabolic activity. These findings largely agreed with former studies in camel (Atoji et al., 1999; Abdel-Magied et al., 2000; Kausar and Shahid, 2006). With respect to pregnancy status in our study, no variations in the thyroid histological structure were seen in the two camel groups. In this respect, no reports were recorded previously in one humped camels thus correlate the thyroid gland with pregnancy status. In buffaloes, the histological picture of thyroid gland differed during early pregnancy as compared to mid- and late pregnancy, where a high epithelium and smaller follicular diameter and colloid volume were observed during early pregnancy (Soliman et al., 1973).

Current results regarding thyroid and TSH hormones failed to show significant differences between pregnant and non-pregnant dromedary camels, although lower mean levels were observed in the former status. These results indicate the stability of body and/or energy metabolism in camels regardless of reproductive status, as thyroid hormones are known as important modulators of general metabolism in which carbohydrates and lipids are the major constituents. These findings in accordance with former studies demonstrated insignificance of pregnancy effect on thyroid hormones levels in one humped (Omidi et al., 2014a) and two humped camels (Omidi et al., 2014b). Also, Agarwal et al. (1989) indicated that T4 and T3 levels were not affected by failure of conception or by abortion. In general, serum levels of thyroid hormones in camels are mainly affected by general body metabolism, season and water availability (Nazifi et al., 2009).

In the present study, there were non-significant differences either in blood parameter (total bilirubin, urea nitrogen and creatinine) or liver enzymatic activity

[aspartate transaminase (AST), alanine transaminase (ALT) and alkaline phosphatase (ALP)] during pregnancy in comparing with non-pregnant condition. The creatinine level (marker of kidney function) is dependent on the dietary intake, synthesis rate of creatinine. Therefore, the high creatinine levels in animals during gestation could be as a result of higher protein needs and this is associated with late stage of pregnancy due to the lower rate of kidney elimination (Omid et al., 2014b). Bengoumi et al. (1997) showed that the physiological stage of pregnancy and lactation did not have any significant effect on serum AST, ALT and ALP activities in dromedary camels. Omid et al. (2014b) stated that, while the serum levels of biochemical parameters (urea, creatinine and total proteins) and liver enzymes (AST, ALT, and Gamma-glutamyl transferase (GGT) were not significantly different with pregnancy, serum levels of ALP in pregnant Bactrian camels were significantly lower than those of the non-pregnant camels. The disagreement between the current results and study by Omid et al. (2014b) in terms of ALP activity might be attributed to the difference in the age of animals as well as breed of camels. Vertor and Swaton (1969) verified the relation between age and ALP concentration in cattle, sheep, and camels, where the younger animals have higher serum ALP activity.

Macro- and micro-electrolytes are necessary elements for animal functioning and health. Current analysis in one humped camels investigated under Egyptian climatic conditions revealed none-significant effect of pregnancy on electrolytes (calcium, phosphorus, sodium, potassium) metabolism and/or mobilization. Besides, the mean serum calcium and potassium concentrations recorded are within the range of previous reports in one-humped camel (Mohamed and Hussein, 1999; Amin et al, 2007; Babeker et al., 2013). These results are consistent with former studies which found that calcium, phosphorus (Omid et al., 2014b), sodium and potassium (Ashwag et al., 2015) insignificantly differed between pregnant and non-pregnant camels. On the contrary, lowered calcium and phosphorus levels might be encountered towards the end of pregnancy (Eltohamy et al., 1986). On the other hand, lactation has been found to have more profound effect on the serum mineral levels in camels where the camels which were pregnant and at the same time lactating had lower levels of P, Ca, Co, Cu and Zn, but higher levels of K, Na and Mg compared to those which were only lactating (Kuria et al., 2013).

## Conclusion

One humped camels show high adaptability to environmental conditions which seem not to be affected by the reproductive status (pregnant vs. non-pregnant) and this undoubtedly is ascribed from the unchanged thyroid gland histomorphometry and activity, as well as

blood metabolites, liver and kidney function, and macro- and micro-minerals levels, at least, during the first six months of pregnancy.

## Conflict of interests

The author(s) did not declare any conflict of interest.

## REFERENCES

- Abdel-Magied E M, Taha A A, Abdalla B (2000). Light and electron microscopic study of the thyroid gland of camel (*Camelus dromedarius*). *Anat. Histol. Embryol.* 29:331-336.
- Agarwal SP, Khanna ND, Agarwal VK, Dwaraknath PK (1989). Circulating concentrations of thyroid hormones in pregnant camels (*Camelus dromedarius*). *Theriogenology* 31:1239-47.
- Al-Mohammed NT, Al-Rawi KM, Younis MA, Al-Marrany WK (1986). Principles of Statistics. Mousl: Book House for Printing and Publishing.
- Amin AS, Abdoun KA, Abdelatif AM (2007). Seasonal variation in blood constituents of one-humped camel (*Camelus dromedaries*). *Pak. J. Biol. Sci.* 10:1250-1256.
- Anonymous (1972). Rec. GSCC, Optimised standard colorimetric methods. Serum Alkaline phosphatase (DGKC). *J. Clin. Biochem.* 10:182.
- Ashwag EAM, Ghurashi MAH, Seri HI (2015). Comparative Biochemical Values in Pregnant and Non-pregnant Dromedary Camels (*Camelus dromedarius*). The Regional Conference of Camel Management and Production under Open range System (RCCMPR), Khartoum-Sudan, 2<sup>nd</sup>-4<sup>th</sup> March. P 22 (Abstract).
- Atoji Y, Yamamoto Y, Suzuki Y, Sayed R (1999). Ultrastructures of the thyroid gland of the one-humped camel (*Camelus dromedarius*). *Anat. Histol. Embryol.* 28:23-26.
- Bancroft JD, Stevens A, Turner DR (1996). Theory and Practice of Histological Techniques. 4<sup>th</sup> edition, Churchill Livingstone Co., New York, London, San Francisco, Tokyo.
- Banks WJ (1993). Applied Veterinary Histology. 3rd Ed., Mosby-Year Book, Inc. USA. pp. 414-415.
- Bengoumi M, Faye B, El Kasmi K, De La Farge F (1997). Clinical enzymology in the dromedary camel (*Camelus dromedarius*): part 2. Effect of season, age, sex, castration, lactation and pregnancy on serum AST, ALT, GGT, AP and LDH activities. *J. Camel Pract. Res.* 4:25-29.
- Berghout A, Wiersinga W (1998). Thyroid size and thyroid function during pregnancy: an analysis. *Eur. J. Endocrinol.* 138:536-542.
- Choksi NY, Jahnke GD, Hilarie STC, Shelby M (2003). Role of thyroid hormones in human and laboratory animal reproductive health. *Birth Defects Res. B Dev. Reprod. Toxicol.* 68:479-491.
- Eltohamy MM, Salama A, Yousef AA (1986). Blood constituents in relation to the reproductive state in she-camel (*Camelus dromedarius*). *Beitr Trop. Landwirtsch Veterinarmed.* 24:425-430.
- El-Wishy AB, Hemeida N A, Omar M A, Mobarak AM, El-Sayed MAI (1981). Functional changes in the pregnant camel with special reference to fetal growth. *Br. Vet. J.* 137:527-537.
- Harold S (1988). Practical Clinical Biochemistry. C.B.S. Publishers, New Delhi, pp.132-140.
- Henry RJ (1974). In: Clinical Chemistry, Principles and Techniques. Harper and Row (Eds.), 2<sup>nd</sup> Edn., p. 543.
- Hussin AM, Al-Taay MM (2009). Histological study of the thyroid and parathyroid glands in Iraqi buffalo "bubalus bubalis" with referring to the seasonal changes. *Bas. J. Vet. Res.* 8:26-38.
- Kausar R, Shahid RU (2006). Gross and microscopic anatomy of thyroid gland of one-humped camel (*Camelus dromedarius*). *Pak. Vet. J.* 26:88-90.
- Kuria S G, Tura IA, Amboga S, Walaga HK (2013). Status of minerals in camels (*Camelus dromedarius*) in north eastern Kenya as evaluated from the blood plasma. *Livest. Res. Rural Dev.* 25:8.

- Mohamed HA, Hussein AN (1999). Studies on normal hematological and serum biochemical values of the Hijin racing camels (*Camelus dromedarius*). Kuwait. Vet. Res. Commun. 24:241-248.
- Nazifi S, Nikahval B, Mansourian M, Razavi SM, Farshneshani F, Rahsepar M, Javdani M, Bozorgi H (2009). Relationships between thyroid hormones, serum lipid profile and erythrocyte antioxidant enzymes in clinically healthy camel (*Camelus dromedarius*). Rev. Med. Vet. 160:3-9.
- Omidi A, Sajedi ZH, Montazer Torbati MB, Mostafai M (2014b). Metabolic profile of pregnant, non-pregnant and male two humped camels (*Camelus bactrianus*) of Iran. Iran. J. Vet. Med. 8:235-242.
- Omidi A, Sajedi Z, Montazer Torbati MB, Ansari Nik H (2014a). Lipid profile and thyroid hormone status in the last trimester of pregnancy in single-humped camels (*Camelus dromedarius*). Trop. Anim. Health Prod. 46:609-614.
- Reitmann S, Frankel SA (1957). A colorimetric method for the determination of serum glutamic oxaloacetic and glutamic pyruvic transaminase. Am. J. Clin. Pathol.. 28(1):56-63.
- Rejeb A, Amara A, Rekik M, Rezeigui H, Crespeau F (2011). Histomorphometry and hormone secretion of the thyroid gland of the dromedary (*Camelus dromedarius*). J. Camelid. Sci. 4:10-22.
- Soliman EA, Afiefy MM, Zaki K, Abul-Fadle W, Ayoub LA, Fahmy MF (1973). Variations in thyroid status of the buffalo during the estrous cycle, pregnancy and in conditions of ovarian abnormalities. Zentralbl. Veterinarmed. A. 20:324-331.
- Sunderman FW Jr, Sunderman F W (1958). Colorimetric determination of potassium in serum and plasma. Am. J. Clin. Pathol. 29:95.
- Tibary A, Anouassi A (1997). Reproductive physiology in the female camelidae. Chapter VI. In: Theriogenology in Camelidae. Abu Dhabi Printing and Publishing Co., Mina, Abu Dhabi, United Arab Emirates. pp. 169-229.
- Tietz NW (1990). Clinical Guide to Laboratory Tests. 2nd Edit. Philadelphia Pa: WB Saunders Company. pp. 444-447.
- Trinder P (1951). A rapid method for the determination of sodium in serum. Analyst 76:596-599.
- Trinder P (1964). Colorimetric Micro-determination of Serum Calcium. In: Microanalysis in Medical Biochemistry. Wooton, J.D.P. (Ed.). Churchill Ltd. London. 6<sup>th</sup> Edn., pp. 76-77.
- Vertor W, Swaton R (1969). Alkaline phosphatase and acid phosphatase in cattle, sheep and camel serum with special reference to lymphatic leucosis in cattle. Mh Vet Med. 19:384-390.