

African Journal of Biotechnology Vol. 9(42), pp. 7216-7223, 18 October, 2010
Available online at <http://www.academicjournals.org/AJB>
DOI: 10.5897/AJB10.1041
ISSN 1684-5315 ©2010 Academic Journals

Full Length Research Paper

Protective role of flaxseed oil against lead acetate induced oxidative stress in testes of adult rats

Ahmed E. Abdel Moniem^{1*}, Mohamed A. Dkhal^{1,2} and Saleh Al-Quraishy²

¹Department of Zoology and Entomology, Faculty of Science, Helwan University, Cairo, Egypt.

²Department of Zoology, College of Science, King Saud University, Riyadh, Saudi Arabia.

Accepted 9 September, 2010

Even though the toxic effects of lead compounds had been studied over many years, inconsistent results have been obtained about their oxidative stress in the testes of adult rats. Lead acetate (20 mg/kg) alters the histology of testes as well as enhances lipid peroxidation and nitric oxide production in both serum and testes with concomitant reduction in glutathione (GSH) and antioxidant enzymes as catalase (CAT), superoxide dismutase (SOD), glutathione reductase (GR), glutathione-S-transferase (GST) and glutathione peroxidase (GPx). Moreover, lead acetate induced DNA fragmentation in testes of rats. Treatment of rats with flaxseed oil (1000 mg/kg) resulted in marked improvement in all studied parameters. On the basis of the aforementioned results, it can be hypothesized that flaxseed oil is a promising natural product to protect against lead acetate induced oxidative stress and toxicity in rats.

Key words: Lead, flaxseed oil, oxidative stress, testes, rat.

INTRODUCTION

The toxicity of lead remains a matter of public health concern (Duzgoren-Aydin, 2007) due to its pervasiveness in the environment and the awareness about its toxic effects (Saleh et al., 2003) at exposure levels lower than what was previously considered harmful (Sandhir et al., 1994). Reproductive consequences of lead exposure are widespread (Patrick, 2006), affecting almost all aspects of reproduction (Zheng et al., 2003). Lead induces decreased sperm count, motility and increased morphological abnormalities in animals (Hsu et al., 1998; Hsu et al., 1997). It is essential to find an appropriate approach to prevent and treat a lead-exposed person. The current approved treatment for lead poisoning is to administer chelating

agents (thiol chelators and other complexons) that form an insoluble complex with lead and remove it from lead enriched tissue; but most of these chelating agents from many side effects (Flora et al., 1995) and are ineffective to reduce lead exposure. Free radical generation is referred to as the pathogenesis of lead, so supplementation of antioxidants could be considered as the alternative method for chelation therapy (Flora et al., 2003). Ascorbic acid, an anti-oxidant chelating agent used in the treatment of lead toxicity, has been reported to protect the cells and sperm from oxidative stress and loss of motility, respectively (Patra et al., 2001).

Flaxseed oil, *Linum unisatissimum*, has a history of food use in Europe and Asia for its potential health benefits, which include anticancer effects, antiviral and bactericidal activity, anti-inflammatory effect, ion reduction, laxative uses and reduction of atherogenic risks (Craig, 1999). The current study is aimed at investigating the role of flaxseed oil in reduction of the alterations induced in the testis of rats by lead acetate.

*Corresponding author. E-mail: aest1977@hotmail.com. Tel: (+2) 0103499114.

Abbreviations: NO, Nitric oxide; MDA, malondialdehyde; ELISA, enzyme-linked immunosorbent assay; GSH, glutathione; TBARS, thiobarbituric acid reactive substances; DHBS, 3,5-dichloro-2-hydroxybenzene sulfonic acid; AAP, 4-aminophenazone; SOD, superoxide dismutase; GST, glutathione-S-transferase; GPx, glutathione peroxidase; GSSG, oxidized glutathione; O.D, optical density; CAT, catalase; GR, glutathione reductase.

MATERIALS AND METHODS

Animals

Adult male albino rats weighing 120 – 150 g and aged 7 - 9 weeks

old were obtained from The Holding Company for Biological Products and Vaccines (VACSERA, Cairo, Egypt). The animals were kept in wire bottomed cages in a room under standard condition of illumination with a 12 - h light-dark cycle at $25 \pm 1^\circ\text{C}$. They were provided with tap water and balanced diet *ad libitum*. The experiments were approved by the state authorities and it followed the Egyptian rules on animal protection.

Experimental protocol

To study the effect of flaxseed oil on lead acetate mediated testicular dysfunction, twenty four adult male albino rats were randomly distributed to four groups (six rats for each). Group I (Con) served as vehicle control and received saline, NaCl 0.9%, (0.3 ml saline/ rat) by oral administration. Group II (Pb) received intraperitoneal (i.p.) injection (100 μl) of 20 mg/kg lead acetate (Ito et al., 1985) for 5 days. Group III (FSO) received 0.3 ml of flaxseed oil by gavages (orally) once a day for 5 days at a dose of 1000 mg/kg (Bhatia et al., 2007) and the animals of group IV (Pb + FSO) received 0.3 ml flaxseed oil by gavages once a day for 5 days at a dose of 1000 mg/kg body weight. One hour after the treatment with flaxseed oil, group IV was intraperitoneally injected with 100 μl of 20 mg/kg lead acetate for 5 days. Consequently, after 24 h of the last i.p. injection of lead acetate, the animals of all groups were cervically dislocated and blood samples were collected. This was followed by the samples standing for half an hour and then centrifuged at 500 g for 15 min at 4°C to separate serum and stored at -70°C . Part of the liver was weighed and homogenized immediately to give 50% (w/v) homogenate in ice-cold medium containing 50 mM Tris-HCl and 300 mM sucrose (Tsakiris et al., 2004). The homogenate was centrifuged at 500 g for 10 min at 4°C . However, 10% of the supernatant was used for various biochemical determinations.

Testis index

At the end of the experimental period, each rat was weighted and the left testis was then removed and weighed. Finally, the testis index was calculated by dividing the left testis weight by the body weight and then multiplying by 100.

Histological examination

Pieces of testes were fixed in 10% neutral-buffered formalin that was embedded in paraffin and the deparaffinized sections were stained routinely with hematoxyline and eosin.

Biochemical estimations

Determination of serum testosterone

Quantitative measurement of serum testosterone was carried out by adopting enzyme-linked immunosorbent assay (ELISA) technique using kits purchased from Calbiotech Inc., (Austin, Canada) according to the method described by Joshi et al. (1979).

Determination of nitric oxide and lipid peroxidation levels

Nitric oxide (NO) and malondialdehyde (MDA) were assayed colorimetrically in the testis homogenate according to the method of Berkels et al. (2004) and Ohkawa et al. (1979) respectively, where MDA was determined by using 1 ml of trichloroacetic acid (10%) and 1 ml of thiobarbituric acid (0.67%). Consequently, they were

then heated in a boiling water bath for 30 min. Thiobarbituric acid reactive substances (TBARS) were determined by the absorbance at 535 nm and expressed as malondialdehyde formed. Nitric oxide was determined somewhere in the acid medium and in the presence of nitrite, so that the formed nitrous acid diazotise sulphanilamide is coupled with N-(1-naphthyl) ethylenediamine. The resulting azo dye has a bright reddish – purple color which can be measured at 540 nm.

Estimation of glutathione reduced and anti-oxidant enzymes

Testicular reduced glutathione (GSH) were determined by the methods of Ellman (1959). The method was based on the reduction of Elman's reagent (5,5'-dithiobis (2-nitrobenzoic acid) "DTNB") with GSH to produce a yellow compound. The reduced chromogen that is directly proportional to GSH concentration and its absorbance can be measured at 405 nm. In addition, the level of testicular antioxidant as catalase (CAT) activity of testis was assayed by the method of Aebi (1984). As a result, catalase reacts with a known quantity of H_2O_2 . The reaction is stopped exactly after one minute with catalase inhibitor. In the presence of peroxidase (HRP), the remaining H_2O_2 reacts with 3,5-Dichloro-2-hydroxybenzene sulfonic acid (DHBS) and 4-aminophenazone (AAP) to form a chromophore with a color intensity that is inversely proportional to the amount of catalase in the original sample.

Testicular superoxide dismutase (SOD) activity was assayed by the method of Nishikimi et al. (1972). This assay relies on the ability of the enzyme to inhibit the phenazine methosulphate-mediated reduction of nitroblue tetrazolium dye. Glutathione-S-transferase (GST) activity in the testis was assayed by the method of Habig et al. (1974). The total GST activity was done by measuring the conjugation of 1-chloro-2,4-dinitrobenzene (CDNB) with reduced glutathione. The conjugation is accompanied by an increase in absorbance at 340 nm. The rate of increase is directly proportional to the GST activity in the sample.

Testicular glutathione peroxidase (GPx) activity was measured by the method of Paglia and Valentine (1967) and the assay was an indirect measurement of the activity of GPx. Oxidized glutathione (GSSG), produced upon reduction of organic peroxide by GPx, was recycled to its reduced state by the enzyme glutathione reductase (GR). The reaction was initiated by the addition of hydrogen peroxide, and the oxidation of NADPH to NADP^+ is accompanied by a decrease in absorbance at 340 nm.

Glutathione reductase activity of testis was assayed by the method of Factor et al. (1998). Glutathione reductase catalyzes the reduction of glutathione in the presence of NADPH, which is oxidized to NADPH^+ . As a result, the decrease in absorbance at 340 nm was measured.

Analysis of DNA fragmentation

The detection of DNA fragmentation using agarose gel electrophoresis was performed as described (Watabe et al., 1996). The testis homogenate was washed twice with phosphate buffered saline (PBS) and the washed cells were lysed in a solution of 10 mM Tris-HCl (pH 8.0), 10 mM ethylenediaminetetraacetic acid (EDTA), 0.5% (w/v) sodium dodecyl sulfate and 0.1% (w/v) RNase A, with incubation for 60 min at 50°C . The lysate was incubated for an additional 60 min at 50°C with 1 mg/ml proteinase K and then subjected to electrophoresis for 60 min at 50 V in a 1% (w/v) agarose gel in 40 mM Tris acetate (pH 7.5) containing 1 mM EDTA. After electrophoresis, DNA was visualized by staining with ethidium bromide. The amount of DNA fragmentation in testes of rats was quantified by the image analyzer. Images were captured using Gene Genius Bio Imaging System, and the optical density (O.D)

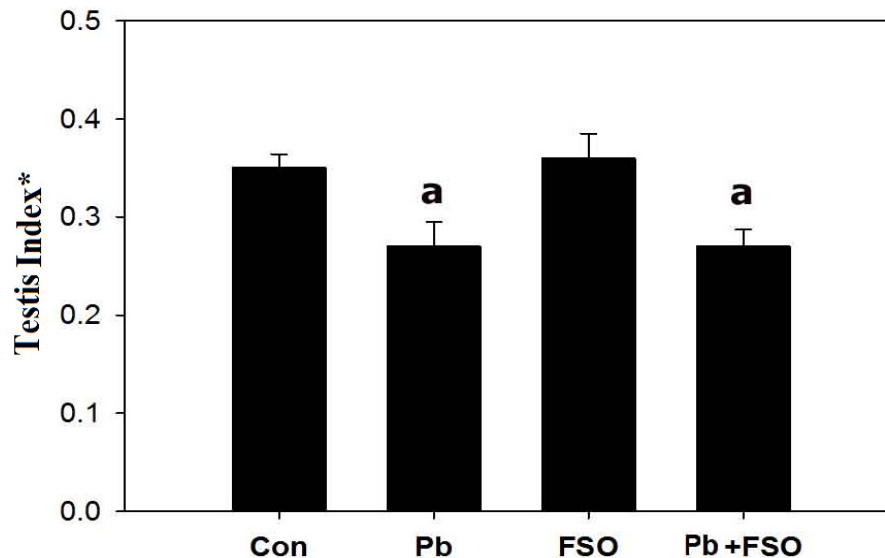


Figure 1. The effect of lead acetate and flaxseed oil on the testis index of rats. Values are means \pm SE (n = 6). a, significant change at $p < 0.05$ with respect to the control group; *ratio of the testis weight in g/rat to body weight in g/rat.

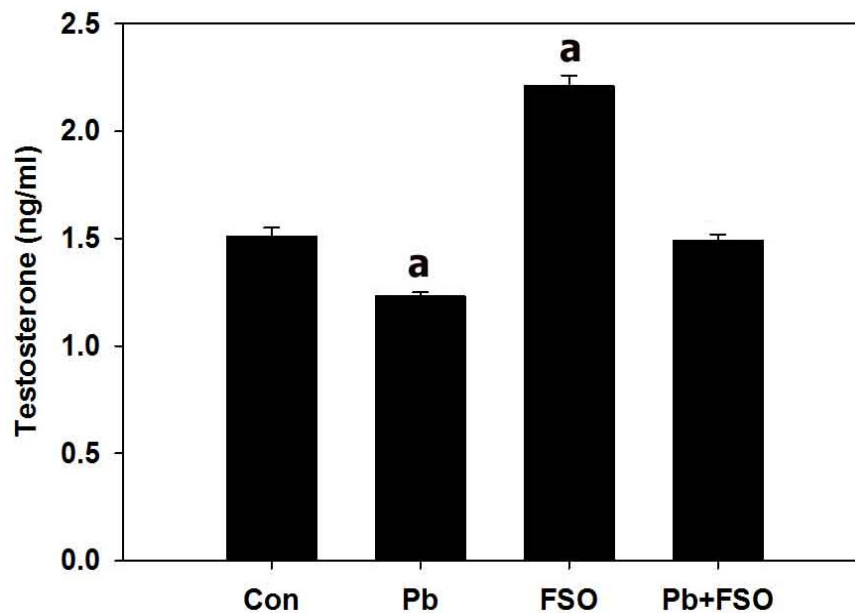


Figure 2. Reduced serum testosterone level in rats administered lead acetate due to treatment with flaxseed oil. Values are means \pm SE (n = 6). a, significant change at $p < 0.05$ with respect to control group.

values of DNA products were measured using Gene Tools Software.

Statistical analysis

The obtained data were presented as means \pm standard error. One way analysis of variance (ANOVA) was carried out, and the statistical comparisons among the groups were performed with Duncan's test using a statistical package program (SPSS version 17.0).

RESULTS

Lead acetate administration in rats caused a significant decrease in testis index (Figure 1) indicating that Pb^{+2} caused impaired testis function. Additionally, the level of blood serum testosterone was significantly decreased (Figure 2). On the other hand, flaxseed oil restored both the rats' body weights (Figure 1) and testosterone level to

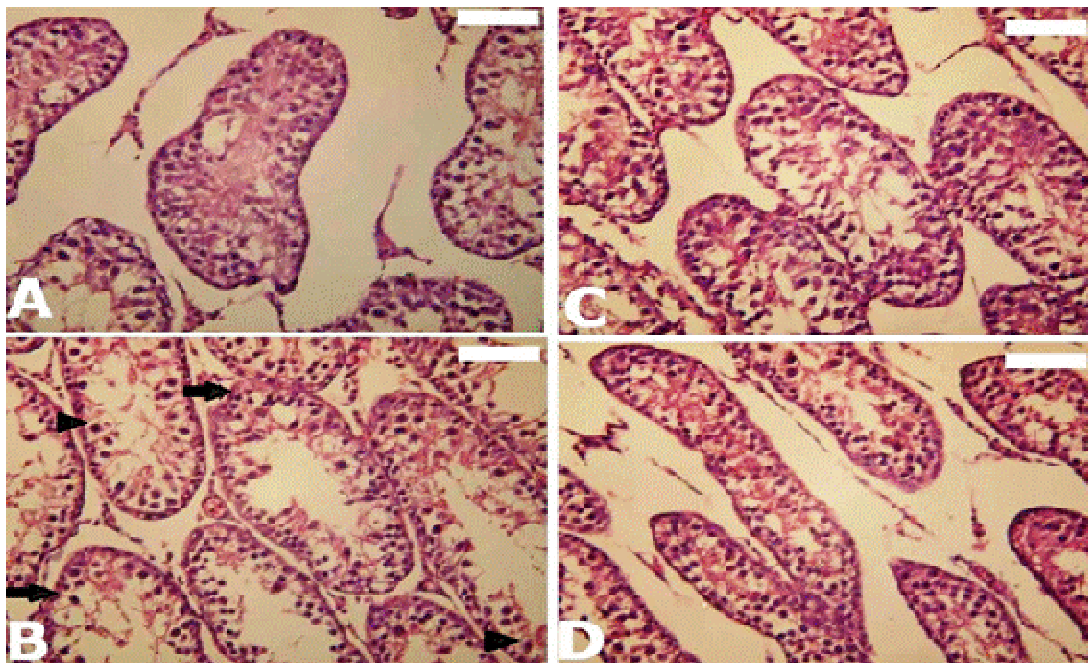


Figure 3. Histological changes in testes of rats. (A) Control testis with normal architecture; (B) rats treated with lead acetate that has degenerated seminiferous tubules (arrow) and vacuolar degeneration in the cytoplasm of the spermatogenic epithelium (arrow head); (C) rats treated with flaxseed oil; (D) Rats treated with the lead acetate and flaxseed oil. Sections were stained with hematoxylin and eosin. Bar = 20 μ m.

the control range, but it failed to restore the testis index to its normal range (Figure 2). Light microscopy was used for evaluation of testicular histology and the seminiferous tubules of the control rats were completely differentiated. Spermatozoa are shown in some of the tubules (Figure 3A). In contrast, in the lead acetate treated group, the testis showed an abnormal structure of the seminiferous tubules with vacuolar degenerative changes appearing in the cytoplasm of the spermatogenic epithelium and absence of late stage germ cells (Figure 3B). These degenerative changes caused by lead acetate were significantly rescued after treatment of rats with flaxseed oil (Figure 3D).

The measured MDA and NO levels in testicular homogenate were significantly increased after lead acetate administration (63.4 and 76.0%, $p < 0.05$), respectively, when compared with the control group (Figure 4). On the other hand, the administration of flaxseed oil only increased the level of NO of testes by 20.3%. In addition, synchronous treatment of flaxseed oil and lead acetate showed significant increase in MDA levels and NO of testes by 39.4 and 42.2%, respectively.

Lead acetate induced a significant decrease in GSH concentration by -37.3% ($p < 0.05$). However, treatment with flaxseed oil failed to recover the Pb^{+2} -induced testicular GSH depletion by -13.1%. Injection of rats with lead acetate significantly decreased the activity of CAT, SOD, GST, GPx and GR in the testicular homogenate by -28.0, -26.3, -31.8, -39.1 and -21.8%,

respectively, in comparison to the control group (Table 1). On the other hand, the change in testicular GR increased significantly in flaxseed oil group (14.8%), while the levels of testicular CAT, SOD, GST and GPx were not significantly affected in the flaxseed oil group when compared with the control animals. In addition, treatment of rats (administered lead acetate with flaxseed oil) significantly reduced the level of antioxidant enzymes in testes (CAT: -19.6%, SOD: -20.7%, GST: -14.2% and GPx: -24.5%, $p < 0.05$), while testicular GR was not significantly affected (Table 1).

The incidence of DNA fragmentation (Figure 5A) is due to necrosis and apoptosis, remembering that both cell deaths frequently occur together. Observing Figure 5, we concluded that flaxseed oil markedly reduced the fragmented DNA in testes of rats injected with lead acetate from 21 to 12% (Figure 5B).

DISCUSSION

Lead (Pb^{+2}) is a heavy metal that can be toxic when introduced into the human and animal bodies by ingestion or inhalation in sufficient quantities. It causes various destructive effects (Neathery and Miller, 1975). In human, increased levels of lead causes many serious diseases and dysfunction of organs (Gennart et al., 1992; McGregor and Mason, 1990).

The result of the present investigation showed that, lead

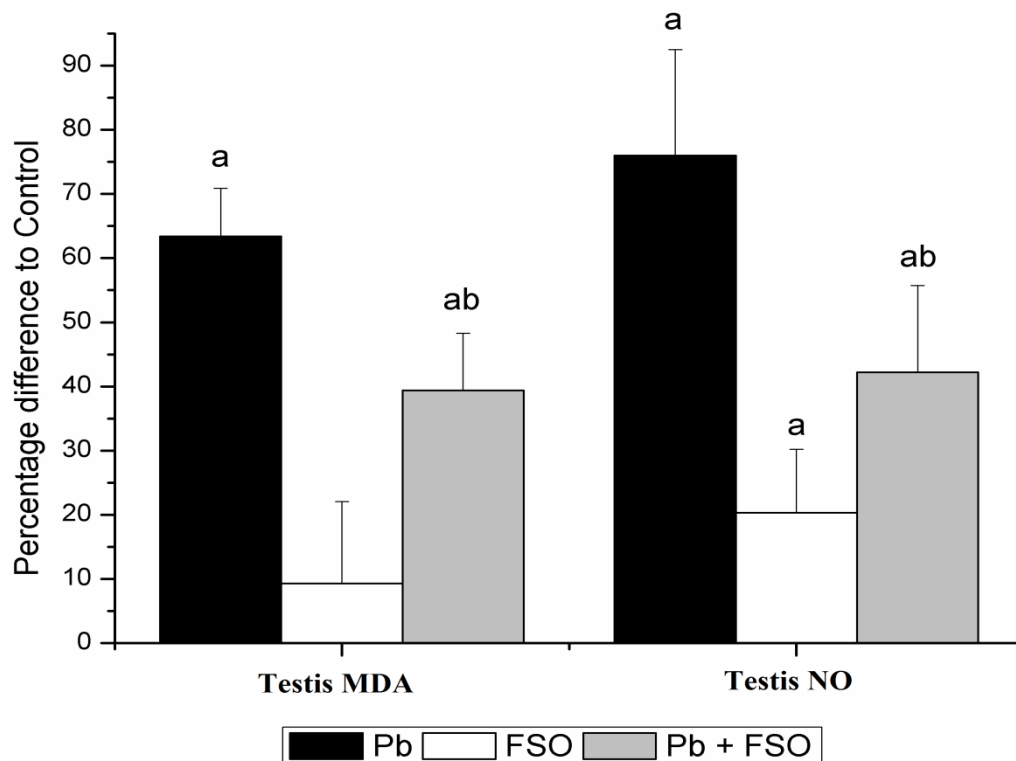


Figure 4. The percentage difference in the levels of MDA and NO in serum and testes homogenate of male rats treated with lead acetate and lead acetate + flaxseed oil. Values are means \pm SE (n = 6). a, significant change at $p < 0.05$ with respect to control group; b: significant change at $p < 0.05$ with respect to Pb^{2+} group.

Table 1. Changes in the levels of GSH, CAT, SOD, GST, GPx and GR in the testis homogenate of male rats treated with lead acetate, flaxseed oil and lead acetate + flaxseed oil.

Group	GSH (mmol/g tissue)	CAT (U/g tissue)	SOD (U/g tissue)	GST (μ mol/h/ g tissue)	GPx (U/g tissue)	GR (μ mol/ g tissue)
Con	2.52 \pm 0.08	3.21 \pm 0.12 ^a	5.89 \pm 0.23	3.02 \pm 0.13	1.69 \pm 0.07	33.65 \pm 1.56
Pb^{2+}	2.08 \pm 0.06 ^a	2.31 \pm 0.12 ^a	4.34 \pm 0.16 ^a	2.06 \pm 0.12 ^a	1.03 \pm 0.05 ^a	26.32 \pm 1.37 ^a
FSO	2.83 \pm 0.25	3.08 \pm 0.14	6.05 \pm 0.17	3.11 \pm 0.09	1.62 \pm 0.11	38.64 \pm 1.09 ^a
Pb^{2+} +FSO	2.19 \pm 0.11 ^a	2.58 \pm 0.11 ^a	4.67 \pm 0.17 ^a	2.59 \pm 0.15 ^{ab}	1.27 \pm 0.08 ^{ab}	31.09 \pm 0.96

Values are means \pm SE (n = 6). a, significant change at $p < 0.05$ with respect to control group; b, significant change at $p < 0.05$ with respect to Pb^{2+} group.

exposure caused progressive vascular, tubular and interstitial testicular damage. These findings are in agreement with Veit et al. (1983), who reported that degeneration of seminiferous tubules of turtles are exposed orally to lead. Flaxseed oil relatively improves the induced histopathological changes in the testis of rats. The study's data indicate that exposure to lead results in the inhibition of testicular function as manifested by the decreased serum testosterone level. This impairment could be due to a decrease in the number of luteinizing hormone binding sites in Leydig cells, as observed previously in testicular homogenates of lead exposed rats (Kempinas et al., 1990). Currently, the increasing interest

in the potential health benefits of estrogenic plant compounds, such as flaxseed, is leading to greater daily consumption. Some of the interest in flaxseed is attributed to its high content of the polyunsaturated fatty acid, α -linolenic acid and its high content of the lignan precursor. Babu et al. (2000) reported an increase in liver vitamin E of rats fed 10% flaxseed. Hu et al. (2007) found that flaxseed plant lignans exhibited strong antioxidant and protective effects in quenching the free radical and inhibiting peroxy-radical-mediated damage of plasmid DNA and phosphatidylcholine liposomes at potentially feasible physiological concentrations.

Lead is well known to produce oxidative damage by

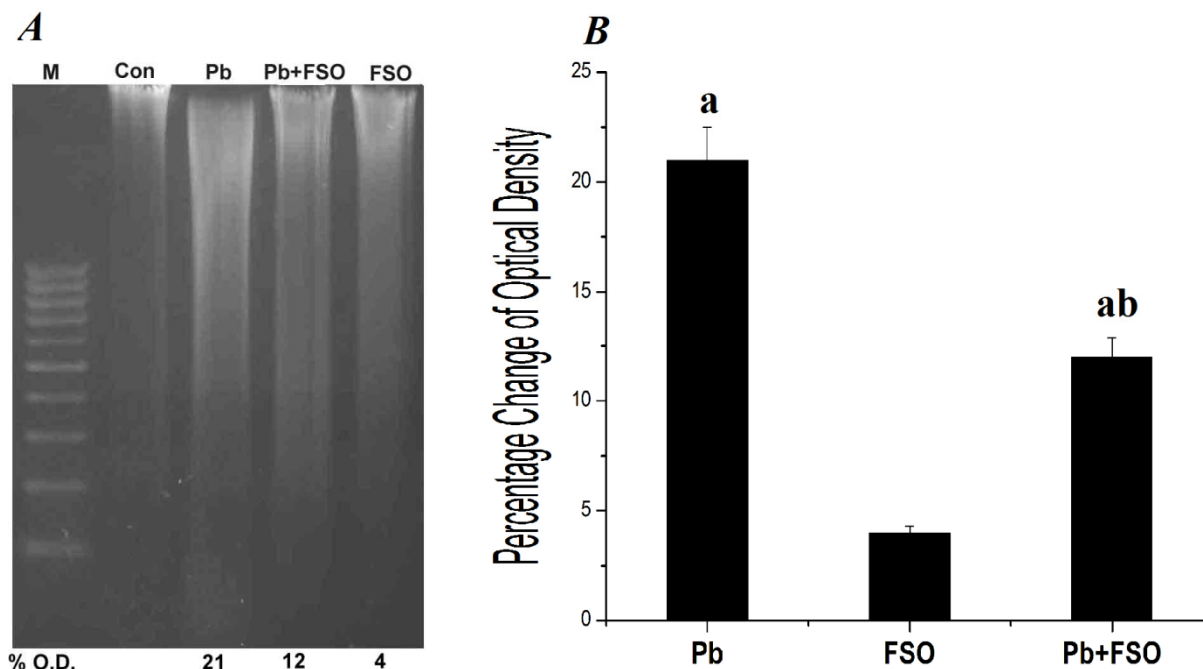


Figure 5. Effect of flaxseed oil on lead acetate induced DNA fragmentation. A, Gel electrophoresis analysis of DNA fragmentation in testes of rats treated with lead and/or flaxseed oil for 5 days; M, marker; Con, control; Pb, lead acetate; FSO, flaxseed oil and Pb+FSO; lead acetate and flaxseed oil. B, optical density (O.D) was measured as a percentage change to the control.

enhancing lipid peroxidation (Gurer et al., 1999). Lipid peroxidation inactivates cell constituents by oxidation or causes oxidative stress by undergoing radical chain reaction, ultimately leading to loss of membrane integrity (Abdel-Wahhab and Aly, 2005). In the current study, treatment with lead resulted in a significant increase in lipid peroxidation as indicated by the significant increase in MDA and the significant decrease in GSH with the antioxidant enzymes (GR, GPx, CAT, SOD and GST). In analogy, lead was shown to implicate testicular lipid peroxidation as evidenced by previous reports (Acharya et al., 2003). The stimulation of lipid peroxidation, presumably caused by lead treatment, could be due to the formation of free radicals (Abdel-Wahhab and Aly, 2005) through an exhaustion of antioxidants (Abdel-Wahhab et al., 2006; Abdel-Wahhab et al., 2007) and subsequently to oxidative stress (Shabani and Rabbani, 2000). On the other hand, since lead does not undergo oxidation-reduction cycle, the effect of lead on lipid peroxidation is not a direct effect, but these changes could rather be due to an indirect effect of lead on the free-radical scavenging enzymes and GSH status (Jindal and Gill, 1999) and/or glutathione peroxidase (Abdel-Wahhab et al., 2007). Based on this, Harlan et al. (1984) reported that the depletion of GSH caused by increased cytotoxicity of H₂O₂ in endothelial cells, resulted from the inhibition of GSH reductase and keeping GSH in its reduced state. Increased lipid peroxidation was proven to be accompanied by a reduced GSH (El-Nekeety et al.,

2009). However, the higher membrane lipid content of testes is presumed to make them more vulnerable to oxidative stress (Georgiou et al., 1987).

DNA fragmentation observed herein by the gel electrophoresis was also reported for humans exposed to Pb (II) (Danadevi et al., 2003). Such evidence may be due to a direct effect of Pb(II) on the DNA structure, oxidative mechanisms (Stohs and Bagchi, 1995) or indirectly due to another mechanism involving the activation of caspases in the process of cell death (Saleh et al., 2003). In fact, participation of lead compounds to damage DNA directly is not yet reported. However, evidences indicate that lead ions can apparently take part in a Fenton reaction to generate damaging oxygen radicals and can cause DNA strand breaks (Roy and Rossman, 1992). Moreover, lead ions are believed to decrease the fidelity of DNA synthesis. Also, some indirect mechanisms leading to inhibition of DNA polymerase B, by lead-induced reactive oxygen species (ROS), possibly indicate the failure of DNA repair mechanisms (Acharya et al., 2003).

Flaxseed oil significantly reduced NO, and it can be suggested that the active flaxseed peptide fractions may have altered the pathway for NO synthesis in the macrophages. Polyunsaturated fatty acid and α -linolenic acid has shown that the activity of potential therapeutic agents of flaxseed oil is responsible for the inhibition of NO production and subsequent inhibition of iNOS mRNA and protein expressions in macrophage (Ho and Lin,

2008; Pan et al., 2008).

In conclusion, the present study has shown a possibility of decreasing lead-induced cytotoxicity in testes leading to male infertility by supplementation with flaxseed oil.

ACKNOWLEDGEMENT

This work was gratefully supported by the centre of Excellence for Biodiversity Research, College of Science, King Saud University, Riyadh, Saudi Arabia.

REFERENCES

- Abdel-Wahhab MA, Ahmed HH, Hagazi MM (2006). Prevention of aflatoxin B1-initiated hepatotoxicity in rat by marine algae extracts. *J. Appl. Toxicol.* 26(3): 229-238.
- Abdel-Wahhab MA, Aly SE (2005). Antioxidant property of *Nigella sativa* (black cumin) and *Syzygium aromaticum* (clove) in rats during aflatoxicosis. *J. Appl. Toxicol.* 25(3): 218-223.
- Abdel-Wahhab MA, Omara EA, Abdel-Galil MM, Hassan NS, Nada SA, Saeed A, Elsayed MM (2007). *Zizyphus spina-christi* extract protects against aflatoxin b(1)-initiated hepatic carcinogenicity. *Afr. J. Tradit. Complement Altern. Med.* 4(3): 248-256.
- Acharya UR, Acharya S, Mishra M (2003). Lead acetate induced cytotoxicity in male germinal cells of Swiss mice. *Ind. Health*, 41(3): 291-294.
- Aebi H (1984). Catalase *in vitro*. *Methods Enzymol.* 105: 121-126.
- Babu US, Mitchell GV, Wiesenfeld P, Jenkins MY, Gowda H (2000). Nutritional and hematological impact of dietary flaxseed and defatted flaxseed meal in rats. *Int. J. Food Sci. Nutr.* 51(2): 109-117.
- Berkels R, Puroh-Schnabel S, Roesen R (2004). Measurement of nitric oxide by reconversion of nitrate/nitrite to NO. *Methods Mol. Biol.* 279: 1-8.
- Bhatia AL, Sharma A, Patni S, Sharma AL (2007). Prophylactic effect of flaxseed oil against radiation-induced hepatotoxicity in mice. *Phytother. Res.* 21(9): 852-859.
- Craig WJ (1999). Health-promoting properties of common herbs. *Am. J. Clin. Nutr.* 70(3): 491S-499S.
- Danadevi K, Rozati R, Saleha Banu B, Hanumanth Rao P, Grover P (2003). DNA damage in workers exposed to lead using comet assay. *Toxicology*, 187(2-3): 183-193.
- Duzgoren-Aydin NS (2007). Sources and characteristics of lead pollution in the urban environment of Guangzhou. *Sci. Total Environ.* 385(1-3): 182-195.
- El-Nekeety AA, El-Kady AA, Soliman MS, Hassan NS, Abdel-Wahhab MA (2009). Protective effect of *Aquilegia vulgaris* (L.) against lead acetate-induced oxidative stress in rats. *Food Chem. Toxicol.* 47(9): 2209-2215.
- Factor VM, Kiss A, Woitach JT, Wirth PJ, Thorgeirsson SS (1998). Disruption of redox homeostasis in the transforming growth factor- α /c-myc transgenic mouse model of accelerated hepatocarcinogenesis. *J. Biol. Chem.* 273(25): 15846-15853.
- Flora SJ, Bhattacharya R, Vijayaraghavan R (1995). Combined therapeutic potential of meso-2,3-dimercaptosuccinic acid and calcium disodium edetate on the mobilization and distribution of lead in experimental lead intoxication in rats. *Fundamental Appl. Toxicol.* 25(2): 233-240.
- Flora SJ, Pande M, Mehta A (2003). Beneficial effect of combined administration of some naturally occurring antioxidants (vitamins) and thiol chelators in the treatment of chronic lead intoxication. *Chem. Biol. Interact.* 145(3): 267-280.
- Gennart JP, Bernard A, Lauwerys R (1992). Assessment of thyroid, testes, kidney and autonomic nervous system function in lead-exposed workers. *Int. Arch. Occup. Environ. Health*, 64(1): 49-57.
- Georgiou M, Perkins LM, Payne AH (1987). Steroid synthesis-dependent, oxygen-mediated damage of mitochondrial and microsomal cytochrome P-450 enzymes in rat Leydig cell cultures. *Endocrinology*, 121(4): 1390-1399.
- Gurer H, Neal R, Yang P, Oztezcan S, Ercal N (1999). Captopril as an antioxidant in lead-exposed Fischer 344 rats. *Hum. Exp. Toxicol.* 18(1): 27-32.
- Habig WH, Pabst MJ, Jakoby WB (1974). Glutathione S-transferases. The first enzymatic step in mercapturic acid formation. *J. Biol. Chem.* 249(22): 7130-7139.
- Harlan JM, Levine JD, Callahan KS, Schwartz BR, Harker LA (1984). Glutathione redox cycle protects cultured endothelial cells against lysis by extracellularly generated hydrogen peroxide. *J. Clin. Invest.* 73(3): 706-713.
- Ho SC, Lin CC (2008). Investigation of heat treating conditions for enhancing the anti-inflammatory activity of citrus fruit (*Citrus reticulata*) peels. *J. Agric. Food Chem.* 56(17): 7976-7982.
- Hsu PC, Hsu CC, Liu MY, Chen LY, Guo YL (1998). Lead-induced changes in spermatozoa function and metabolism. *J. Toxicol. Environ. Health A*, 55(1): 45-64.
- Hsu PC, Liu MY, Hsu CC, Chen LY, Leon Guo Y (1997). Lead exposure causes generation of reactive oxygen species and functional impairment in rat sperm. *Toxicology*, 122(1-2): 133-143.
- Hu C, Yuan YV, Kitts DD (2007). Antioxidant activities of the flaxseed lignan secoisolariciresinol diglucoside, its aglycone secoisolariciresinol and the mammalian lignans enterodiol and enterolactone *in vitro*. *Food Chem. Toxicol.* 45(11): 2219-2227.
- Ito Y, Niya Y, Kurita H, Shima S, Sarai S (1985). Serum lipid peroxide level and blood superoxide dismutase activity in workers with occupational exposure to lead. *Int. Arch. Occup. Environ. Health*, 56(2): 119-127.
- Jindal V, Gill KD (1999). Ethanol potentiates lead-induced inhibition of rat brain antioxidant defense systems. *Pharmacol. Toxicol.* 85(1): 16-21.
- Joshi UM, Shah HP, Sudhama SP (1979). A sensitive and specific enzymeimmunoassay for serum testosterone. *Steroids*, 34(1): 35-46.
- Kempinas WG, Melo VR, Oliveira-Filho RM, Santos AC, Favaretto AL, Lamano-Carvalho TL (1990). Saturnism in the male rat: endocrine effects. *Braz. J. Med. Biol. Res.* 23(11): 1171-1175.
- McGregor AJ, Mason HJ (1990). Chronic occupational lead exposure and testicular endocrine function. *Hum. Exp. Toxicol.* 9(6): 371-376.
- Neathery MW, Miller WJ (1975). Metabolism and toxicity of cadmium, mercury, and lead in animals: a review. *J. Dairy Sci.* 58(12): 1767-1781.
- Nishikimi M, Appaji N, Yagi K (1972). The occurrence of superoxide anion in the reaction of reduced phenazine methosulfate and molecular oxygen. *Biochem. Biophys. Res. Commun.* 46(2): 849-854.
- Ohkawa H, Ohishi N, Yagi K (1979). Assay for lipid peroxides in animal tissues by thiobarbituric acid reaction. *Anal. Biochem.* 95(2): 351-358.
- Paglia DE, Valentine WN (1967). Studies on the quantitative and qualitative characterization of erythrocyte glutathione peroxidase. *J. Lab. Clin. Med.* 70(1): 158-169.
- Pan MH, Chang YH, Tsai ML, Lai CS, Ho SY, Badmaev V, Ho CT (2008). Pterostilbene suppressed lipopolysaccharide-induced up-expression of iNOS and COX-2 in murine macrophages. *J. Agric. Food Chem.* 56(16): 7502-7509.
- Patra RC, Swarup D, Dwivedi SK (2001). Antioxidant effects of alpha tocopherol, ascorbic acid and L-methionine on lead induced oxidative stress to the liver, kidney and brain in rats. *Toxicology*, 162(2): 81-88.
- Patrick L (2006). Lead toxicity part II: the role of free radical damage and the use of antioxidants in the pathology and treatment of lead toxicity. *Altern. Med. Rev.* 11(2): 114-127.
- Roy NK, Rossman TG (1992). Mutagenesis and comutagenesis by lead compounds. *Mutat. Res.* 298(2): 97-103.
- Saleh AM, Vijayasathay C, Masoud L, Kumar L, Shahin A, Kambal A (2003). Paraoxon induces apoptosis in EL4 cells via activation of mitochondrial pathways. *Toxicol. Appl. Pharmacol.* 190(1): 47-57.
- Sandhir R, Julka D, Gill KD (1994). Lipoperoxidative damage on lead exposure in rat brain and its implications on membrane bound enzymes. *Pharmacol. Toxicol.* 74(2): 66-71.
- Shabani A, Rabbani A (2000). Lead nitrate induced apoptosis in alveolar macrophages from rat lung. *Toxicology*, 149(2-3): 109-114.
- Stohs SJ, Bagchi D (1995). Oxidative mechanisms in the toxicity of metal ions. *Free Radic. Biol. Med.* 18(2): 321-336.
- Tsakiris S, Schulpis KH, Marinou K, Behrakis P (2004). Protective effect

- of L-cysteine and glutathione on the modulated suckling rat brain Na⁺, K⁺, -ATPase and Mg²⁺ -ATPase activities induced by the *in vitro* galactosaemia. *Pharmacol. Res.* 49(5): 475-479.
- Veit HP, Kendall RJ, Scanlon PF (1983). The effect of lead shot ingestion on the testes of adult ringed turtle doves (*Streptopelia risoria*). *Avian Dis.* 27(2): 442-452.
- Watabe M, Masuda Y, Nakajo S, Yoshida T, Kuroiwa Y, Nakaya K (1996). The cooperative interaction of two different signaling pathways in response to bufalin induces apoptosis in human leukemia U937 cells. *J. Biol. Chem.* 271(24): 14067-14072.
- Zheng W, Aschner M, Gherzi-Egea JF (2003). Brain barrier systems: a new frontier in metal neurotoxicological research. *Toxicol. Appl. Pharmacol.* 192(1): 1-11.