

African Journal of Biotechnology Vol. 10(51), pp. 10516-10519, 7 September, 2011

Available online at <http://www.academicjournals.org/AJB>

DOI: 10.5897/AJB11.599

ISSN 1684-5315 © 2011 Academic Journals

## Full Length Research Paper

# Comparison of apical sealing ability of resected mineral trioxide aggregate, gutta-percha and a resin-based root canal filling material (resilon)

Mohammad Froughreyhani<sup>1</sup>, Amin Salem Milani<sup>2</sup>, Saeed Rahimi<sup>1</sup>, Sahar Shakouie<sup>1</sup> and Somaieh Fateh<sup>3</sup>

<sup>1</sup>Department of Endodontics, Faculty of Dentistry, Tabriz University of Medical Sciences, Tabriz, Iran.

<sup>2</sup>Dental and Periodontal Disease Research Center, Faculty of Dentistry, Tabriz University of Medical Sciences, Tabriz, Iran.

<sup>3</sup>Dentist, Private practice, Tabriz, Iran.

Accepted 18 July, 2011

**In the case of limited access in endodontic surgery, an alternative approach includes obturation of the canal with mineral trioxide aggregate (MTA) prior to surgery. Following the setting of MTA, endodontic surgery is carried out by resecting the root-end and exposing the set MTA without cavity preparation. This may also be performed with other retrofilling materials. This study was designed to compare the sealing ability of resected resilon, MTA and gutta-percha. 84 maxillary anterior teeth were instrumented and randomly assigned into three experimental groups (n = 20), each having a positive and negative control (n = 4). The canals were filled with resilon, MTA or gutta-percha. Following the root-end resection and submergence in India ink, the maximum dye penetration was measured. Welch and Brown-Forsythe test was used to analyze the data. The resected gutta-percha showed significantly more leakage than MTA (p = 0.041). The leakage in resected resilon was more than MTA and slightly lesser than gutta-percha. However, the differences were not statistically significant (p > 0.05). Based on this study, MTA is the most appropriate choice in this approach.**

**Key words:** Gutta-percha, microleakage, mineral trioxide aggregate, resilon, root-end resection.

## INTRODUCTION

Endodontic surgery is often conducted when non-surgical endodontic treatment is unsuccessful. It includes root-end resection, retrocavity preparation and the placement of a root-end filling (Gutmann and Harrison, 1994). A variety of materials have been proposed to fill the retrocavities including gutta-percha, amalgam, zinc oxide-eugenol, dentin bonding agents, glass-ionomer cements and other restorative materials (De Bruyne and De Moor, 2009).

Mineral trioxide aggregate (MTA) was introduced in 1993 as a root-end filling material (Torabinejad et al., 1993). MTA has excellent biocompatibility and sealing ability (Lee et al., 1993; Torabinejad et al., 1993, 1994,

1995a, b, 1997; Fischer et al., 1998; De Bruyne and De Moor, 2004), and is considered by many clinicians as gold standard of retrofilling materials (Nicholson et al., 1991; Asrari and Lobner, 2003; Pistorius et al., 2003; Sousa et al., 2004).

Recently, a thermoplastic synthetic polycaprolactone-based polymer, resilon/epiphany system (Pentron Clinical Technologies, LLC Wallingford, CT), has been introduced as a root canal filling material (Shipper et al., 2004). The resilon core material is used with the epiphany dual-cured sealer and self-etching primer to form a "monoblock" in the root canal system (Shipper et al., 2004, 2005). The resilon/epiphany system has shown excellent biocompatibility (Maltezos et al., 2006). The manufacturer claims that this system has similar handling properties as gutta-percha, provides higher flexural strength than gutta-percha, strengthens the root, and can be removed by solvents and heat (Maltezos et al., 2006). This material has been used as root-end filling material and showed

\*Corresponding author. E-mail: [Amin.salemmilani@gmail.com](mailto:Amin.salemmilani@gmail.com).  
Tel: +98(411)3355965.

**Abbreviation:** MTA, Mineral trioxide aggregate.

similar sealing ability as MTA and superior sealing than Super-EBA (Maltezos et al., 2006). One of the properties of this system is its immediate setting by light which is an advantage in endodontic surgery where isolation of the root-end cavity is difficult to maintain.

Placement of MTA or resilon into the root-end cavity has some difficulties. Special consistency of MTA makes it difficult to deliver and compact into the root-end cavity, and long setting time increases the possibility of washing out during the first hours after surgery (Kogan et al., 2006). Resilon/epiphany system is technique sensitive and contamination with water or blood during surgery leads to reduced bonding to dentin and increased microleakage (Shipper et al., 2004). Under some circumstances, when access to the surgical site is limited, an alternative approach includes obturation of the root canal with MTA prior to surgery. Following the setting of MTA, endodontic surgery is carried out by resecting the root-end and exposing the set MTA without cavity preparation (Andelin et al., 2002). There are also some situations where MTA may be used to fill the entire root canal. In these instances, if endodontic surgery is subsequently required, the clinician may choose this alternative approach (Andelin et al., 2002).

The main concern of this method is the sealing ability of the resected MTA or resilon. Andelin et al. (2002) showed that the resection of set MTA does not affect its sealing ability. It was confirmed in another *in vitro* study which showed that the root resection did not affect the sealing ability of MTA when at least 3 mm of the MTA remained (Lamb et al., 2003). There is no published data on the evaluation of the sealing ability of resected Resilon. Therefore, this study was designed to compare the sealing ability of resected roots filled with resilon, MTA, or gutta-percha.

## MATERIALS AND METHODS

### Sample selection

84 human maxillary anterior teeth with mature apices which were extracted due to the periodontal disease were selected for this study. The inclusion criteria were the root length of at least 12 mm and an initial apical size no greater than ISO size 20. All teeth were cleaned free of attached periodontal tissues using periodontal curette, then autoclaved and stored in 0.5% chloramine T solution until use.

### Sample preparation

Access cavities were prepared using a #2 diamond round bur (Tizkavan, Tehran, Iran) in a high-speed handpiece under water spray. The working length was measured by introducing a #15 K-file into the canal until the file-end was visible at the apex. One millimeter was subtracted from this length and recorded as the working length. The coronal flaring was carried out using # 3,4 Gates-Glidden burs. Then, RaCe rotary file size 40, 0.1 taper (FKG Dentaire, Switzerland) was used to enlarge middle third of the canals. The apical portion was enlarged to ISO size 50 file using

stainless steel k-files (Maillefer, Ballagius, Switzerland). A total of 10 ml of 5.25% NaOCl was used to irrigate the canals during instrumentation. Finally, 2.5 ml of 17% EDTA was used as final irrigant followed by 5 ml normal saline. The teeth were randomly divided into three experimental groups of 20 teeth each, three positive and three negative control groups of 4 teeth each. The control groups were used to check the accuracy of the procedures and to ensure that the results would be only affected by the sealing ability of the materials used.

### Obturation of the canals

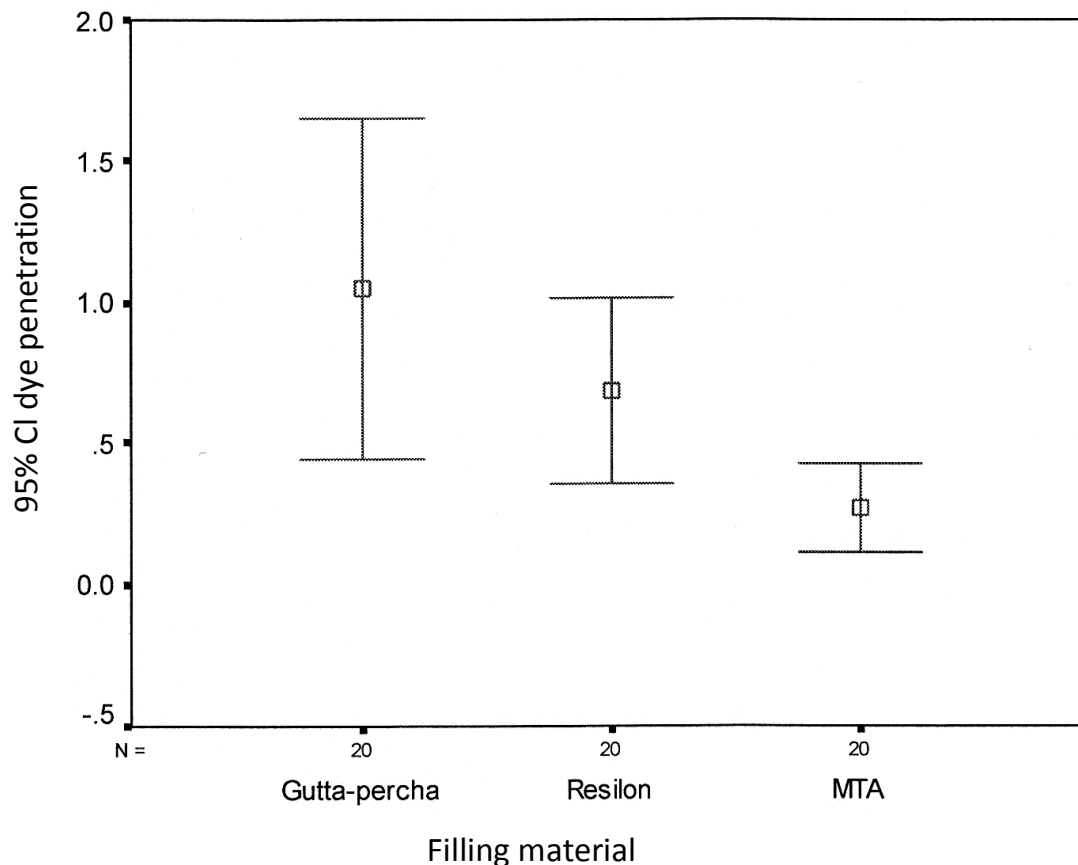
In experimental group 1, the canals were cwith resilon/epiphany system (Pentron Clinical Technologies, LLC Wallingford, CT) using warm vertical compaction. A size 50 resilon cone was fit, and a radiograph was obtained to confirm the length. After drying the canal with paper points, the self-etch epiphany primer was applied in the canal for 30 s using paper points. Then, the dual cure epiphany sealer was placed in the canal using lentulo spiral, and the master cone was placed in the canal. The coronal portion was removed with heat carrier. A proper plugger was used to compact the resilon filling. Then, 2 to 3 mm of the coronal filling was removed using heat carrier, and the remained filling was vertically compacted. This process was repeated until the apical portion was filled. The remaining part of the canal was backfilled by placing 3 to 4 mm sections of resilon into the root, applying heat, and compacting the mass with a plugger. Finally, the coronal segment was light cured for 40 s. In the control teeth of group 1, the canals were filled using the earlier-mentioned procedure except that the canals in positive control were filled without sealer.

In experimental group 2, the canals were obturated with gutta-percha (Gapadent, Germany) and AH26 sealer (Dentsply, Germany) using warm vertical compaction as mentioned for group 1. In the control teeth of group 2, the canals were filled using the same process except that the canals in the positive control were filled without sealer.

In experimental group 3, the apical 3 mm of the canals were filled with white MTA (ProRoot MTA, Dentsply, Tulsa Dental, Tulsa, OK). The root-ends of the teeth were placed on a moistened oasis sponge to provide an apical stop. MTA was mixed with distilled water according to the manufacturer's instructions and incrementally placed into the canal using an MTA carrier (Medesy, Italy). The material was then compacted using paper points and prefitted Schilder pluggers (Dentsply Caulk, Milford, DE) until the apical 6 mm of the canal was filled. The length and density of the filling were checked by radiography. Then, a damp cotton pellet was placed into the canal over the MTA. The access cavity was sealed with Cavit (ESPE Dental, Seefeld, Germany). In negative control of group 3, the canals were filled with MTA using the earlier mentioned process. The canals in the positive control were not filled. All the samples were incubated at 37°C and 100% humidity for seven days.

### Leakage test

After the incubation period, the apical 3 mm of the roots were resected perpendicular to the long axis of the teeth using a fissured diamond bur (Tizkavan, Tehran, Iran) in a high-speed handpiece. Then, all the surfaces in experimental groups except the apical 2 mm were covered by two layers of nail varnish. In the negative control, all the root surfaces were covered by two layers of nail varnish. In the positive control, the roots were not covered. All the teeth were then submerged in Indian ink. After 48 h, the teeth were rinsed and grooved on the buccal and lingual surfaces and split into two sections. Maximum dye penetration was measured with a stereomicroscope (Carl Zeiss, Germany) at 16× magnification to the



**Figure 1.** Error bar illustrating the mean of maximum dye penetration into the canals after apical resection of roots filled with MTA, gutta-percha and resilon.

nearest 0.1 mm.

#### Statistical analysis

Statistical analysis was performed with SPSS for windows (SPSS Inc, Chicago, IL). Welch and Brown-Forsythe test was used to evaluate the statistical significance of differences due to the heterogeneity of variances. Games-Howell post hoc test was used for pairwise comparison. The significance level was set at  $p < 0.05$ .

#### RESULTS AND DISCUSSION

All the canals in the positive control groups demonstrated leakage throughout the entire root canal. The canals in the negative control groups did not display any leakage. The resected gutta-percha showed significantly more leakage than MTA ( $p = 0.041$ ). The leakage in resilon group was more than MTA group and slightly lesser than gutta-percha (Figure 1). However, the differences were not statistically significant ( $p > 0.05$ ) (Table 1).

There are some circumstances where difficult access and isolation make placement of retrofilling materials very difficult. Studies have shown that root-end resection does not affect the sealing ability of MTA placed in an orthograde

manner (Andelin et al., 2002; Lamb et al., 2003). Therefore, an alternative approach to retrofill placement is the obturation of the root canal with MTA prior to surgery, allowing adequate time for the material to set, and then resecting the apical 3 mm of the root without the need for a root-end preparation and root-end filling (Lamb et al., 2003). This approach may be possible with other retrofill materials if root resection does not influence their sealing ability. One of the retrofilling materials with favorable characteristics is the resilon which originally has been introduced as a root canal filling material (Shipper et al., 2004); however, it has also been used as retrofilling material (De Bruyne and De Moor, 2009). The resilon core material is used with the epiphany sealer to form a "monoblock" in the root canal (Shipper et al., 2004, 2005). One of the properties of this system is its immediate setting by light which is an advantage in endodontic surgery where isolation of the cavity is difficult to maintain. When used as root-end filling material, resilon showed similar sealing ability as MTA and superior sealing than Super-EBA (Maltezos et al., 2006). An *in vitro* study by De Bruyne et al. (2009) showed that the sealing ability of resilon was better than MTA in the short-term. In our study, MTA samples showed less

**Table 1.** Maximum dye penetration into the canals after apical resection of roots filled with MTA, gutta-percha and resilon.

Parameter	Dye penetration (mm)	
	Mean	Standard deviation
Gutta-percha <sup>a</sup>	1.05	1.30
Resilon <sup>a,b</sup>	0.69	0.71
MTA <sup>b</sup>	0.27	0.34

Groups identified by the same superscript letters are not significantly different ( $p > 0.05$ ); different letters identify significantly different groups ( $p < 0.05$ ); MTA: mineral trioxide aggregate.

leakage than resilon or gutta-percha after resection with statistically significance in the case of MTA and gutta-percha. Based on these results, if limited access and isolation is not used for retrofill placement, MTA is still the better choice than resilon to fill the canal prior to root-end resection. However, in the cases of curved canals, when placement of MTA is difficult, it is possible to use resilon as a substitution of MTA in this approach. Considering the limitations of dye leakage studies, it is recommended that sealing ability of resected resilon and MTA be also evaluated with other leakage tests, and like studies on MTA, sealing ability of canals filled with resilon should be compared before and after root-end resection.

## REFERENCES

- Andelin WE, Browning DF, Hsu GH, Roland DD, Torabinejad M (2002). Microleakage of resected MTA. *J. Endod.*, 28: 573-574.
- Asrari M, Lobner D (2003). *In vitro* neurotoxic evaluation of root-end-filling materials. *J. Endod.*, 29: 743-746.
- De Bruyne MA, De Moor RJ (2004). The use of glass ionomer cements in both conventional and surgical endodontics. *Int. Endod. J.* 37: 91-104.
- De Bruyne MA, De Moor RJ (2009). Long-term sealing ability of Resilon apical root-end fillings. *Int. Endod. J.* 42: 884-892.
- Fischer EJ, Arens DE, Miller CH (1998). Bacterial leakage of mineral trioxide aggregate as compared with zinc-free amalgam, intermediate restorative material, and Super-EBA as a root-end filling material. *J. Endod.*, 24: 176-179.
- Gutmann JL, Harrison JW (1994). *Surgical endodontics*. St. Louis: Ishiyaku EuroAmerica.
- Kogan P, He J, Glickman GN, Watanabe I (2006). The effects of various additives on setting properties of MTA. *J. Endod.*, 32: 569-572.
- Lamb EL, Loushine RJ, Weller RN, Kimbrough WF, Pashley DH (2003). Effect of root resection on the apical sealing ability of mineral trioxide aggregate. *Oral surgery, oral medicine, oral pathology, oral radiology, and endodontics*, 95: 732-735.
- Lee SJ, Monsef M, Torabinejad M (1993). Sealing ability of a mineral trioxide aggregate for repair of lateral root perforations. *J. Endod.* 19: 541-544.
- Maltezos C, Glickman GN, Ezzo P, He J (2006). Comparison of the sealing of Resilon, Pro Root MTA, and Super-EBA as root-end filling materials: a bacterial leakage study. *J. Endod.*, 32: 324-327.
- Nicholson JW, Braybrook JH, Wasson EA (1991). The biocompatibility of glass-poly(alkenoate) (Glass-Ionomer) cements: A review. *J. Biomater. Sci. Polym.*, Ed 2: 277-285.
- Pistorius A, Willershausen B, Briseno Marroquin B (2003). Effect of apical root-end filling materials on gingival fibroblasts. *Int. Endod. J.*, 36: 610-615.
- Shipper G, Orstavik D, Teixeira FB, Trope M (2004). An evaluation of microbial leakage in roots filled with a thermoplastic synthetic polymer-based root canal filling material (Resilon). *J. Endod.*, 30: 342-347.
- Shipper G, Teixeira FB, Arnold RR, Trope M (2005). Periapical inflammation after coronal microbial inoculation of dog roots filled with gutta-percha or resilon. *J. Endod.*, 31: 91-96.
- Sousa CJ, Loyola AM, Versiani MA, Biffi JC, Oliveira RP, Pascon EA (2004). A comparative histological evaluation of the biocompatibility of materials used in apical surgery. *Int. Endod. J.*, 37: 738-748.
- Torabinejad M, Higa RK, McKendry DJ, Pitt Ford TR (1994). Dye leakage of four root end filling materials: effects of blood contamination. *J. Endod.*, 20: 159-163.
- Torabinejad M, Hong CU, Lee SJ, Monsef M, Pitt Ford TR (1995a). Investigation of mineral trioxide aggregate for root-end filling in dogs. *J. Endod.*, 21: 603-608.
- Torabinejad M, Pitt Ford TR, McKendry DJ, Abedi HR, Miller DA, Kariyawasam SP (1997). Histologic assessment of mineral trioxide aggregate as a root-end filling in monkeys. *J. Endod.*, 23: 225-228.
- Torabinejad M, Rastegar AF, Kettering JD, Pitt Ford TR (1995b). Bacterial leakage of mineral trioxide aggregate as a root-end filling material. *J. Endod.*, 21: 109-112.
- Torabinejad M, Watson TF, Pitt Ford TR (1993). Sealing ability of a mineral trioxide aggregate when used as a root end filling material. *J. Endod.*, 19: 591-595.