

Full Length Research Paper

Antimicrobial efficacy and tissue reaction of *Euphorbia hirta* ethanolic extract on canine wounds

J. F. Akinrinmade* and O. A. Oyeleye

Department of Veterinary Surgery and Reproduction, Faculty of Veterinary Medicine, University of Ibadan, Oyo State, Nigeria.

Accepted 22 March, 2010

Antimicrobial efficacy and tissue reaction of crude ethanolic extract of *Euphorbia hirta* was investigated in canine infected incised wounds. The gross appearance and histopathological reactions of the lesions were evaluated at 72 h after treatment. The results showed that crude ethanolic extract of *E. hirta* neither promoted the growth of *Staphylococcus aureus* nor provoked tissue reaction in canine wounds. It was concluded that infected wound would benefit from treatment with ethanolic extract of *E. hirta* and its use in surgical site preparation is thus recommended.

Key words: Antimicrobial, efficacy, tissue reaction, *Euphorbia hirta*, canine wounds.

INTRODUCTION

Surgical or traumatic cutaneous wounds are common features of human and veterinary surgical practice. In most cases, such wounds heal normally and without complications, while in some, healing is delayed or disrupted due to factors such as nutritional deficiencies, impairment of blood supply, poor wound care and infection among others. Of all these factors, wound infection remains a major concern for the surgeon, the patient and the client. Different treatment modalities had been used in the management of wound infections with varying results (Gruber et al., 1975; Kaul and Jewett, 1981; Hirsh (Check spelling) and Spencer, 1995).

Besides their use in wounds, antiseptics are used to kill bacteria on the skin of patient before surgery, to scrub the hands of surgeons and reduce bacterial load for various skin graft procedures. Thus, in order to minimize wound infection with its attendant fatal consequences, a preparation with a broad antimicrobial spectrum and one that does not provoke hypersensitivity reaction in the patient is highly desirable. Wound preparations abound with antimicrobial properties but declining clinical efficacy due to the emergence of multi-drug resistant pathogens (Bandow et al., 2005). Of the numerous organisms that colonize wounds, wound care experts have found

Staphylococcus aureus, *Pseudomonas aeruginosa* and Beta-haemolytic *Streptococcus* as the most likely bacterial strains which cause delayed wound healing and infection (Bowler, 1998; Bowler et al., 2001; Athanasopoulos et al., 2006). In view of the global concern generated by the emergence of antimicrobial resistance to synthetic products, *Euphorbia hirta*, a tropical herb is currently receiving research attention with regard to its antimicrobial and antiseptic properties. Extract of the plant has been used in the treatment of boils, sore and promotion of wound healing in Nigeria with satisfactory results (Igoli et al., 2005). This study evaluated the antimicrobial efficacy and tissue reaction prospects of crude ethanolic extract of *E. hirta* on canine wounds.

MATERIALS AND METHODS

Plant materials

E. hirta plants were collected within the University of Ibadan community in the month of June. The taxonomic identity of the plant was confirmed in the Departments of Veterinary Physiology and Pharmacology and Botany and Microbiology, University of Ibadan. A voucher specimen was also deposited in the research laboratories of the above departments.

Extraction of *Euphorbia hirta*

Twenty grams (20 g) of the fine powder of the dried leaves was

*Corresponding author. E-mail: fadeyemiakinrinmade@yahoo.com.

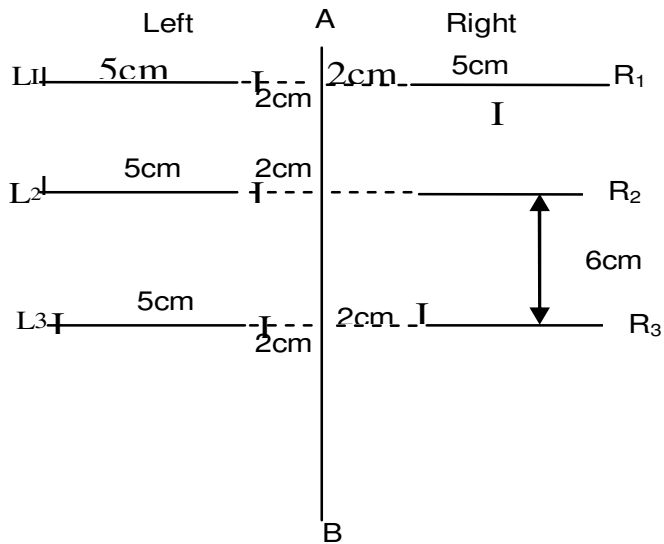


Figure 1. Diagram of the 3 paired dorsoventral skin incisions evenly spaced on both sides of the dorsal midline of each dog. R₁, L₁ = *Euphorbia hirta* treatment; R₂, L₂ = saline treatment; R₃, L₃ = no treatment; Left = not infected; Right = infected; and A B = dorsal midline.

extracted with 95% ethanol according to the method of Al-Mughrabi (2003) while the techniques of Akujobi et al. (2004) and Esimone et al. (1998) were adopted for the preparations of dilutions of the crude extract for the study.

Preparation of inoculum

The test organism used in this study was obtained from the Department of Microbiology and Parasitology of the University of Ibadan. Pure culture of *S. aureus* containing a concentration of 0.5×10^7 cfu/ml of inoculum, suspended in saline solution were obtained according to the method of Amber et al. (1983).

Surgical wound creation, infection and treatment

Four clinically healthy, mongrel dogs between 10.5 and 12 kg were used for the investigation with the approval of the ethical committee of the Faculty of Veterinary Medicine. The dogs were maintained to be in good health based on the results of routine clinical and haematological examinations as well as floatation test for helminth eggs. The back of each dog was clipped from the neck to the lumbosacral region and laterally to a line from the costochondral junction to the stifle. The dogs were premedicated with atropine sulphate (0.04 mg/kgi/m) and xylazine (2 mg/kgi/m) while anaesthesia was induced and maintained with 6% pentobarbitone (10 mg/kgi/v).

The clipped area was scrubbed with soap, defatted and finally scrubbed with hibitane. The dogs were positioned in external recumbency and intended surgical sites isolated by the use of sterile drapes. Using sterile techniques, three paired, 5 cm dorsoventral skin incisions were evenly spaced 6 cm apart on both sides of the dorsal midline and 2 cm away from the dorsal midline (Figure 1). Each incision was standardized in length, size and position by using a radiographic film template. Hemostasis was achieved with gauze sponges and digital pressure. Each of the three incised wounds on the right side of the dorsal midline (R₁,

R₂ and R₃) was instilled with 1 ml each of *S. aureus* culture containing 0.5×10^7 cfu/ml while none of the wounds on the left (L₁, L₂ and L₃) was infected. All wounds were left for 2 h followed by the irrigation of wound R₁ with 10 ml of standardized ethanolic extract of *E. hirta* and wound R₂, with 10 ml of normal saline while wound R₃ was left intact unirrigated. The uninfected wounds on the left (L₁, L₂ and L₃) were similarly treated as in wounds R₁, R₂ and R₃. Irrigation was done with the use of plastic syringe with G-21 hypodermic needle attached. Wounds awaiting treatment were closed with forceps and covered with sterile gauze sponges to prevent splash contamination of the wounds by bacteria and or *E. hirta* extract. All wounds were closed with 2-0- monofilament nylon sutures using horizontal mattress pattern. The dogs were taken to the recovery room with improvised basket collar on the neck to prevent mutilation of surgical wounds. The animals were euthanized 3 days after surgery and wounds scanned for gross macroscopic changes. Biopsies were taken aseptically to produce a cross-section of the skin and sub- cutis from each wound as well as from normal skin in the same area. The tissues were routinely processed, stained with haematoxylin and eosin and examined for microscopic changes. The degree of skin and sub-cutis inflammation was rated on a scale of 0 to 4 that is, 0 = normal; 1 = minimal; 2 = mild; 3 = moderate and 4 = severe neutrophilic infiltration.

Statistical analysis

The means of rating for macroscopic and microscopic (neutrophilic infiltration) were calculated and compared using analysis of variance (ANOVA). Mean differences were considered significant at $P < 0.05$.

RESULTS AND DISCUSSION

Gross and microscopic evidence of infections were observed in all wounds at 72 h after inoculation. The prevalence of the infection however varied from 25 to 100% (Table 1). The incidence of infection was least in wounds treated with *E. hirta* extract. The mean neutrophilic count was significantly lower ($P < 0.05$) in infected *E. hirta* treated wounds than the other infected and non-infected untreated wounds (Table 2). *E. hirta* extract provoked the least inflammatory cellular reaction in infected and treated wounds as compared to other infected and uninfected untreated wounds. No significant ($P > 0.05$) tissue reaction occurred in non-infected treated and untreated wounds. All the wounds in this group showed minimal neutrophilic infiltration. There was however a significantly higher ($P < 0.05$) tissue reaction in the infected, treated and untreated wounds as compared to the non-infected, treated and untreated wounds (Table 3). The wounds in this group were characterized by moderate to severe neutrophilic infiltration.

Acute inflammatory changes occurred in all the wounds during the early stages. Usually, the changes persist for 3 - 5 days and then disappear. These inflammatory changes that tend to appear quickly as a wound is created surgically or otherwise, was used in the present study to evaluate the antimicrobial efficacy and tissue reaction of *E. hirta* extract on canine incised wounds. Of the organisms used to evaluate antibacterial efficacy,

Table 1. Number of infections seen 72 h following irrigation of experimentally infected and non-infected wounds with ethanolic extract of *Euphorbia hirta*.

Description of Wounds	Total number of wound inoculated	Wounds with gross infection	Wounds with microscopic infection
Infected wounds			
<i>Euphorbia hirta</i> extract irrigated wounds R ₁	4	1 (25%)	1 (25%)
Normal saline irrigated wounds R ₂	4	4 (100%)	4 (100%)
Wound not irrigated with neither saline nor <i>Euphorbia hirta</i> extract R ₃	4	4 (100%)	4 (100%)
Non-infected wounds			
<i>Euphorbia hirta</i> extract irrigated wounds L ₁	4	NIL	NIL
Normal saline irrigated wounds L ₂	4	2 (50%)	2 (50%)
Wounds not irrigated with neither saline nor <i>E. hirta</i> extract L ₃	4	2 (50%)	2 (50%)

Table 2. Mean scores of inflammatory cell counts in infected and non-infected *Euphorbia hirta* treated wounds.

S/N	Wound/ Lesion	Macrophage	Neutrophil x 10 ³ cells/mm ³
1	Normal wound, non-infected, non-treated.	8.40 ± 4.83	14.60 ± 2.79 a
2	Wound infected with <i>Staphylococcus aureus</i> and not treated.	3.00 ± 2.92	25.40 ± 6.31 b
3	Wound infected with <i>Staphylococcus aureus</i> and treated with normal saline.	6.00 ± 3.54	20.20 ± 7.60 c
4	Wound infected with <i>Staphylococcus aureus</i> and treated with <i>Euphorbia hirta</i> ethanolic extract.	7.00 ± 3.08	10.20 ± 3.96 d

Means with a different superscript are significantly different (P < 0.05).

Table 3. Histopathologic tissue inflammation response scores following irrigation with ethanolic extract of *Euphorbia hirta* on non-infected and infected wounds.

Non-infected wounds	<i>E. hirta</i> extract treated (L ₁)	Normal saline treated (L ₂)	No treatment (L ₃)
Dog 1	2	2	2
Dog 2	1	1	2
Dog 3	2	1	2
Dog 4	2	2	1
Mean Score	1.75 ^a	1.50 ^a	1.75 ^a
Infected wounds	<i>E. hirta</i> extract treated (R ₁)	Saline treated (R ₂)	No treatment (R ₃)
Dog 1	3	4	3
Dog 2	3	3	4
Dog 3	3	4	4
Dog 4	2	4	3
Mean Score	2.75 ^b	3.75 ^b	3.50 ^b

*Means with different superscripts are significantly different (P < 0.05). Ratings of inflammation are as follows: 0 - normal skin; 1 - minimal neutrophilic infiltration; 2 - mild neutrophilic infiltration; 3 - moderate neutrophilic infiltration; 4 - severe neutrophilic infiltration.

S. aureus is considered to be one that is the least susceptible to antiseptic agents. Having the ability to kill

S. aureus therefore gives such an agent a broader spectrum. This is the basis for the choice of the organism

in this study.

Our findings in the present study indicated that the ethanolic extract of *E. hirta* had a positive effect on *S. aureus* growth in canine wound. It has also shown that the extract did not provoke cutaneous tissue reaction when applied to incised wounds in dogs as no statistically significant difference ($P > 0.05$) in microscopic inflammation was seen in clean, non-infected *E. hirta* treated and non-infected controls. There was however a significant ($P < 0.05$) tissue reaction seen in infected and *E. hirta* treated wounds which may be due to bacterial activity. These results corroborates the findings of previous researchers to the effect that the extract contains substances that are capable of inhibiting the growth of micro-organisms (Akujobi et al., 2004; Parekh and Chanda, 2005; Ogbuliu et al., 2007). The observed antibacterial effect of the extract on cutaneous wound is believed to be due to the presence of phenols, alkaloids, tannis, flavonoids and saponins which have been shown to possess antibacterial and anti-septic properties (Yoshida et al., 1990; Cowan, 1999; Draughon, 2004; Parekh and Chanda, 2005; Soetan et al., 2006). Also, the report of Valsaraj et al. (1997) indicated that alkaloids and its derivatives have activities specifically against *S. aureus* and methicillin-resistant *S. aureus* and attributed the mechanism of action of these compounds to their ability to intercalate with DNA. The mode of action and efficacy of the routinely used cutaneous antimicrobials in surgery depend to a large extent on the physical and chemical properties of the compounds. While some act by mechanical means because of their excellent detergent and surfactant characteristics, others exert their effects by altering bacterial cell wall permeability and cell wall damage and also by forming highly reactive ions (Scherr and Dodd, 1976; Steward, 1980; Kaul and Jewette, 1981). In the present study, the mechanism by which *E. hirta* exerts its antibacterial properties on cutaneous wound is still unknown.

The results of this study indicated that infected wound benefited from irrigation with ethanolic extract of *E. hirta*. It also suggested that the extract could be used as an antiseptic in the preparation of surgical site. Further research is however necessary to determine the identity of the exact antibacterial compounds, the mode of action and their full spectrum of efficacy. Perhaps, other factors such as the concentration, volume and pH that could also influence the antibacterial efficacy of *E. hirta* in wound management should also be considered for further studies.

REFERENCES

- Amber EI, Henderson RA, Swain SF (1983). A comparison of antimicrobial efficacy and tissue reaction of four antiseptics on canine wounds. *Vet. Surgery* 18(2): 63-68.
- Akujobi C, Anyanwu BN, Onyze C, Ibekwe VI (2004). Antibacterial activities and preliminary phytochemical screening of four medicinal plants. *J. Appl. Sci.* 7(3): 4328-4338.
- Al-Mughrabi KI (2003). Antimicrobial activity of extracts from leaves, stems and flowers of *Euphorbia macroclada* against plant pathogenic fungi. *Phytopathologia mediterranea*, 42: 245-250.
- Athanasopoulos AN, Economopoulou M, Orlava VV, Sobke A, Schneider D et al., (2006): The extracellular adherence protein of *Staphylococcus aureus* inhibits wound healing by interfering with host defence and repair mechanism. *The Amer. Soc. for Haematology*, 101(7): 2720-2727.
- Bandow JE, Brotz H, Leichert LI (2005). Proteomic approach to understanding antibiotic action. *Antimicrob. Agents Chemother.* 47: 948-955.
- Bowler PG (1998). The anaerobic and aerobic microbiology of wounds. *A Review on wounds.* 10(6): 170-178.
- Bowler PG, Duerdon BI, Armstrong DG (2001). Wound microbiology and associated approaches to wound management. *Clin. Microbiol. Rev.* 14(2): 244-269.
- Cowan MM (1999). Plant products as Antimicrobial agents. *Clin. Microbiol Rev.* 12: 564-583.
- Draughon FA (2004). Use of Botanicals as Biopreservatives in Foods. *Food Technol.* 58(2): 20-28.
- Esimone CO, Adiukwu MU, Okonta JM (1998). Preliminary antimicrobial screening of the ethanolic extract from the Lichen *Usnea subfloridams* (L). *J. Pharmaceutic. Res. Dev.* 3(2): 99-102.
- Gruber RP, Vinstines L, Pardoe R (1975). The effects of commonly used antiseptics on wound healing. *Plast. Reconstr. Surg.* 55: 472.
- Hirsh CN, Spencer K (1995). *In: Small Animal Surgery.* Theresa Welsh Fossum 2nd Ed. Mosby Publication Inc. pp. 68-70.
- Igoli JO, Ogaji TA, Tor-Anyiin, Igoli NP (2005). Traditional medicine practice amongst the Igede people of Nigeria. Part II. *Afr. J. Traditional Compl. Alt. Med.* 2(2): 134-152.
- Kaul AF, Jewett JF (1981). Agents and Techniques for disinfection of skin. *Surg. Gynecol. Obstet.* 152: 667.
- Ogbulie JN, Ogueke CC, Okoli IC, Anyanwu BN (2007). Antibacterial activities and toxicological potentials of crude ethanolic extracts of *Euphorbia hirta*. *Afr. J. Biotechnol.* 6(13):1544-1548.
- Parekh J, Nair R, Chanda S (2005). Preliminary screening of some folklore medicinal plants from Western India for potential antimicrobial activity. *Indian J. Pharmacol.* 37: 408-409.
- Scherr DD, Dodd TA (1976). *In vitro* bacteriological evaluation of effectiveness of antimicrobial irrigating solutions. *J. Bone Joint Surg.* 58^A: 119.
- Soetan KO, Oyekunle MA, Aiyelaagbe OO, Fafunso MA (2006). Evaluation of the antimicrobial activity of Saponins extract of *Sorghum bicolor* L. Moench. *Afr. J. Biotechnol.* 5(23): 2405-2407.
- Steward CH (1980). Antiseptics and Disinfectants. In: Goodman LS, Gilman AG eds. *Pharmacological Basis of Therapeutics*, 6th Ed. New York: MacMillan Pub: p. 964.
- Valsaraj R, Pushpangadan P, Smith UW (1997). Antimicrobial screening of selected medicinal plants from India. *J. Ethnopharmacol.* 58: 75-83.
- Winstanley EW (1975). The microscopical appearance of the healing full thickness excised wound in the thoracic and metatarsal regions of the dog. *J. Small Anim. Pract.* 16: 143-154.
- Yoshida T, Namba O, Chen L, Okuda T (1990). Euphorbin E, a hydrolysable tannin dimmer of highly oxidized structure from *Euphorbia hirta*. *Chem. Phar. Bull.* 38(4): 1113-1115.