

## Full Length Research Paper

# Attenuation of cisplatin-induced nephrotoxicity in rats using zerumbone

Mohamed Yousif Ibrahim<sup>1</sup>, Ahmad Bustamam Hj Abdul<sup>1,2\*</sup>, Tengku Azmi Tengku Ibrahim<sup>3,4</sup>,  
Siddig Ibrahim AbdelWahab<sup>1</sup>, Manal Mohamed Elhassan<sup>1</sup> and Syam Mohan<sup>1</sup>

<sup>1</sup>UPM-MAKNA Cancer Research Laboratory, Institute of Bioscience (IBS), Universiti Putra Malaysia (UPM), Serdang, 43400, Selangor, Malaysia.

<sup>2</sup>Department of BioMedical Sciences, Faculty of Medicine and Health Sciences, Universiti Putra Malaysia (UPM), Serdang, 43400, Selangor, Malaysia.

<sup>3</sup>Microscopy Unit, Institute of Bioscience (IBS), Universiti Putra Malaysia (UPM), Serdang, 43400, Selangor, Malaysia.

<sup>4</sup>Department of Pathology, Faculty of Veterinary Medicine, Universiti Putra Malaysia (UPM), Serdang, 43400, Selangor, Malaysia.

Accepted 13 April, 2010

Zerumbone is a natural compound isolated from the fresh rhizomes of *Zingiber zerumbet*. This bioactive compound has shown a chemo-preventive, anti-inflammatory and free radical scavenging activities. This study examines the effect of zerumbone on the extent of tissue damage in cisplatin-induced nephrotoxicity in rats. The rats received a single dose injection of 10 mg/kg cisplatin. Other groups of rats received zerumbone (100 and 200 mg/kg), corn oil or the vehicle, dimethyl sulfoxide (DMSO) intraperitoneally for 4 days prior to cisplatin-injections. All animals were decapitated 16 h after cisplatin injection. Trunk blood was collected and analyzed for blood urea nitrogen (BUN) and serum creatinine. Kidney tissue was kept for the quantification of malondialdehyde and glutathione levels. Histopathological investigations were carried out and the severity of lesions was scored to obtain quantitative data. Our study revealed that zerumbone reduced kidney damage and preserved renal functions as proved by microscopic observations and lesion scoring. The increased in kidney malondialdehyde (MDA) levels with simultaneous glutathione (GSH) reduction in cisplatin treated group was attenuated by zerumbone ( $p < 0.05$ ). It was concluded that zerumbone is beneficial in cisplatin-induced renal dysfunction and organ damage in rats possibly via the prevention of lipid per oxidation and preservation of antioxidant glutathione.

**Key words:** Zerumbone, cisplatin, nephrotoxicity, oxidative stress, antioxidant glutathione.

## INTRODUCTION

Cisplatin (*cis*-diamine-dichloroplatinum) is a prominent member of the effective broad-spectrum antitumour drugs. However, its clinical usage is restricted due to some adverse side effects, such as nephrotoxicity and

ototoxicity (Ekborn et al., 2003; Iraz et al., 2005; Yao et al., 2007). Continued aggressive high-dose cisplatin chemotherapy necessitates investigating newer measures of preventing dose-limiting side effects that inhibit the administration of cisplatin at tumouricidal doses. Up till now, a large number of studies have been focused on measures of preventing cisplatin's side effects via the simultaneous supplementation of preventive agents (Ali et al., 2006). Findings of these studies suggested that the side effects of cisplatin could well be protected using drugs and micronutrients with different chemical entity (Blakley et al., 2001; Leitao and Blakley, 2003; Fetoni et al., 2004; Kalkanis et al., 2004; Weijl et al., 2004; Kim et al., 2005). Though the mechanism underlying cisplatin's

\*Corresponding author. E-mail: [ahmadbstmm@yahoo.com](mailto:ahmadbstmm@yahoo.com). Tel: 0060126894693-0060126143371 Fax: 0060389472101

**Abbreviations:** ROS, Reactive oxygen species; MDA, malondialdehyde; ZER, zerumbone; H and E, hematoxylin and eosin stain; HPLC, high performance liquid chromatography; DMSO, dimethyl sulfoxide; BUN, blood urea nitrogen; MDA, malondialdehyde; GSH, glutathione.

side effects are not clearly understood, it was considered to be attributed by various factors (Hong et al., 2005; Ramesh and Reeves, 2002; Nowak, 2002; Townsend and Hanigan, 2002; Xiao et al., 2003), amongst them included the generation of reactive oxygen species (ROS) that could interfere with the antioxidant defense system, resulting in oxidative damage at different tissues (Koc et al., 2005; Mansour et al., 2006; Iraz et al., 2006) and the reaction with thiols in protein and glutathione, which causes cell dysfunction. On the other hand, it has been proposed that the antitumour activity of cisplatin is due to its ability to form adducts with DNA, which could cause cross-linking of DNA strands (Kasparkova et al., 2004). As the anti-tumour activity and side effects in cisplatin-based chemo-therapy are mediated in part by different mechanisms, the actions on selective inhibition of certain side effects could be achieved whilst retaining the antitumor activity (Leonetti et al., 2003). Furthermore, since the side effects in cisplatin-based chemotherapy were considered to be induced through various factors, a possible potential protective action on these side effects could be achieved via the combined use of preventive agents with different chemical entity; however, until to this present day, very little is known regarding the combined use of cisplatin with these agents. In this present investigation, we attempted to explore the use of these agents in preventing cisplatin nephrotoxicity. In regard to this, a natural compound belonging to a ginger plant family, Zingiberaceae was used. Several dietary ingredients of this ginger family have been known and their biological activities elucidated (Aggarwal and Shishodia, 2006; Surh, 1999). The natural compound zerumbone (ZER) used in our study was isolated and purified from *Zingiber zerumbet* of the ginger family. This compound is used initially as an anti-inflammatory adjuvant for sprain and in treating human ailments such as stomach ache and fever. In addition, its rhizome has been used frequently as spice in traditional cooking (Chiu and Chang, 1986). Several reports on the bioactivities of ZER have been reported, which included anticarcinogenesis (Takada et al., 2005), anti-inflammation (Murakami et al., 2003) and most recently from our own laboratory, ZER's anticancer effect on cervical tissues (Abdul et al., 2008). Besides, ZER was also found to act synergistically as an anticancer agent during experimental cervical intraepithelial neoplasia in mice. In this present study, we investigated the preventive effect of zerumbone on cisplatin-induced nephrotoxicity using microscopy examination of rat kidney tissues after H and E (hematoxylin and eosin) staining and further evaluating blood kidney enzymes functions and levels of malondialdehyde (MDA), the end product of lipid peroxidation in kidney tissues, as biomarkers.

## MATERIALS AND METHODS

### Reagents and laboratory wares

All reagents used in this study are of analytical grade. All glasses

and plastic wares were washed with detergent and acid, and rinsed several times with distilled water. Cisplatin and the other chemicals were obtained from Sigma Chemical Co., St. Louis, MO, USA.

### Isolation and characterization of ZER

ZER was isolated using the hydrodistillation (steam distillation) method. Briefly, fresh rhizomes of *Z. zerumbet* were initially cleaned and sliced and later placed in a glass flask containing distilled water and heated immediately using the heating mantel. The flask was immediately connected to special glassware (Dienstag) in order to collect vaporized steam containing the volatile oil. Then volatile oil was crystallized using circulating cool water. The crystals were collected and used. To obtain highly pure ZER, recrystallization was performed using hexane and the solution was left standing to evaporate. Thin layer chromatography was used to examine purification of ZER at each step. The crystals of ZER were kept for further chemical and pharmacological analyses.

### ZER structure elucidation by nuclear magnetic resonance (NMR)

Five milligrams of ZER crystals were dissolved in high performance liquid chromatography (HPLC)-grade methanol and the sample was subsequently sent for NMR analysis at the laboratory of Natural Products, Institute of Bioscience, University Putra Malaysia (UPM). <sup>1</sup>Hydrogen and <sup>13</sup>Carbon NMR spectra were recorded in Varian Unity Inova spectrometer operated at 500 MHz and the chemical shifts of the respective compound were reported in ppm

### Animals

Thirty five (35) female rats (Sprague-Dawley) of 150 - 200 g weight, procured from the Animal House Unit, Faculty of Veterinary Medicine, UPM were used. The animal room at the Institute Bioscience, UPM was maintained at a temperature of 25 ± 2°C with a 12 h light/dark cycle and a relative humidity of 50 – 60%. Free access to food and water was allowed at all times. Rats were housed five per cage in sterilized plastic cages using homogenized wood shavings as bedding. All experimental protocols held on animals were done according to regulations set by the Institutional Animal Care and Use Committee, Faculty of Medicine and Allied Sciences, UPM.

### Experimental procedure

The rats were divided into groups (n = 5): Rats in Group 1 were intraperitoneally pretreated for 4 days with ZER (100 mg/kg per day, in corn oil). Rats in Group 2 were intraperitoneally pretreated for 4 days with ZER (200 mg/kg per day, in corn oil). Three hours after ZER pretreatment, a dose of 10 mg/kg of cisplatin was injected into rats in Groups 1 and 2. Rats in Group 3 were intraperitoneally treated by cisplatin as positive control. Group 4 were intraperitoneally treated with corn oil. Rats in Group 5 were intraperitoneally treated with ZER (100 mg /kg) as a control for Group 1. Rats in Group 6 were intraperitoneally treated with ZER (200 mg/kg) as a control for Group 2. Rats in Group 7 were intraperitoneally treated with dimethyl sulfoxide (DMSO) in distilled water, as a control for the cisplatin group. All animals were injected in similar volume injections. Since higher doses of cisplatin showed evidence of tissue damage between 8-15h after injection (Liu et al., 1998), the rats were killed under ether anesthesia; 16 h after injection and blood, kidney tissues were then collected. Trunk blood was collected and analyzed for serum creatinine and blood urea

**Table 1.** Kidney serum enzymes of control and cisplatin treated rats and the effect of zerumbone pre-treatment.

Groups	CREAT (mg/dl)		BUN (mg/dl)	
	Mean	SD	Mean	SD
100 ZER + CIS	91.25	16.42	7.53	2.29
200 ZER + CIS	73.00	12.17	7.95	3.51
Cisplatin	123.67*	16.77	17.30*	0.61
Corn Oil Negative Control	70.50	4.20	6.83	0.68
DMSO control	75.50	8.89	7.33	1.27
200 ZER	72.00	4.42	7.62	0.72
100 ZER	77.00	7.00	5.33	1.25

CREAT: Creatinine; BUN: blood urea nitrogen. Data are means  $\pm$  SD of five rats for each group. \*Denotes significant difference at 0.05.

nitrogen (BUN). After bleeding, kidney samples were removed and fixed in 10% formaldehyde for histopathological examinations or stored at  $-80^{\circ}\text{C}$  for subsequent measurement of malondialdehyde (MDA) and glutathione (GSH) levels.

#### Determination of kidney functions

As indicators of kidney function, serum creatinine and BUN levels were measured. All biochemical assays were performed spectrophotometrically using Hitachi-912 Autoanalyser (Mannheim, Germany) with kits supplied by Roche Diagnostics (Mannheim, Germany). To obtain data with good sensitivity and validity, serum samples were analyzed in triplicates and blindly analyzed.

#### Histopathological examinations

Animal tissue was fixed in 10% formalin. Kidney samples embedded in paraffin and sectioned at  $5\ \mu\text{m}$  were stained with hematoxylin-eosin. All sections were examined using a photomicroscope (Olympus BH-2, Japan). At least five microscopic areas were examined to score a specimen. The renal injury was based on degeneration of Bowman space and glomeruli, degeneration of proximal and distal tubuli, vascular congestion and interstitial edema. Each specimen was score using a scale ranging from 0 to 3 (0: none, 1: mild, 2: moderate and 3: severe) for each criterion. The total score was 9 for kidney. Histological examination and scoring were performed by an observer (F.E.) unaware of the treatment groups.

#### Measurement of tissue MDA

Levels of MDA were assayed by the method of Satoh. Briefly, 10% (weight/volume) homogenate of kidney made by 0.1 mol/L phosphate buffer was centrifuged at  $4^{\circ}\text{C}$ ; 3500 rpm for 10 min. 0.2 mL supernatant was mixed with 0.67% 2-thiobarbituric acid (TBA) and 20% trichloroacetic acid solution and heated in a boiling water bath for 30 min. The pink-colored chromogen formed by the reaction of TBA with MDA was measured at 532 nm. The results were expressed as MDA nmol/mg protein. Contents of protein in the supernatant were measured by Lowry's method (Yingjun et al., 2008).

#### Measurement of tissue GSH levels

The tissue samples were homogenized in 10 volumes of ice-cold 10% trichloroacetic acid and centrifuged at 1000 g for 15 min at

$4^{\circ}\text{C}$ . Supernatant was removed and recentrifuged at 35,000 g at  $4^{\circ}\text{C}$  for 8 min. GSH was determined using a spectrophotometric method which is a modification of Ellman procedure (Aykan et al., 1985).

#### Statistical analysis

All data are expressed as mean  $\pm$  SD. Histological data (Lesion Scoring) were compared using Kruskal-Wallis non-parametric test whilst other parameters were compared by one-way ANOVA followed by *post hoc* Tukey's honestly significant difference (HSD) multiple comparison tests. The type 1 error level was set at  $p < 0.05$  for all tests. All statistical analyses were performed using statistical package for the social sciences (SPSS) software (Chicago, IL, USA) version 16.0 for Microsoft Windows®.

## RESULTS

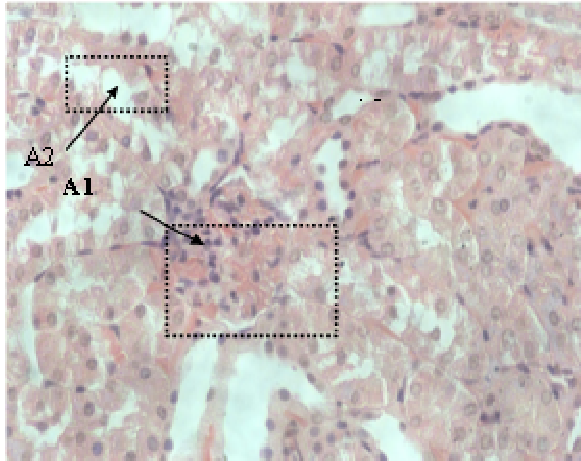
### The effect of zerumbone on cisplatin-induced kidney dysfunction

The results of this study showed that cisplatin caused a significant reduction in renal function, as characterized by remarkable increased in serum creatinine and BUN levels (Table 1). These findings indicate strongly that the single intra-peritoneal injection of 10 mg/kg cisplatin harms renal function.

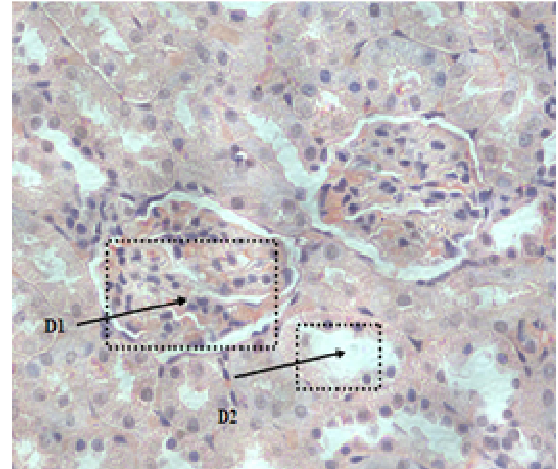
Pretreatment with zerumbone for 4 days significantly overturned cisplatin-induced elevation in serum creatinine and BUN levels. Treatment with DMSO and corn oil however did not induce any abnormal changes in the serum level of kidney enzymes. In addition, serum levels of these enzymes are not affected by the treatment with zerumbone (Table 1).

### The effect of zerumbone on qualitative and quantitative histopathology and clinical observation

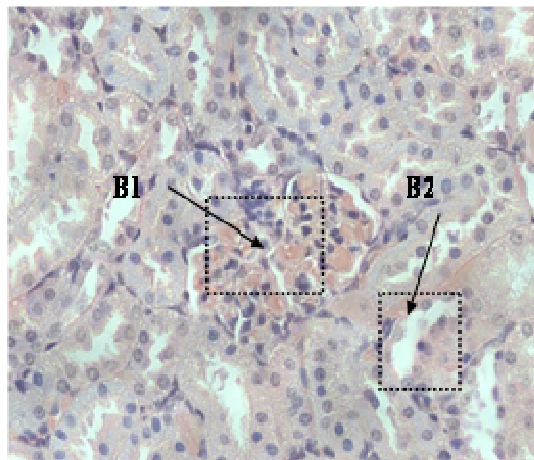
No death was observed among all groups during the period of this study. Kidney samples were obtained and



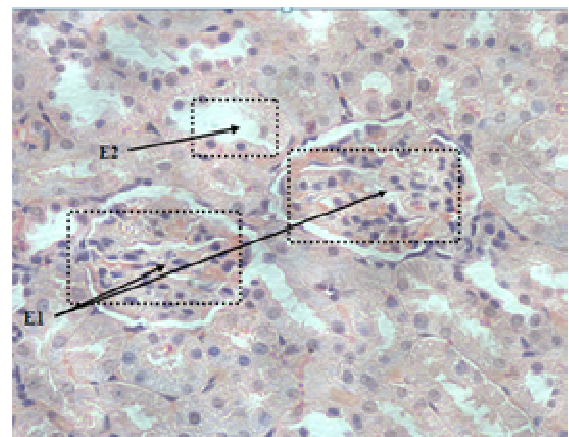
A-cisplatin 10 mg/kg  
**A1** Severe glomerular congestion.  
**A2** Severe degeneration in tubular cells



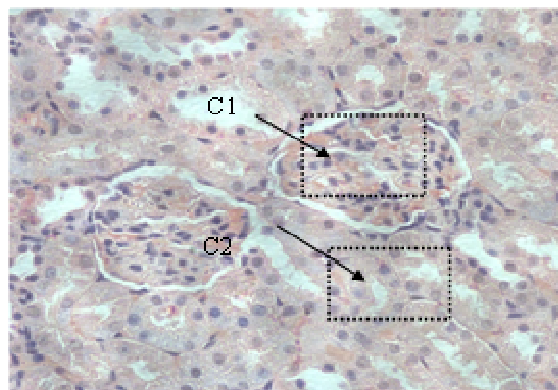
D-ZER 200 mg/kg control  
**D1** Normal Histological Appearance of Glomeruli,  
**D2** Normal Histological Appearance of Tubular Cells.



B-ZER 100 mg/kg+ cisplatin 10m g/kg  
**B1** Moderate glomerular congestion.  
**B2** Moderate tubular degeneration in tubular cells.



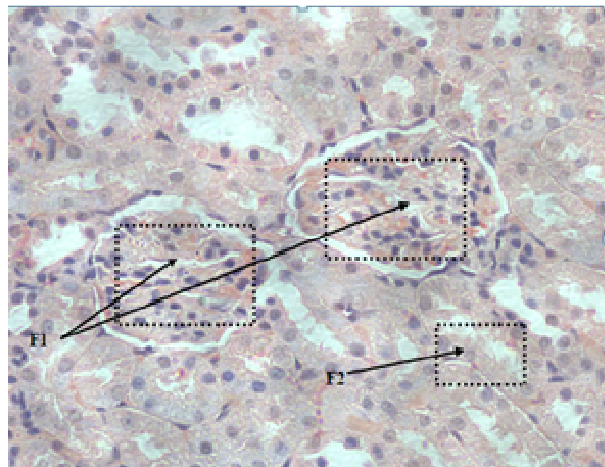
E-ZER 100 mg/kg control  
**E1** Normal Histological Appearance of Glomeruli,  
**E2** Normal Histological Appearance of Tubular Cells.



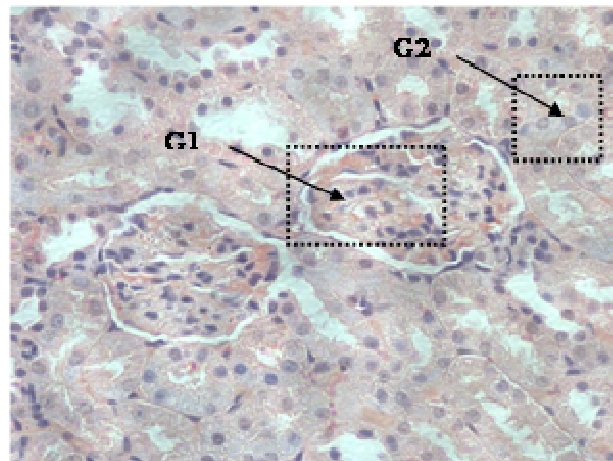
C-ZER 200 mg/kg + cisplatin 10 mg/kg  
**C1** Mild Glomerular Congestion.  
**C2** Mild Tubular Degeneration in Tubular Cells.

observed under microscopy. Kidney tissues in cisplatin-administered animals showed cellular damage. Renal damage was recognized by severe degeneration in glomeruli and tubuli (both proximal and distal tubuli). In zerumbone pre-treated animals, the morphology of renal tissue is near normal. The morphological feature of kidney tissues from zerumbone injected animals is similar to the control morphology, which revealed normal and regular appearance of both glomeruli and tubuli (Figure 1: A - G). With reference to the morphological appearance of kidney tissues from cisplatin injected animals, their quantitative lesions scoring mean is statistically higher than that of normal control group ( $p < 0.05$ ). Zerumbone administration reduced the microscopic lesion scoring effectively ( $p < 0.05$ ) (Table 1).

Total mean scoring, degeneration of Bowman space and glomeruli, degeneration of proximal and distal tubuli,



F-Negative control CORN OIL  
**F1** Normal Histological Appearance of Glomeruli,  
**F2** Normal Histological Appearance of Tubular Cells.



G-Negative control DMSO  
**G1** Normal Histological Appearance of Glomeruli,  
**G2** Semi Normal Histological Appearance of Tubular Cells.

vascular congestion and interstitial edema was used as indices to evaluate the lesions quantitatively as earlier mentioned. In respect to these indices, the highest mean was observed in the cisplatin treated group animals (Table 2).

### The effect of zerumbone on MDA and GSH levels

Lipid peroxidation in kidney tissues was evaluated using measurements of MDA levels quantitatively. In cisplatin injected animals, MDA level was markedly higher compared to normal control. Pretreatment with zerumbone decreases the levels of MDA which are significantly different from the mean of MDA in cisplatin treated animals (Table 3). Meanwhile, the indigenous level of GSH was strongly depleted by a single intraperitoneal injection of 10 mg/kg cisplatin. However, this depletion has been reversed by prior treatment of zerumbone at 100 and 200 mg/kg injections (Table 3).

### DISCUSSION

Platinating agents are an important class of chemotherapeutic agents, with cisplatin and carboplatin used in treating testicular, gynecologic, head and neck and lung carcinomas (Rabik and Dolan, 2007). Contraindications of cisplatin are documented as the important dose-limiting factor in cancer chemotherapy, but at high doses of cisplatin, hepatotoxicity as well as nephrotoxicity does transpire (Weijl et al., 2004). Hence, to overcome such contraindications, the potential use of natural products of plant origin has been examined (Hong et al., 2005).

Zingiberaceae is a botanical family that possesses

**Figure 1.** Photomicrographs of kidney samples of the control, cisplatin, or 100 and 200 mg kg<sup>-1</sup> ZER-treated cisplatin groups. **Control group (G), (F):** normal histological appearance of kidney. **Cisplatin group (A):** severe glomerular congestion and degeneration, dilatation in Bowman's space, and degeneration in tubular cells in kidney. **Cisplatin + 200 mg ZER group (C):** Mild glomerular and tubular degeneration in kidney. **Cisplatin + 100 mg ZER group (C)** Normal Histological appearance of Glomeruli and Normal Histological appearance of Tubular Cells. Hematoxylin–eosin staining, original magnifications: ×400. A: 10 mg/kg cisplatin; B: 100 mg/kg ZER + 10 mg/kg cisplatin; C: 200 mg/kg ZER + 10 mg/kg cisplatin; D: 200 mg/kg ZER + 10 mg/kg cisplatin; E: 100 mg/kg ZER + 10 mg/kg cisplatin; F: Negative Control (Corn oil); and G: Negative Control (DMSO).

potential nephro-protective compounds such as curcumin and xanthorrhizol (Kim et al., 2005). Zerumbone, a phytochemical isolated from *Z. zerumbet* of the Zingiberaceae family, has shown to possess chemopreventive, free radical scavenging activities and activating properties towards phase II drug metabolizing enzymes (Murakami et al., 2003; Abdul et al., 2009). In addition, the cytotoxic property of zerumbone was known to be cytoselective towards cancer cells compared to normal cells (Sakinah et al., 2007).

Our previous study demonstrated that zerumbone acts synergistically with cisplatin to inhibit cervical intra-epithelial neoplasia induced in female Balb/c mice. This synergism led to the lowering of the curative dose of cisplatin and subsequently to its clinical complications (Abdul et al., 2008).

Experiments in animals have shown that a minimum dose of cisplatin (5 mg/kg body weight) was adequate to persuade toxicity in rats (Ravi et al., 1995). A higher dose of cisplatin (12 mg/kg weight) corresponds to the equivalent human dose presently being used. In this study, a dose of cisplatin (10 mg/kg body weight, i.p.) was used that demonstrated significant increase in kidney

**Table 2.** Lesions scoring of the control, cisplatin or cisplatin + ZER.

Treatment	Degeneration of Bowman space and glomeruli		Degeneration of proximal and distal tubuli		Vascular congestion and interstitial edema	
	Mean	SD	Mean	SD	Mean	SD
100ZER+Cisplatin	1.33	0.44	1.00	0.28	0.33	0.00
200ZER+Cisplatin	0.80	0.25	1.60	0.51	0.24	0.21
CISPLATINPLATIN	3.00*	0.00	3.00*	0.00	3.50*	1.50
Corn Oil Negative control	0.00	0.00	0.00	0.00	0.00	0.00
DMSO Control	0.00	0.00	0.00	0.00	0.00	0.0
200ZER	1.25	0.40	1.75	0.50	0.50	0.12
100ZER	1.50	0.48	0.90	0.20	0.75	0.16

**Table 3.** The tissue malondialdehyde (MDA) level, glutathione (GSH) content of the control, cisplatin-injected and zerumbone pretreated groups.

Treatments	MDA (nmol/g)		GSH ( $\mu$ mol/g)	
	Mean	SD	Mean	SD
ZER100+Cisplatin	0.38	0.05	1.66	0.15
ZER200+Cisplatin	0.33	0.10	1.90	0.16
Cisplatin	1.10*	0.17	4.87*	0.36
Corn Oil Negative Control	0.41	0.09	1.91	0.14
DMSO	0.43	0.07	1.89	0.12
200ZER	0.40	0.12	1.73	0.11
100ZER	0.42	0.11	1.70	0.11

Data are means  $\pm$  SD of five rats for each group.

\*Significant difference at 0.05.

serum enzymes, MDA and GSH as well as in causing histopathological lesions in kidney compared to normal control groups.

Biochemical evidence of renal injury has been demonstrated by elevated levels of BUN and serum creatinine. In our present study, intraperitoneally administered cisplatin (10 mg/kg) led to elevated levels of these biochemical markers. In contrast, intraperitoneal pretreatment with zerumbone (100 and 200 mg/kg) significantly abrogated these elevations. These biochemical findings were confirmed by evidences of microscopic examinations.

Platinating agents become aquated in cellular cytoplasm, which enables them to react with thiol containing molecules, including GSH. Increased concentrations of these compounds are known to induce resistance against cisplatin (Ali et al., 2006). Glutathione acts as an antioxidant to the cell; it helps to maintain the redox environment while maintaining the reduced sulfhydryl groups. Cisplatin is thought to be detoxified by glutathione through an adduct formation (Ali et al., 2006; Hoffman et al., 2002).

In agreement to the above, this study revealed elevations in renal glutathione levels in rats treated with zerumbone as compared to the control, DMSO and corn oil groups. Glutathione uptake is one of the mechanisms of cells to

sustain intracellular thiol redox status (Visarus et al., 1996). Thus, it is possible to speculate that a positive regulation in the biosynthesis of glutathione may contribute to an increase in its intracellular contents. In this context, we postulated that zerumbone indirectly induces the biosynthesis of glutathione and provided a protective intracellular mechanism, presumably as free radical scavenger for toxic agents. Hoffman et al. (2000) had proposed a redox model of cell proliferation and suggested an appropriate dose of zerumbone that will enhance intracellular redox potential ( $E$ ) in cancer cells. In this aspect, zerumbone is thought to deplete intracellular reduced glutathione, thereby raising  $E$ , which in turn stops the proliferation of the cancer cells. On the other hand, normal cells partially increased the redox potential  $E$ . In relation to this, our study indicates enhanced levels of antioxidant glutathione (reduced form) in non-cancerous rat kidney tissues after pretreatment with zerumbone. We find these results interesting since pretreatment using appropriate dose of zerumbone is able to reduce cisplatin nephrotoxicity in noncancerous rats; in tandem with zerumbone is reported to be a potential anti-cancer agent (Abdul et al., 2008; Sakinah et al., 2007). This could mean that zerumbone is specific towards cancer cells but causing less adversity towards normal surrounding tissues,

concurrently to previous findings from our laboratory (Abdul et al., 2008).

Previous data have mentioned that cisplatin induces oxidative stress and lipid peroxidation, whereby cisplatin induced nephrotoxicity is narrowly related to an increase in lipid peroxidation in kidney tissues (Yüce et al., 2007). In our present study using laboratory rats, renal injury develops after intraperitoneally injecting high dose of cisplatin (10 mg/kg), whilst renal toxicity became obvious as early as 8 h after injection, as indicated by marked elevations in the kidney biomarker enzymes and MDA levels in rats' kidney tissues.

Many natural products have been evaluated as potential chemopreventive agents (Hong et al., 2005). The effects of pretreatment of a natural antioxidant on cisplatin-induced renal damages have been previously investigated and reported elsewhere (Hong et al., 2005; Ali et al., 2006). The findings of this study however have demonstrated *in vivo* that pretreatment with a natural compound such as zerumbone prevented kidney cells from further tissue damages as evidenced by the significant difference between cisplatin alone and zerumbone pretreatment groups.

## Conclusion

It can be concluded that cisplatin, when administrated at a dose of 10 mg/kg, induced renal damages as evidenced by the qualitative and quantitative histopathology and biochemical analysis. DMSO and corn oil did not induce any crossing effect, which clearly shows the validity of the experimental design of this study. On the other hand, zerumbone pretreatment was beneficial in cisplatin-induced renal dysfunction and organ damage in rats, presumably via the prevention of lipid peroxidation and preservation of antioxidant glutathione. Therefore, these beneficial effects could be responsible for providing nephro-protective properties and hence, anti-cancer chemopreventive potential. It is therefore, strongly recommended to consider this natural compound to be a useful co-treatment for cisplatin, particularly during treatment of cancers.

## ACKNOWLEDGEMENTS

The authors are grateful and would like to express their deepest appreciations to Dr. Huda Yahia Hamid, a Clinical Veterinarian and Histopathologist, in evaluating the histopathology slides. The authors would also like to express their appreciation to The National Cancer Counsel of Malaysia (MAKNA) and Research University Grant Scheme (RUGS) for providing financial supports in this study.

## REFERENCES

Abdul AB, Adel SA, Nirmala DT, Siddig IA, Zetty NZ, Sharin R (2008). Anticancer Activity of Natural Compound (Zerumbone) Extracted from

- Zingiber Zerumbet in Human HeLa Cervical Cancer Cells. *Int. J. Pharmacol.* 4(3): 160-168.
- Abdul AB, Siddig IW, Johari J, Adel SA, Manal MT (2009). Combination of zerumbone and cisplatin to treat cervical intraepithelial neoplasia in female Balb/c mice. *Int. J. Gynecol. Cancer.* 19(6):1004-1010.
- Yüce A, Ateşşahin A, Çeribaşı AO, Aksakal M (2007). Ellagic Acid Prevents Cisplatin-Induced Oxidative Stress in Liver and Heart Tissue of Rats. *Basic Clin. Pharmacol. Toxicol.* Issue101(5): 345-349.
- Aggarwal BB, Shishodia S (2006). Molecular targets of dietary agents for prevention and therapy of cancer, *Biochem. Pharmacol.* 71: 1397-1421.
- Ali BH, Al-Moundhri M, Tageldin M, Al-Husseini IS, Mansour MA, Nemmar A (2006). Ontogenic aspects of cisplatin-induced nephrotoxicity in rats, *Food Chem. Toxicol.* 46: 3355-3359.
- Ali BH, Al-Moundhri MS (2006). Agents ameliorating or augmenting the nephrotoxicity of cisplatin and other platinum compounds: a review of some recent research. *Food Chem. Toxicol.* 44: 1173-1183.
- Aykac G, Uysal M, Yalcın AS, Koc,ak-Toker N, Sivas AO zH (1985). The effect of chronic ethanol ingestion on hepatic lipid peroxide, glutathione peroxidase and glutathione transferase in rats, *Toxicology*, 36: 71-76.
- Blakley BW, Cohen JI, Doolittle ND, Muldoon LL, Campbell KC, Dickey DT (2001). Strategies for prevention of toxicity caused by platinum-based chemotherapy. *Laryngoscope* 112: 1997-2001.
- Chiu NY, Chang KH (1986). Zingiberaceae. Taipei: SMC Publishing Inc.
- Ekborn A, Lindberg A, Laurell G, Wallin I, Eksborg S, Ehrsson H (2003). Ototoxicity, nephrotoxicity and pharmacokinetics of cisplatin and its monohydrated complex in the guinea pig. *Cancer, Chemother. Pharmacol.* 51: 36-42.
- Fetoni AR, Sergi B, Ferraresi A, Paludetti G, Troiani D (2004). Protective effects of alphatocopherol and tiopronin against cisplatin-induced ototoxicity, *Acta. Otolaryngol.* 124: 421-426.
- Hoffman A, Spetner LM, Burke M (2002). Redox-regulated mechanism may account for zerumbone's ability to suppress cancer-cell proliferation. *Carcinogenesis* 23: 1961-1966.
- Hong KO, Hwang JK, Park KK, Kim SH (2005). Phosphorylation of c-Jun N-terminal Kinases (JNKs) is involved in the preventive effect of xanthorrhizol on cisplatin-induced hepatotoxicity, *Arch. Toxicol.* 79: 231-236.
- Iraz M, Kalcioğlu MT, Kizilay A, Karatas E (2005). Aminoguanidine prevents ototoxicity induced by cisplatin in rats, *Ann. Clin. Lab. Sci.* 35: 329-335.
- Iraz M, Ozerol E, Gulec M, Tasdemir S, Idiz N, Fadillioglu E (2006). Protective effect of caffeic acid phenethyl ester (CAPE) administration on cisplatin-induced oxidative damage to kidney in rat. *Cell Biochem. Funct.* 24: 357-361.
- Kalkanis JG, Whitworth C, Rybak LP (2004). Vitamin E reduces cisplatin ototoxicity. *Laryngoscope*, 114: 538-542.
- Kasparkova J, Delalande O, Stros M, Elizondo-Riojas MA, Vojtiskova M, Kozelka J, Brabec V (2004). Recognition of DNA interstrand cross-link of antitumor cisplatin by HMGB1 protein. *Biochemistry*, 42: 1234-1244.
- Kim SH, Hong KO, Hwang JK, Park KK (2005). Xanthorrhizol has a potential to attenuate the high dose cisplatin-induced nephrotoxicity in mice, *Food. Chem. Toxicol.* 43: 117-122.
- Koc A, Duru M, Ciralik H, Akcan R, Sogut S (2005). Protective agent, erdosteine, against cisplatin-induced hepatic oxidant injury in rats. *Mol. Cell Biochem.* 278: 79-84.
- Leitao DJ, Blakley BW (2003). Quantification of sodium thiosulphate protection on cisplatin-induced toxicities. *J. Otolaryngol.* 32: 146-50.
- Leonetti C, Biroccio A, Gabellini C, Scarsella M, Maresca V, Flori E (2003). Alpha-tocopherol protects against cisplatin-induced toxicity without interfering with antitumor efficacy, *Int. J. Cancer*, 104: 243-250.
- Liu J, Liu Y, Habeebu SS, Klaassen CD (1998). Metallothionein (MT)-null mice are sensitive to cisplatin-induced hepatotoxicity, *Toxicol. Appl. Pharmacol.* 149: 24-31.
- Mansour HH, Hafez HF, Fahmy NM (2006). Silymarin modulates cisplatin induced oxidative stress and hepatotoxicity in rats, *J. Biochem. Mol. Biol.* 39: 656-661.
- Murakami A, Hayashi R, Takana T, Kwon KH, Ohigashi H, Safitri R

- (2003). Suppression of dextran sodium sulfate-induced colitis in mice by zerumbone, a subtropical ginger sesquiterpene, and nimesulide: separately and in combination, *Biochem. Pharmacol.* 66: 1253-1261.
- Nowak G (2002). Protein kinase C-alpha and ERK1/2 mediate mitochondrial dysfunction, decreases in active Na<sup>+</sup> transport, and cisplatin-induced apoptosis in renal cells, *J. Biol. Chem.* 277: 43377-43388.
- Rabik CA, Dolan ME (2007). Molecular Mechanisms of Resistance and Toxicity Associated. *Cancer Treat. Rev.* 33(1): 9-23.
- Ramesh G, Reeves WB (2002). TNF-alpha mediates chemokine and cytokine expression and renal injury in cisplatin nephrotoxicity, *J. Clin. Invest.* 110: 835-842.
- Ravi RS, Somini SM, Rybak LP (1995). Mechanism of cisplatin ototoxicity. Antioxidant system, *Pharmacol. Toxicol.* 76: 386-394.
- Sakinah SA, Handayani ST, Hawariah LP (2007). Zerumbone induced apoptosis in kidney cancer cells via modulation of Bax/Bcl-2 ratio. *Cancer Cell Int.* 7: p. 4.
- Surh YJ (1999). Molecular mechanisms of chemopreventive effects of selected dietary and medicinal phenolic substances. *Mutation Research- Fund. Mol. Mechan. Mutat.* 428: 305-327.
- Takada Y, Murakami A, Aggarwal BB (2005). Zerumbone abolishes NF-jB and IjBa kinase activation leading to suppression of antiapoptotic and metastatic gene expression, upregulation of apoptosis, and down regulation of invasion. *Oncogene*, 24: 6957-6969.
- Townsend DM, Hanigan MH (2002). Inhibition of gamma-glutamyl transpeptidase or cysteine S-conjugate beta-lyase activity blocks the nephrotoxicity of cisplatin in mice, *J. Pharmacol. Exp. Ther.* 300: 142-148.
- Visarus TM, Putt DA, Schare JM, Pegouske DM, Lash LH (1996). Pathways of glutathione metabolism and transport in isolated proximal tubular cells from rat kidney. *Biochem. Pharmacol.* 52: 259-272.
- Weijl NI, Elsendoorn TJ, Lentjes EG, Hopman GD, Wipkink-Bakker A, Zwiderman AH (2004). Supplementation with antioxidant micronutrients and chemotherapy-induced toxicity in cancer patients treated with cisplatin-based chemotherapy: a randomised, double-blind, placebocontrolled study, *Eur. J. Cancer.* 40: 1713-1723. with Platinating Agents, *Cancer Treat. Rev.* 33: 9-23.
- Xiao T, Choudhary S, Zhang W, Ansari NH, Salahudeen A (2003). Possible involvement of oxidative stress in cisplatin-induced apoptosis in LLC-PK1 cells, *J. Toxicol. Environ. Health A.* 66: 469-479.
- Yao X, Panichpisal K, Kurtzman N, Nugent K (2007). Cisplatin nephrotoxicity: a review. *Am. J. Med. Sci.* 334: 115-124.
- Yingjun L, Xiuqiang L, Chunwei L, Gexin L, Yaping J, Hao T (2008). Selection of agents for prevention of cisplatin-induced hepatotoxicity, *Pharmacol. Res.* 57: 125-131.