

Original Research Article

Usnic acid ameliorates bleomycin-induced pulmonary fibrosis in mice via inhibition of inflammatory responses and oxidative stress

Xiao-Qi Huang^{1,2}, Gao-Xiang Ai¹, Xing-Han Zheng¹, Hui-Jun Liao^{3*}

¹Guangdong Provincial Key Laboratory of New Drug Development and Research of Chinese Medicine, Mathematical Engineering Academy of Chinese Medicine, Guangzhou University of Chinese Medicine, Guangzhou 510006, ²Guangzhou University Chinese Medicine, Dongguan Mathematical Engineering Academy of Chinese Medicine, Dongguan 523808, ³Department of Clinical Pharmacy and Pharmaceutical Services, Shenzhen Sixth People's Hospital (Nanshan Hospital), Shenzhen, PR China

*For correspondence: **Email:** lhj2019000@163.com

Sent for review: 15 June 2019

Revised accepted: 20 November 2019

Abstract

Purpose: To Investigate the effect of usnic acid (UA) on bleomycin (BLM)-induced pulmonary fibrosis in mice, and the underlying mechanism.

Methods: Male Kunming mice with bleomycin-induced pulmonary fibrosis (PF) were exposed to different concentrations of usnic acid. Lung coefficient and histopathological changes were determined, while MDA, superoxide dismutase (SOD) activity, and expression levels of hydroxyproline, tumor necrosis factor- α , interleukins-1 β & 6, and transforming growth factor- β 1 were assayed in lung homogenates.

Results: UA significantly mitigated lung coefficient and histopathological changes in mice. Compared to the bleomycin group, MDA level was significantly reduced while the content of SOD markedly increased after UA pretreatment ($p < 0.05$). Moreover, UA significantly reduced the expression levels of all the parameters, relative to bleomycin group ($p < 0.05$).

Conclusion: These results indicate that UA protects mice against bleomycin-induced PF via a mechanism associated with attenuation of pro-oxidant stress and inflammation. Therefore, UA has therapeutic potential for the management of pulmonary fibrosis.

Keywords: Usnic acid, Bleomycin, Pulmonary fibrosis, Inflammation, Oxidative stress

This is an Open Access article that uses a fund-ing model which does not charge readers or their institutions for access and distributed under the terms of the Creative Commons Attribution License (<http://creativecommons.org/licenses/by/4.0>) and the Budapest Open Access Initiative (<http://www.budapestopenaccessinitiative.org/read>), which permit unrestricted use, distribution, and reproduction in any medium, provided the original work is properly credited.

Tropical Journal of Pharmaceutical Research is indexed by Science Citation Index (SciSearch), Scopus, International Pharmaceutical Abstract, Chemical Abstracts, Embase, Index Copernicus, EBSCO, African Index Medicus, JournalSeek, Journal Citation Reports/Science Edition, Directory of Open Access Journals (DOAJ), African Journal Online, Bioline International, Open-J-Gate and Pharmacy Abstracts

INTRODUCTION

Pulmonary fibrosis (PF) is a respiratory disease associated with gradual replacement of normal lung parenchyma with fibrous tissue, and it results in chronic inflammatory response and deposits of excess collagen [1]. The incidence of

PF has been on the increase in recent years. It has been estimated that the median survival of patients with PF is 2.8 to 4.2 years [2].

Transforming growth factor (TGF- β) regulates the differentiation, proliferation and apoptosis of cells and the secretion of extracellular matrix.

Increasing evidence suggest that the pathological accumulation of extracellular matrix in the interstitial lung is implicated in the pathogenesis of PF [3]. Moreover, TGF- β 1 is a strong actuation factor that promotes the secretion and pathological accumulation of extracellular matrix in the lungs, leading to PF.

Excessive oxidative stress in lung tissue is an important pathological feature of PF. Reactive oxygen species (ROS) induce apoptosis and damage of alveolar epithelial cells through cell membrane lipid peroxidation. Studies have shown that ROS activate the protein tyrosine kinase and protein phosphatase pathway, resulting in enhancement of the secretion of inflammatory cytokines. In addition, ROS affect the degradation of extracellular matrix [4].

There is need for newer therapeutic agents for pulmonary fibrosis because the currently used agents such as immunosuppressants and anti-fibrotic drugs are limited by low efficacy and severe side effects. Usnic acid (UA), a compound present in lichens, is especially abundant in *Lecanora*, *Ramalina*, *Alectoria*, *Cladonia*, *Usnea* and *Evernia* [5]. It possesses numerous pharmacological properties, including anti-oxidant, anti-inflammatory, antitumor, antiviral, antibiotic, antipyretic and analgesic effects [6]. The mechanism involved in the effect of UA against lipopolysaccharide-induced acute lung injury might be associated with the inhibition of excessive inflammatory responses and oxidative stress [7]. Hence, this study was carried out to investigate the protective effect of UA on BLM-induced PF in mice, and the underlying mechanism.

EXPERIMENTAL

Materials

Usnic acid (UA, Figure 1) was product of Sigma-Aldrich, Shanghai, China, while BLM (purity > 99 %) was obtained from Nippon Kayaku, Japan. Prednisone acetate (PA; purity: > 99 %) was purchased from the Guangdong Huanan Pharmaceutical Group Co. Ltd, Dongguan, Guangdong, China. Hydroxyproline (HYP), TNF- α , IL-1 β , IL-6, TGF- β 1, ELISA and protein assay kits, and assay kits for MDA and SOD were obtained from Jiancheng Bioengineering Institute, Nanjing, China. The other reagents were of analytical quality.

Experimental mice

Mice (male Kunming) were supplied by the Center for Laboratory Animal Services of our

institution (certificate no. SCXK2013-0020). The mice were housed in a 12 h light/ 12 h dark cycle at temperature of 25 – 27 °C and relative humidity 50 - 60 %. The mice received standard forage and clean water *ad libitum*. The study was carried out strictly in compliance with National Institutes of Health (NIH) Guide for the Care and Use for Laboratory Animals [8], and approved by the Institutional Animal Care and Use Committee of Guangzhou University of Chinese Medicine (approval no. 2016047).

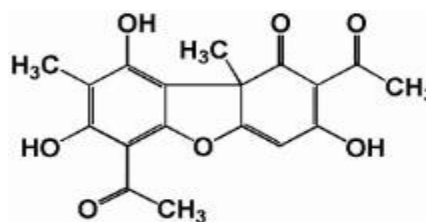


Figure 1: Structure of usnic acid

Experimental design

Six groups of mice were used: control, BLM, BLM + UA (3) and BLM + prednisone acetate (PA) groups. Mice in all groups except control were administered bleomycin at a dose of 15 mg/kg, i.p., once a day for 10 consecutive days. Mice in the control group received normal saline injection in place of bleomycin. On the 2nd day after BLM injection, the BLM + UA and BLM + PA mice were given UA at doses of 25, 50 and 100 mg/kg, i.g., or 5 mg PA/kg, i.g. daily for 21 days. At the same time, the control and BLM group mice were given equivalent amounts of Tween-80 in place of UA and PA. One hour after the last administration, the mice were humanely sacrificed. The mice were weighed, and pulmonary tissues were taken for determination of lung coefficient and histological studies. Moreover, the pulmonary levels of SOD, MDA, HYP, TGF- β 1, TNF- α , IL-1 β and IL-6 were determined. The doses of UA used were selected based on a pilot trial on bleomycin-induced pulmonary fibrosis.

Determination of lung coefficient

One hour after the last treatments, the mice were weighed, and sacrificed humanely, and the lung tissues were excised and weighed immediately. Lung coefficient [ratio of lung weight (mg) to weight (g)] is closely associated with the severity of pulmonary fibrosis[9].

Histological assessments

Following mice sacrifice, the lung tissues were excised, fixed in 10 % paraformaldehyde and

paraffinized. After deparaffinizing and dehydrating, the lung tissues were cut into 3- μ m sections for hematoxylin & eosin (H & E) and Masson staining. After H & E staining, histological scoring for lung fibrosis was performed by a lung pathologist in a blinded way using a standard and validated score system based on pathological changes in lungs [10]. Histological scoring for lung fibrosis in the Masson staining was performed by lung pathologists who were naïve to this study protocol. The lung fibrosis scoring was done using a validated score system based on the pathological changes in the lungs.

Preparation of lung homogenate

Mice lung tissue (100 mg) was homogenized in a microtube (T18 basic, IKA, Germany) with 0.9 mL of PBS. The homogenate and centrifuged at 15000 rpm for 10 min at 4 °C and supernatant was kept at -80 °C prior to use in subsequent assays.

Assay of MDA level and SOD activity

Excessive oxidative stress is implicated in the etiology pulmonary fibrosis. The pulmonary MDA content and SOD activity were assayed using their respective assay kits.

HYP content and levels of inflammatory cytokines

The content of HYP is significantly increased in the lung tissue of mice with PF. Thus, HYP is an indicator of the severity of PF. Excessive inflammatory response is also a critical factor in the pathogenesis of pulmonary fibrosis. Therefore, in this study, tumor necrosis factor- α , interleukins-1 β & 6, and transforming growth factor- β 1 were assayed using their respective ELISA assay kits (Jiancheng Company, Nanjing, China).

Statistical analysis

Data are presented as mean \pm SEM. One-way ANOVA was used for comparisons among groups. Statistical significance was set at $p < 0.05$. All analyses were done with SPSS 20.0.

RESULTS

Effect of UA on lung coefficient of mice with pulmonary fibrosis

As shown in Table 1, the lung coefficient of mice in BLM group significantly increased ($p < 0.01$), when compared to the control group, indicating

that the pulmonary fibrosis model of mice was successfully established in this study. However, UA treatment significantly and dose-dependently reduced the lung coefficient of mice ($p < 0.01$; $p < 0.05$).

Table 1: Effect of UA on lung coefficient of mice with pulmonary fibrosis ($n = 6$)

Group	Concentration (mg/kg)	Lung coefficient (mean \pm SEM)
Control	-	7.16 \pm 0.28
BLM	15	10.39 \pm 0.23 [#]
UAL	25	9.32 \pm 0.18 ^{**}
UAM	50	8.64 \pm 0.26 ^{**}
UAH	100	8.20 \pm 0.33 ^{**}
PA	5	8.15 \pm 0.31 ^{**}

Values are mean \pm SEM; [#] $p < 0.01$, compared with control; ^{**} $p < 0.01$, compared with BLM mice

Effect of usnic acid on lung histopathology

As illustrated in Figure 2, typical PF-induced changes in lung tissue morphology were observed in BLM group. These changes include aggregates of neutrophils, congestion in alveoli, bleeding, hemorrhage and thickened walls of alveoli. In contrast, the control mice had normal histological appearance (Figure 3). Bleomycin exposure caused extensive lung tissue lesions, collagen deposition and marked fibrosis, suggesting that the PF mouse model was successfully established. In contrast, UA administration significantly reversed these bleomycin-associated lesions and fibrosis.

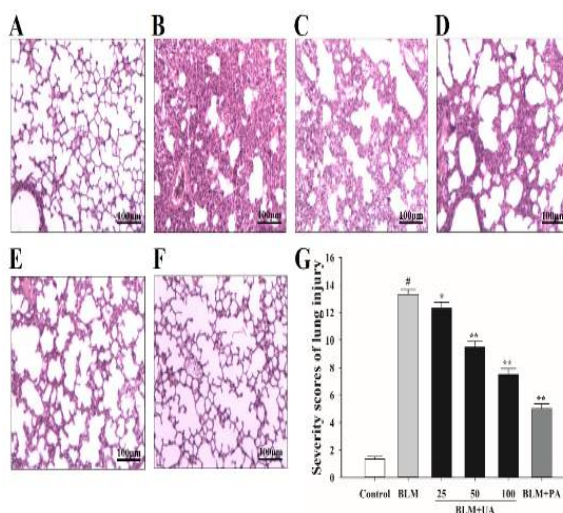


Figure 2: Influence of UA on histopathology of PF mice (H & E). (A) Control; (B) BLM; (C) BLM + 25 mg UA/kg; (D) BLM + 50 mg UA/kg; (E) BLM + 100 mg UA/kg; (F) BLM + PA group, (all x100 magnification); (G) lung injury scores. Data are mean \pm SEM ($n = 6$); [#] $p < 0.01$ vs. control group; ^{*} $p < 0.05$ vs. BLM group; ^{**} $p < 0.01$ vs. BLM group

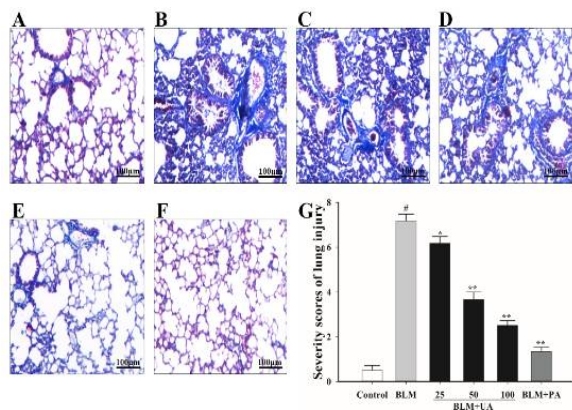


Figure 3: Effect of UA on histopathological variations in mice with pulmonary fibrosis (Masson staining). With Masson's trichrome, the nuclei stain dark red or purple, muscle stains red, and collagen stains blue. (A) Control; (B) BLM; (C) BLM + 25 mg UA/kg; (D) BLM + 50 mg UA/kg; (E) BLM + 100 mg UA/kg; (F) BLM + PA group; (magnification: x100); (G) lung injury scores. Results are mean ± SEM; [#]*p* < 0.01, relative to control; ^{*}*p* < 0.05, relative to BLM group; ^{**}*p* < 0.01 vs. BLM mice

Effect of usnic acid on pulmonary MDA level and SOD activity

As shown in Figure 4 A, compared with normal control group, the level of MDA in the model group was markedly increased by 86.70 % (13.84 ± 0.91 vs. 25.84 ± 1.49) and the activity of SOD in the model group was decreased by 26.87 % (10.98 ± 0.38 vs. 8.03 ± 0.37). However, prior treatment with UA (25, 50 and 100 mg/kg) and PA effectively suppressed the MDA level, and reversed the reduction in SOD activity. The levels of MDA were decreased by UA in a concentration-dependent manner, when compared with the model group (UA at doses of 25, 50 and 100 mg/kg decreased MDA by 14.33, 27.18 and 33.43 %, respectively; but increased SOD by 12.43, 13.65 and 17.32 %, respectively).

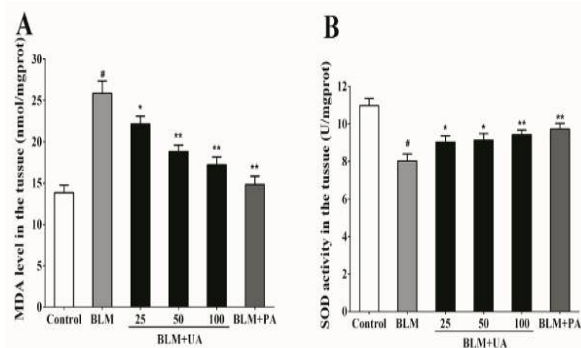


Figure 4: Effect of usnic acid on MDA (A) and SOD (B) levels in the lung tissues. Values are mean ± SEM (*n* = 6); [#]*p* < 0.01, relative to control; ^{*}*p* < 0.05; ^{**}*p* < 0.01, relative to BLM mice

Influence of UA on pulmonary HYP content

The content of HYP in the model group was markedly increased by 123.84 % (1.46 ± 0.08 vs. 0.65 ± 0.08), relative to the control group (Figure 5). However, compared to the model group, the level of HYP was significantly and dose-dependently reduced by 22.59, 29.35 and 31.99 % by UA treatment at doses of 25, 50 and 100 mg/kg, respectively. The use of PA suppressed the content of HYP by 41.72 % (0.85 ± 0.05 vs 1.46 ± 0.08).

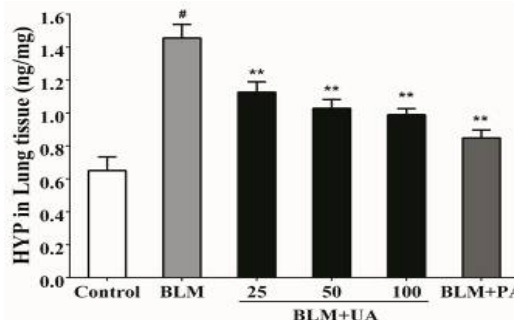


Figure 5: Influence of usnic acid on hydroxyproline levels. Values are presented as mean ± SEM. [#]*p* < 0.01, compared to control; ^{*}*p* < 0.05; ^{**}*p* < 0.01, compared to BLM mice

Effect of UA on levels of pulmonary inflammatory cytokine levels

The results in Figure 6 show that the levels of TNF-α, IL-1β, IL-6 and TGF-β1 in the model group were significantly increased by 49.49 % (36.90 ± 0.93 vs. 24.68 ± 1.14), 40.27 % (76.99 ± 1.80 vs. 54.89 ± 1.97), 40.27 % (76.99 ± 1.80 vs. 54.89 ± 1.97), 41.13 % (38.22 ± 1.00 vs. 27.08 ± 0.68), and 49.14 % (132.66 ± 3.61 vs. 88.95 ± 3.16), respectively. However, pretreatment with UA markedly reduced the levels of TNF-α, IL-1β, IL-6 and TGF-β1 (^{*}*p* < 0.05; ^{**}*p* < 0.01).

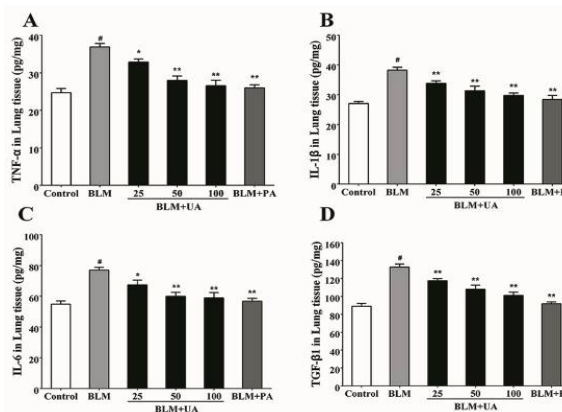


Figure 6: Effect of UA on pulmonary levels of TNF-α (A), IL-1β (B), IL-6 (C) and TGF-β1 (D). Data are

presented as mean \pm SEM ($n = 6$ in each group); # $p < 0.01$, relative to control; * $p < 0.05$; ** $p < 0.01$, relative to bleomycin group

DISCUSSION

Based on pathological features, PF is divided into early and late stages. The early stage is characterized by inflammatory cell invasion, secretion of inflammatory mediators, and damage to alveolar epithelial and capillary endothelial cells. In the late stage, fibroblasts become activated and promote the secretion of collagen and other extracellular matrix proteins. Under the effect of growth factors, extracellular matrix becomes excessively secreted and collagen is excessively biosynthesized, leading to abnormal reconstruction in lung tissue and fibrillation [11].

Bleomycin (BLM) is an anti-tumor polypeptide drug, but unfortunately it causes PF. Studies indicate that morphological characteristics of BLM-induced PF in mouse are closely related to those of PF in humans [12]. Hence, the BLM-induced PF animal model has been widely used in the study of PF. In the animal model of BLM-induced PF, the administration routes of BLM include intratracheal and intranasal routes, as well as intravenous and intraperitoneal injections.

The pathological features of BLM-induced mouse PF model established by intraperitoneal injection of BLM are closer to those of human PF because the diseased region is under the pleural and around the bronchus. Moreover, BLM-induced PF occurs in a time-dependent manner [13]. From the 7th to 14th day after BLM administration, PF is at the early phase of inflammatory response. At this stage, a large number of macrophages and neutrophils infiltrate the lung tissue on the 7th day after BLM administration. On the 14th day, inflammatory activity reaches its peak and desmocytes markedly proliferate. On the 21st day, PF is successfully established [6,10].

In the present study, mice were intraperitoneally injected with multiple doses of BLM to establish the PF model, and 21 days later, it was observed that the lung coefficient of mice was significantly increased. The results of H&E and Masson procedures showed damaged alveolar structure, infiltration of large amounts of inflammatory cells, and deposition of collagen fibrils in the BLM group. Moreover, there were marked increases in malondialdehyde, hydroxyproline, tumor necrosis factor- α , interleukins-1 β and 6, and transforming growth factor- β 1. These features demonstrate

successful establishment of the mouse PF model in this study.

The early stage of PF is characterized by inflammatory activity. Neutrophils and macrophages excessively accumulate in pulmonary tissue, and a lot of inflammatory cytokines and chemokines are secreted to destroy the balance between inflammatory and anti-inflammatory and profiles, ultimately resulting in lung injury. Hydroxyproline (HYP) is a major component of collagen fibrils, accounting for about 13.4 % [14]. Thus, HYP content indirectly reflects the level of collagen fibrils and the severity of PF. In addition, TNF- α , a pre-inflammatory factor secreted by macrophages and lymphocytes, causes inflammation and stimulates inflammatory cells (e.g., neutrophils and lymphocytes) to secrete other inflammatory cytokines, thereby triggering further inflammatory responses.

Reports have indicated that TNF- α also activates and accelerates the proliferation of fibroblasts, and promotes the biosynthesis of collagen [15]. In addition, IL-1 β is also a pre-inflammatory factor mainly secreted by macrophages. In the early phase of PF, the content of IL-1 β increases in the lung tissue, but returns to the normal level with the development of PF [16]. Hence, IL-1 β may induce and enhance inflammatory activity in the early stage of PF. It has been reported that IL-6 not only induces powerful inflammatory activity, but also activates proliferation of fibroblasts and collagen levels, and inhibits breakdown of extracellular matrix [17].

The cytokine, TGF- β 1, which regulates cells proliferation, differentiation and apoptosis, promotes the biosynthesis and secretion of extracellular matrix and promotes its pathological accumulation in the lungs [18]. Moreover, TGF- β 1 inhibits the apoptosis of fibroblasts, TGF- β 1 and improves the secretion of fibronectin that is closely related to PF through activation of the transcription of related genes. In order to regulate the secretion of extracellular matrix, TGF- β 1 also inhibits the secretion of protein kinase and upregulates suppressors of the enzyme, leading to reduction of degradation of extracellular matrix [19]. This study showed that the lung contents of hydroxyproline, and the cytokines assayed were significantly elevated in the BLM group, relative to control. However, these increases were significantly reduced after UA treatment, indicating that UA possesses anti-inflammatory capacity which may play an important part on the prevention and treatment of PF.

The understanding of the etiology of PF is a continuous and evolving process. In the early stages, PF was thought to be just an inflammatory disease, and so it was often treated with anti-inflammatory and immune-suppressing drugs, but the clinical efficiency was only 20% [20]. However, research evidence have indicated that oxidative stress is also a very important factor in the development of PF. Reactive oxygen species (ROS) are markers implicated in the pathogenesis of oxidative stress [21].

In general, pulmonary epithelial cell apoptosis is associated with the development of PF, and ROS induce alveolar epithelial cell apoptosis through lipid peroxidation and DNA mutation on the alveolar epithelial cell membrane. Moreover, ROS promote the secretion of inflammatory cytokines, platelet-derived growth factor and transforming growth factor by activating protein tyrosine kinase and protein phosphatase pathway. These cytokines activate fibroblasts to secrete collagen fibers, resulting in worsening of PF. In addition, ROS affect the degradation of extracellular matrix, including collagen, elastin, fibrin and proteoglycan.

Studies have indicated that ROS elevate the expression of plasminogen activator inhibitor-1 (PAI-1) via upregulation of mitogen-activated protein kinase (MAPK) signaling pathway [22]. Thus, ROS interfere with the normal degradation of extracellular matrix, leading to its massive deposition. In order to protect itself against damage due to oxidative stress, the body produces a variety of endogenous antioxidants, among which is SOD, an important enzyme that scavenges oxygen free radicals. Under the catalysis of SOD, the superoxide anion $O_2^{\cdot-}$ is converted to H_2O_2 , and H_2O_2 is further transformed to non-toxic H_2O by catalase [23]. If un-neutralized, the oxygen free radical attacks the polyunsaturated fatty acids in biological membranes, and further triggers lipid peroxidation to produce malonaldehyde (MDA) [24]. Therefore, the contents of SOD and MDA reflect the antioxidant capacity of tissues.

In the present study, the content of SOD was markedly reduced, while the content of MDA was significantly increased in lung tissues of BLM mice. However, following pretreatment with UA, the content of SOD was markedly increased, while MDA level was significantly reduced in the lung tissues when compared to the BLM group. These results suggest UA possesses antioxidant capacity which may be beneficial in the prevention and treatment of PF.

CONCLUSION

This study has demonstrated that usnic acid inhibits inflammatory response as well as pro-oxidant damage in pulmonary tissue of PF mice via attenuation of inflammatory response and oxidative stress. These findings suggest that UA has a therapeutic potential for the management of pulmonary fibrosis.

DECLARATIONS

Acknowledgement

This work was supported by grants from Special Project on the Integration of Industry, Education and Research of Guangdong Province (no. 2014B090902002).

Conflict of interest

No conflict of interest is associated with this work.

Contribution of authors

We declare that this work was done by the authors named in this article and all liabilities pertaining to claims relating to the content of this article will be borne by the authors.

Open Access

This is an Open Access article that uses a funding model which does not charge readers or their institutions for access and distributed under the terms of the Creative Commons Attribution License (<http://creativecommons.org/licenses/by/4.0>) and the Budapest Open Access Initiative (<http://www.budapestopenaccessinitiative.org/read>), which permit unrestricted use, distribution, and reproduction in any medium, provided the original work is properly credited.

REFERENCES

1. Spagnolo P, Maher TM, Richeldi L. Idiopathic pulmonary fibrosis: Recent advances on pharmacological therapy. *Pharmacol Ther* 2015; 152: 18-27.
2. Fukunaga S, Kakehashi A, Sumida K, Kushida M, Asano H, Gi M, Wanibuchi H. Integrative analyses of miRNA and proteomics identify potential biological pathways associated with onset of pulmonary fibrosis in the bleomycin rat model. *Toxicol Appl Pharmacol* 2015; 286(3): 188-197.
3. Sue M, Higashi N, Shida H, Kogane Y, Nishimura Y, Adachi H, Kolaczowska E, Kepka M, Nakajima M, Irimura T. An iminosugar-based heparanase inhibitor
Trop J Pharm Res, December 2019; 18(12): 2568

- heparastatin (SF4) suppresses infiltration of neutrophils and monocytes into inflamed dorsal air pouches. *Int Immunopharmacol* 2016; 35: 15-21.
4. Matsuzawa Y, Kawashima T, Kuwabara R, Hayakawa S, Irie T, Yoshida T, Rikitake H, Wakabayashi T, Okada N, Kawashima K et al. Change in serum marker of oxidative stress in the progression of idiopathic pulmonary fibrosis. *Pulm Pharmacol Ther* 2015; 32: 1-6.
 5. Ingólfssdóttir K. Usnic acid. *Phytochemistry* 2002; 61(7): 729-736.
 6. Odabasoglu F, Cakir A, Suleyman H, Aslan A, Bayir Y, Halici M, Kazaz C. Gastroprotective and antioxidant effects of usnic acid on indomethacin-induced gastric ulcer in rats. *J Ethnopharmacol* 2006; 103(1): 59-65.
 7. Su Z-Q, Mo Z-Z, Liao J-B, Feng X-X, Liang Y-Z, Zhang X, Liu Y-H, Chen X-Y, Chen Z-W, Su Z-R et al. Usnic acid protects LPS-induced acute lung injury in mice through attenuating inflammatory responses and oxidative stress. *Int Immunopharmacol* 2014; 22(2): 371-378.
 8. *Guide for the Care and Use of Laboratory Animals*, NIH publication NO. 85-23, revised 1996.
 9. Papiris SA, Daniil ZD, Malagari K, Kapotsis GE, Sotiropoulou C, Milic-Emili J, Roussos CJRM. The Medical Research Council dyspnea scale in the estimation of disease severity in idiopathic pulmonary fibrosis. *Respir Med* 2005; 99(6): 755-761.
 10. Takao Y, Mikawa K, Nishina K, Obara H. Attenuation of acute lung injury with propofol in endotoxemia. *Anesth Analg* 2005; 100(3): 810-816.
 11. Aoki Y, Kojo Y, Yamada S, Onoue S. Respirable dry powder formulation of bleomycin for developing a pulmonary fibrosis animal model. *J Pharm Sci* 2012; 101(6): 2074-2081.
 12. Moore BB, Hogaboam CM. Murine models of pulmonary fibrosis. *Am J Physiol Lung Cell Mol Physiol* 2008; 294(2): L152-160.
 13. Scheule RK, Perkins RC, Hamilton R, Holian AJA. Bleomycin stimulation of cytokine secretion by the human alveolar macrophage. *Am J Physiol Lung Cell Mol Physiol* 1992; 262(4): L386-L391.
 14. Akgedik R, Akgedik S, Karamanli H, Uysal S, Bozkurt B, Ozol D, Armutcu F, Yildirim Z. Effect of resveratrol on treatment of bleomycin-induced pulmonary fibrosis in rats. *Inflammation* 2012; 35(5): 1732-1741.
 15. Freeburn RW, Kendall H, Dobson L, Egan J, Simler NJ, Millar AB. The 3' untranslated region of tumor necrosis factor-alpha is highly conserved in idiopathic pulmonary fibrosis. *Eur Cytokine Netw* 2001; 12(1): 33-38.
 16. Crosby LM, Waters CM. Epithelial repair mechanisms in the lung. *Am J Physiol Lung Cell Mol Physiol* 2010; 298(6): L715-731.
 17. Ortiz LA, Gambelli F, McBride C, Gaupp D, Baddoo M, Kaminski N, Phinney DG. Mesenchymal stem cell engraftment in lung is enhanced in response to bleomycin exposure and ameliorates its fibrotic effects. *Proc Natl Acad Sci U S A* 2003; 100(14): 8407-8411.
 18. Wang D, Morales JE, Calame DG, Alcorn JL, Wetsel RA. Transplantation of human embryonic stem cell-derived alveolar epithelial type II cells abrogates acute lung injury in mice. *Mol Ther* 2010; 18(3): 625-634.
 19. Thabut G, Christie JD, Ravaud P, Castier Y, Dauriat G, Jebrak G, Fournier M, Leseche G, Porcher R, Mal H. Survival After Bilateral Versus Single-Lung Transplantation for Idiopathic Pulmonary Fibrosis. *Ann Intern Med* 2009; 151(11): 767.
 20. Gharaee-Kermani M, Hu B, Thannickal VJ, Phan SH, Gyetko MR. Current and emerging drugs for idiopathic pulmonary fibrosis. *Expert Opin Emerg Drugs* 2007; 12(4): 627.
 21. Daniil ZD, Papageorgiou E, Koutsokera A, Kostikas K, Kiriopoulos T, Papaioannou AI, Gourgoulialis KI. Serum levels of oxidative stress as a marker of disease severity in idiopathic pulmonary fibrosis. *Pulm Pharmacol Ther* 2008; 21(1): 26-31.
 22. Liu RM. Oxidative stress, plasminogen activator inhibitor 1, and lung fibrosis. *Antioxid Redox Signal* 2008; 10(2): 303-319.
 23. Wang P, Ye XL, Liu R, Chen HL, Liang X, Li WL, Zhang XD, Qin XJ, Bai H, Zhang W et al. Mechanism of acute lung injury due to phosgene exposition and its protection by caffeic acid phenethyl ester in the rat. *Exp Toxicol Pathol* 2013; 65(3): 311-318.
 24. Marnett LJ. Oxy radicals, lipid peroxidation and DNA damage. *Toxicology* 2002; 181(181-182): 219-222.