

Conjoined twin presenting as a case of “hanging breech” in labor - Case report

LAIMA CH^{1,2}, MELLER TB², NWUKWA G²

¹Department of Obstetrics and Gynaecology, College of Medical Sciences, Gombe State University, ²Department of Obstetrics and Gynaecology, State Specialist Hospital Gombe, Gombe, Nigeria

ABSTRACT

Conjoined twin is a rare phenomenon. This is a report of suspected undiagnosed bicephalus conjoined twin that presented as hanging breech which was delivered by craniotomy. It presented with management challenge, from attempted home delivery to a primary healthcare facility and finally referred to the Specialist Hospital. The diagnosis was made after delivery. The finding was a male stillborn infant with normal body parts but two heads. Clinicians should look out for these complications when confronted with hanging breech.

Key words: Conjoined-twin; hanging breech; labor.

Introduction

Bicephalus conjoined twins are among the rarest of conjoined twins reported in literature. Bicephalus conjoined twins presenting as a cause of hanging breech are even rarer, if ever reported. Conjoined twin is an extremely rare phenomenon occurring in about 1 in 49,000 to 1 in 189,000 births.^[1] In the United States, a value of 1 in 33,000 to 1 in 165,000 has been reported.^[2] The incidence of bicephalus conjoined twin is not clear in literature due to its rarity; however, a case has been reported by Kaufman.^[3]

Case History

A 19-year-old gravida 2 para 1, one alive, whose last child birth was 3 years ago, presented on 30th January 2019 at the labor ward with arrest of the after-coming head of breech in labor. Her first pregnancy was unsupervised, and delivery was done at home to an infant who is alive and well. There was no family history of twinning.

The patient did not book index pregnancy and could not remember her last menstrual period but thinks she was term; she started labor at home with a traditional birth attendant. However, when the head could not be delivered after the delivery of the body, they rushed to a primary health center. From there, they were referred to our hospital, with hanging breech at term.

A preliminary ultrasound scan was done in the labor ward, which did not reveal anything significant. A provisional diagnosis of hanging breech secondary to suspected hydrocephalus with intrauterine fetal death was made. The patient was prepared for and had craniotomy in the theater. After craniotomy with some difficulty, the baby was eventually delivered. The finding was, however, a two-headed male infant, having one neck, trunk, and a pair of hands and legs, weighing 2.8 kg [Figure 1].

Address for correspondence: Dr. Laima CH,
Department of Obstetrics and Gynaecology, Federal Teaching Hospital Gombe, Gombe, Nigeria.
E-mail: cdlaima@yahoo.com

This is an open access journal, and articles are distributed under the terms of the Creative Commons Attribution-NonCommercial-ShareAlike 4.0 License, which allows others to remix, tweak, and build upon the work non-commercially, as long as appropriate credit is given and the new creations are licensed under the identical terms.

For reprints contact: reprints@medknow.com

How to cite this article: Laima CH, Meller TB, Nwukwa G. Conjoined twin presenting as a case of “hanging breech” in labor – Case report. Trop J Obstet Gynaecol 2019;36:299-300.


Access this article online	
Website: www.tjogonline.com	Quick Response Code 
DOI: 10.4103/TJOG.TJOG_29_19	

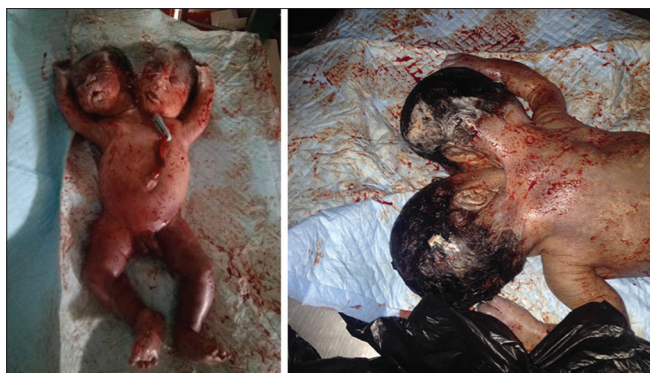

Figure 1: Bicephalus conjoined twins – anterior view. Bicephalus conjoined twins – posterior view

The parents did not consent for postmortem X-rays or autopsy.

The patient was placed on antibiotics and other medications; she was counselled and discharged after 48 hours.

Discussion

Conjoined twins are monozygotic twins joined in the uterus. It is an extremely rare phenomenon occurring in about 1 in 49,000 to 1 in 189,000 births.^[1,2] The incidence is, however, higher in South-West Asia and Africa and has also been reported in other animals.^[1,4,5]

Most conjoined twins were females with a ratio of 3:1 which carries a better survival rate.^[1,2] The stillbirth rate of conjoined twins is 40%–60%; one-third of those born a life will die in the first 24 hours.^[2]

There are mainly two types of conjoined twins: the symmetrical and asymmetrical – in symmetrical, two fetuses can be identified; whereas in asymmetrical, only a single fetus is identified with doubling of a particular organ.^[6] Examples of symmetrical are thoracoomphagus (74%), pyrophagus 18%, ischiopagus 6%, and craniopagus (2%). Asymmetrical conjoined twins are very rare and include parasitic twins and bicephalus conjoined twins.^[6,7]

In the case presented, only the head is doubled on a single neck grossly. (No X-rays were done; this is because the parents did not give consent for X-ray or postmortem autopsy.) It means splitting here could have started before gastrulation.

Conjoined twins can be diagnosed by ultrasound as early as 8 weeks of gestation; however, even with ultrasound, the asymmetric forms can present diagnostic challenge.^[8] This can explain why the ultrasound missed the diagnosis. These women should have been delivered abdominally as the vaginal route will increase morbidity. However, obstetricians should be wary of cases of hanging breech and suspect rare occurrence like this.

Various modalities of treatments have been tried for conjoined breech with appreciable success depending on the type.^[9,10] However, the chances for survival are extremely rare.

Delivery of conjoined twins and its management is often associated with moral, ethical, and religious concerns;^[9,10] while some attribute it to witchcraft and superstitious beliefs, some are worried because of the stigma associated with it.^[9]

Financial support and sponsorship

Nil.

Conflicts of interest

There are no conflicts of interest.

References

1. Carnevale CF, Borges MV, Affonso BB, Pinto RA, Tannuri U, Maksound JG. Importance of angiographic study in a preoperative planning of conjoined twins: Case report. *Clinics (Sao Paulo)* 2006;61:167-70.
2. De Ugart DA, Boechat MI, Shaw WW, Laks H, Williams H, Atkinson JB. Parasitic omphalopagus complicated by omphalocele and congenital heart disease. *J Pediatr Surg* 2002;37:1357-8.
3. Kaufman MH. The embryology of conjoined twins. *Childs Nerv Syst* 2004;20:508-25.
4. Mazzullo G, Maer F, Rapisarda G, Marins F. Deralaelphous cephalothoracopagus in kittens. *Anat Histol Embryol* 2009;8:327-9.
5. Hartwell S. Feline medical curiosities: Conjoint Kittens. Messy beast. Available from: <http://www.messybeast.com/freak-conjoined.htm>. [Last accessed on 2018 Apr 24].
6. Jackson OA, Low DW, Larossa D. Conjoined twin separation: Lessons learned. *Plast Reconstr Surg* 2012;129:956-63.
7. Carlson TL, Daugherty R, Miller A, Gbulie UB, Wallace R. Successful separation of conjoined twins: The contemporary experience and historic review in Memphis. *Ann Plast Surg* 2018;80 (6S Suppl 6):S333-9.
8. Matthew RP, Francis S, Basti RS, Suresh HB, Rajarathnam A, Cunha PD, *et al.* Conjoined twins – Role of imaging and recent advances. *J Ultrason* 2017;17:259-66.
9. Thomasme DL, Muraskas J, Marshal PA, Myers T, Tomich P, O'Neil JA Jr. The ethics of caring for conjoined twins. *The Lakeberg twins*. *Hastings Cent Rep* 1996;26:4-12.
10. Burmagina Y. Duplicats incomplete, dicephalus dipus dibrachius. 2006. Available from: <http://www.the.fetus.net/page/page.php?d=1420>. [Last accessed on 2019 Mar 09].