

Original Article

Correlation between transabdominal ultrasound features of ectopic gestation and surgical findings at the university college hospital, Ibadan: A preliminary review

OBAJIMI GO, SMART AE¹, ADEKANMI AJ¹, ADENIJI-SOFOLUWE A¹, JINADU FO²

Department of Obstetrics and Gynaecology, University College Hospital, Ibadan, ¹Department of Radiology, University College Hospital, Ibadan, ²Department of Radiology, Lagos State Teaching Hospital (LASUTH), Ikeja, Lagos

ABSTRACT

Introduction: Ectopic pregnancy in Sub-Saharan Africa has an incidence of 1%-5% of all deliveries and 5%-10% of all gynaecological admissions. The fallopian tube is the most common site of occurrence of an ectopic pregnancy and ruptured ectopic is the commonest variety seen in low resource settings.

Materials and Method: This is a 2-year retrospective diagnostic accuracy test of transabdominal ultrasonographic findings in ectopic pregnancy, using surgical findings as the gold-standard. The study was conducted at the Radiology Department of the University College Hospital, Ibadan, Nigeria between 1 January 2013 and 31 December 2014. Radiological request cards of 41 women who were clinically suspected to have an ectopic pregnancy and had a transabdominal ultrasound scan were retrieved, however, only 34 were suitable for analysis. Data analysis was done using the Statistical Package for Social Sciences (SPSS) version 20 (Chicago, IL, USA). A *P* value of <0.05 was regarded as statistically significant.

Results: The ages of the women ranged between 20 and 40 years with a mean age of 29.94 ± 5.06 years. The mean gestational age at time of scan was 44.8 days (6 weeks + 3 days). Out of 34 patients reviewed in this study, 29 had surgical interventions in the course of their management and 26 had ectopic gestation confirmed at surgery. This study found a Sensitivity of 88.4%, Specificity of 37.5% and Positive and Negative predictive values of 82.1% and 50%, respectively.

Conclusion: This preliminary study suggests that transabdominal ultrasonography is a useful and reliable means of diagnosing ectopic pregnancy particularly in low-resource settings where availability and or technical skill for transvaginal ultrasonography is not readily available.

Key words: Correlation; ectopic gestation; surgical findings; transabdominal ultrasound.

Introduction

Ectopic pregnancy refers to the implantation of a fertilized ovum anywhere outside the endometrial lining of the uterine cavity.^[1] It can occur in any part of the fallopian tube, the cervix, ovary or elsewhere in the peritoneal cavity. The commonest site of occurrence of an ectopic pregnancy is within the fallopian tube (95.5%), with about three-quarters


occurring in the ampullary region, followed by ovarian (3.2%) and abdominal (1.3%) implantation sites.^[2]

Address for correspondence: Dr. Obajimi GO, Department of Obstetrics and Gynaecology, University College Hospital, Ibadan, Nigeria.
E-mail: gbolahanobajimi@gmail.com

This is an open access journal, and articles are distributed under the terms of the Creative Commons Attribution-NonCommercial-ShareAlike 4.0 License, which allows others to remix, tweak, and build upon the work non-commercially, as long as appropriate credit is given and the new creations are licensed under the identical terms.

For reprints contact: reprints@medknow.com

How to cite this article: Obajimi GO, Smart AE, Adekanmi AJ, Adeniji-Sofoluwe A, Jinadu FO. Correlation between transabdominal ultrasound features of ectopic gestation and surgical findings at the university college hospital, Ibadan: A preliminary review. *Trop J Obstet Gynaecol* 2019;36:265-70.

Access this article online	
Website: www.tjogonline.com	Quick Response Code 
DOI: 10.4103/TJOG.TJOG_39_18	

The global incidence of ectopic pregnancy is said to be about 1-2 in a 100 pregnancies.^[2] Ectopic pregnancy significantly contributes to maternal morbidity and mortality particularly in developing countries and the Sub-Sahara Africa.^[3-5] Hospital-based surveys in Nigeria have reported an incidence of 1%-5% of all deliveries^[3,5-7] and 5%-10% of all gynaecological admissions.^[3,4,6-9] Although mortality from ectopic gestation is relatively lower than other causes of maternal deaths, the associated morbidity is often grave, leading to poor fertility and obstetric outcomes.^[10]

Tubal damage is an important aetiological factor associated with ectopic gestation. However, several other risk factors have been associated with ectopic pregnancy, such as pelvic inflammatory disease (PID),^[6,11] previous history of induced abortions^[3,11] contraceptive failure^[12] and assisted reproductive techniques (ART).^[13]

Clinical presentation varies in cases of ruptured or unruptured ectopic pregnancy with a vast majority of patients presenting with the ruptured variety in developing countries. Due to late presentation, most cases of ectopic gestation present as acute emergencies^[7,14] contributing to nearly half (48.5%) the number of gynaecological emergencies in a study by Anolu *et al.* in Lagos, Nigeria.^[11]

Menstrual and reproductive history accompanied by a high level of suspicion, are important clinical correlates in women of reproductive age who present with abdominal or pelvic symptoms, since cardiovascular symptoms may oftentimes be the obvious presenting feature in cases of ruptured ectopic pregnancy.^[15]

Investigations needed to confirm a diagnosis include serum B-HCG and a pelvic ultrasound scan.^[16] The transvaginal route is the ideal sonographic approach to imaging patients with ectopic gestation since most present in the early first trimester.^[17-19] However, the deployment of transvaginal ultrasonography in early pregnancy is not widely practiced in Nigeria, due to the non-availability of the equipment and/or technical skills required to perform a transvaginal ultrasound alongside the prevailing negative socio-cultural beliefs. Therefore, transabdominal ultrasonography has been the preferred choice in evaluating ectopic pregnancies in low-resource settings.^[14,20] A study evaluating the reliability of transabdominal ultrasonography in diagnosing ectopic pregnancy and its complications is not only imperative but useful in settings where transvaginal ultrasonography is not widely available and acceptable.

Materials and Method

This study is a preliminary 2-year retrospective diagnostic accuracy test of transabdominal ultrasonographic findings in ectopic pregnancy, using surgical findings as the gold-standard. The study was carried out at the Radiology department of the University College Hospital Ibadan, Nigeria. Radiological request cards of 41 women between 2013 and 2014 who were clinically suspected to have ectopic pregnancy and had a transabdominal pelvic ultrasound scan that either confirmed or refuted ectopic pregnancy as the definitive diagnosis were retrieved.

The patients had presented with clinical complaints of one or more of lower abdominal pain, bleeding per vaginam, fainting episodes and dizziness with a background history of amenorrhea and positive pregnancy test. The ultrasonographic scan either confirmed ectopic pregnancy as the diagnosis or suggested it as a differential diagnosis in the setting of a non-specific adnexal mass.

Thirty-four of these women had their case records which also contained their operation notes. From the case records, demographic data, presenting complaints, relevant gynaecological history (last menstrual period, positive serum pregnancy test, gestational age) haematological status (packed cell volume), intraoperative findings -presence of an ectopic gestation, status of the ectopic gestation, (ruptured or unruptured), haemoperitoneum, presence of contralateral disease and incidental findings, type of surgical procedure performed as well as the histological finding of the surgical specimen were extracted.

The data were inputted into the Statistical Package for Social Sciences (SPSS) version 20 (Chicago, IL, USA). Qualitative data were summarized using percentages whereas quantitative data were summarized using mean and standard deviation and were presented using appropriate tables. Measures of ultrasound accuracy such as sensitivity, specificity, positive predictive values and negative predictive values were also computed from cross-tabulations of sonographic diagnosis versus intraoperative surgical findings. The concordance between intraoperative surgical and histological findings was determined from the corresponding cross-tabulation using kappa statistic.

Results

The ages of the women ranged from 20 to 40 years with a mean age of 29.94 ± 5.06 years. The mean gestational age at time of scan was 44.8 days (6 weeks + 3 days) [Figure 1]. Out of the 41 request cards of patients who met the eligibility

criteria, 34 (82.9%) case files were found and used for final analysis. Majority of the patients (72%) presented with abdominal pain and 23% (8/34) presented with vaginal bleeding [Figure 2].

Table 1 shows the ultrasound findings in the uterus and adnexa. Of the total women studied, 15 (44%) were reported to have had a bulky uterus (>8 weeks); 28 (82%) women had endometrial reaction (endometrial thickness and or pseudogestational sac) detected sonographically, while an adnexal mass was seen in 27 patients (79.4%). Live ectopic gestation was reported in only 4 patients (12%). Twenty-two patients (65%) had haemoperitoneum at ultrasonography and over two-thirds of the patients in this category had extensive haemoperitoneum involving the Morrison's pouch and paracolic gutters [Figure 3].

Twenty-nine patients had surgical interventions in the course of their management. Twenty-six of them had ectopic pregnancy confirmed at surgery and had salpingectomy, including one patient who had salpingo-oophorectomy, on account of a ruptured ovarian ectopic gestation. Two patients had cystectomy for ovarian cysts; two others had manual vacuum aspiration for incomplete abortion; one patient had exploratory laparotomy for complicated unsafe abortion; while three patients who were followed up were subsequently found not to have ectopic pregnancy and had no surgical interventions done on them.

Deploying transabdominal scan as a diagnostic test for detecting ectopic pregnancy, this study found a sensitivity of 88.4%, specificity of 37.5%, positive and negative predictive values of 82.1% and 50%, respectively [Table 2]. However, the diagnostic accuracy test of transabdominal ultrasound on ruptured ectopic pregnancy showed sensitivity and specificity of 61% and 100%, respectively, while positive and negative predictive values were 100% and 44%, respectively [Table 2]. The commonest complication of ectopic gestation in this study was hemoperitoneum which was seen in 23 patients (88.5%). Of the women in whom hemoperitoneum was detected on transabdominal ultrasound, 19 (85%) were

confirmed to have hemoperitoneum at surgery. The negative predictive value for haemoperitoneum was, however, 40% [Table 2]. Concordance between surgical diagnosis (using intra-operative findings) and histological diagnosis was computed with a kappa of 1.00, implying total agreement between the surgical and histological diagnoses in the cases where surgical specimen was sent for histology.

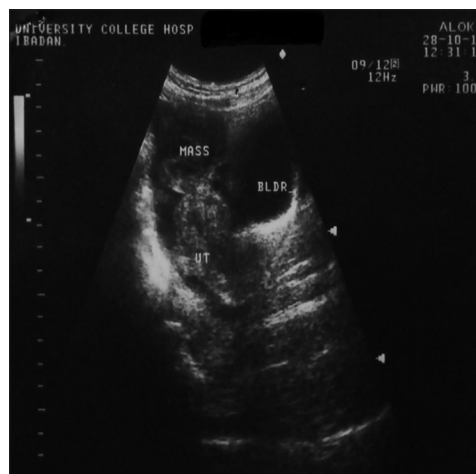

Figure 1: Transabdominal ultrasonography of the mid pelvis showing a complex mass adjacent the uterine fundus

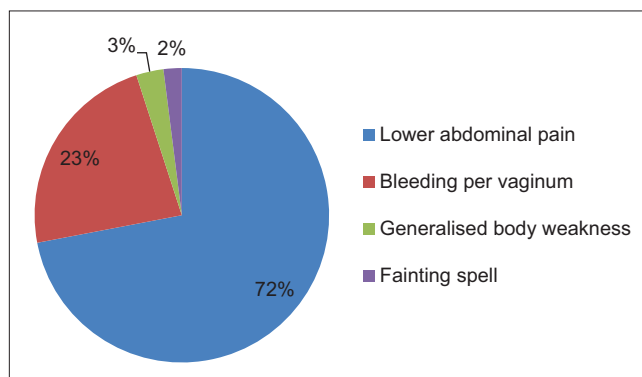


Figure 2: Presenting complaints of the patients

Table 1: Ultrasound findings in screening sonography for ectopic pregnancy

Ultrasound findings	Yes (%)	No (%)	Total
Bulky uterus	15 (44)	19 (56)	34
Endometrial reaction	28 (82)	6 (18)	34
Adnexal mass	27 (79.4)	7 (20.6)	34
Peripheral colour flow (ring of fire appearance)	11 (41)	16 (59)	27
Live ectopic gestation	4 (11.8)	30 (88.2)	34
Location of adnexal mass	Right 15 (55.6)	Left 12 (44.4)	27

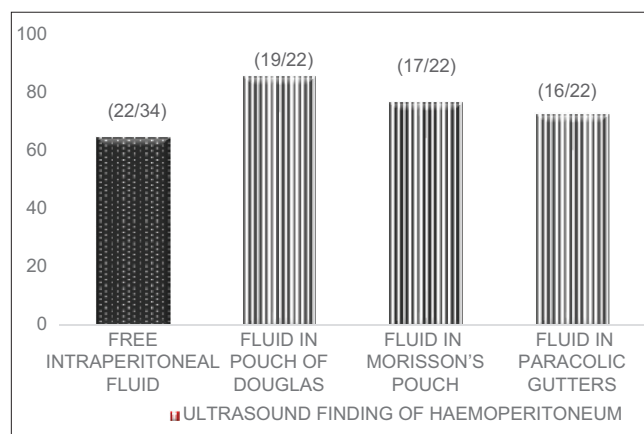


Figure 3: Ultrasound findings suggestive of haemoperitoneum in screening transabdominal ultrasound for ectopic pregnancy

Table 2: Diagnostic accuracy of transabdominal ultrasonography in predicting ectopic gestation, ruptured ectopic gestation and haemoperitoneum

Ultrasound diagnosis	Sensitivity (%)	Specificity (%)	Positive predictive value (%)	Negative predictive value (%)
EG	88.4	37.5	82.1	50.0
REG	61	100	100	44
HAE	74	57	85	40

EG, Ectopic gestation; REG, Ruptured ectopic gestation; HAE, Haemoperitoneum

Discussion

Ectopic pregnancy presents a major public health challenge among women of reproductive age in Nigeria.^[3-9] The purpose of this study was to evaluate the diagnostic accuracy of transabdominal ultrasonography using surgical diagnosis as the gold standard in patients clinically suspected to have ectopic pregnancy. Transvaginal ultrasound offers a better approach in examining the uterus and adnexa in early pregnancy, both for evaluation of normal early pregnancy, ectopic gestation as well as complications of early pregnancy.^[21,22] However, the transabdominal approach is still relevant in the assessment of early pregnancy and its complications, and can be used to compliment findings on transvaginal sonography where associated or co-existing intra-abdominal findings may not be well assessed via the transvaginal approach.^[17]

The mean age of patients in this study was 29.9 ± 5.1 years which was similar to that reported in other studies in the country.^[3-6,8] This corresponds to the peak age of sexual activity and reproductive career in most women. Over three-quarters of the women in this study presented with haemoperitoneum indicating late presentation. This is often a result of late registration of pregnancies and concomitant ignorance about the aetiology and clinical features of ectopic gestation. This finding is consistent with those from other studies in the country.^[3-8,23] Cornelius *et al.*^[5] in a retrospective descriptive study at Federal Medical Centre Owerri, found haemoperitoneum in 99.5% of the subjects studied, likewise, Igberase^[4] and Akaba,^[7] reported haemoperitoneum in 95.3% and 83.1% of patients, respectively. Baffoe^[24] in Ghana reported ruptured gestation in 98.1% of cases. In this study, the commonest presenting complaint was lower abdominal pain which occurred in 24 patients (72%). This was followed by vaginal bleeding in eight patients. Lower abdominal pain is often secondary to rupture and, not surprisingly, the commonest symptom seen in late presentation.^[3,8] Less than half of the patients had a bulky uterus which was in tandem with the early gestational age at presentation. Endometrial reaction (increased endometrial thickness and or pseudogestational sac) was noted in 28 patients. Decidualization of the endometrial plate in the absence of a gestational sac is an important sonographic finding in ectopic

pregnancy. However, must not be confused with endometrial changes in early pregnancy.

In all, 22 patients suspected to have ectopic pregnancy had haemoperitoneum on ultrasonographic assessment, most of which extended to the Morison's pouch and paracolic gutters. This was in concordance with the pattern of presentation seen in many studies in the region^[3-8,23] indicating the need to promote reproductive health education and awareness about early registration of pregnancy among the at risk population. The high sensitivity (88.4%) and positive predictive values (82.1%) of transabdominal ultrasonography from this study suggest that it can be used for the initial screening of ectopic pregnancy. However, the low specificity of 37.5% demands further ancillary testing in confirming or refuting the diagnosis. This may be a result of the few subjects studied and as such cannot be generalized. Gramith *et al.*^[17] suggested that though transvaginal ultrasonography improves diagnostic accuracy in early pregnancy, it should be used in conjunction with, and not as a total substitute for transabdominal ultrasound. Furthermore, Nyberg *et al.* in their study on sonographic evaluation of ectopic pregnancy, suggested that transvaginal sonography should be employed in the evaluation of women suspected of having an ectopic pregnancy when conventional transabdominal ultrasonography fails to show a living embryo.^[25]

However, the low specificity and negative predictive values of transabdominal ultrasound in this study indicates that it cannot be used to confidently rule out the presence of an ectopic gestation when the classical features of the condition (such as extra-uterine gestational sac or live ectopic gestation with or without evidence of rupture) are not seen.^[26,27] Transvaginal ultrasonography offering better direct access to the uterus and adnexa as well as better image resolution, and laparoscopy offering direct visualization of the pelvic cavity, are superior to transabdominal ultrasound in this regard.^[28,29]

Evaluation for the presence of ruptured ectopic gestation with transabdominal scan using intraoperative findings as the gold-standard showed sensitivity of 61% and specificity of 100% with positive and negative predictive values of 100% and 44%, respectively. This shows that transabdominal ultrasound

scan has a very high specificity and positive predictive value for detecting ruptured ectopic gestation. This implies that in all cases where there was no rupture found at surgery, preceding transabdominal ultrasound done was accurate in noting absence of rupture; and in all cases where ultrasound noted rupture with haemoperitoneum, these were consistent with findings at surgery. One explanation for the latter is that almost all the cases of haemoperitoneum detected with transabdominal scan were extensive, involving the Morison's pouch and paracolic gutters such that they were more likely to be detected during the transabdominal examination. Conversely, the relatively lower sensitivity and low negative predictive values implied that some cases of ruptured ectopic gestation were missed with transabdominal scan. This is likely to be seen in cases of slow-leaking ectopic gestation in which the leaking fluid is not significant enough to be detected on transabdominal ultrasonography and thus result in lower sensitivity and concomitant low negative predictive values due to high false negative scans, resulting in some cases of undiagnosed rupture. This setback in transabdominal evaluation of patients with ectopic pregnancy has been reported in studies comparing the diagnostic accuracy of transabdominal versus transvaginal ultrasonography in detecting ectopic pregnancy and its complications such as that by Thorsen *et al.*^[22] who found transvaginal sonography to be diagnostic of ectopic pregnancy in 23 (38%) out of the 60 patients with surgically proved ectopic pregnancies while transabdominal sonography was diagnostic in 13 (22%) of such patients. Similarly, Nyberg *et al.*^[25] reported that transvaginal sonography provided new information in 15 cases out of 25 ectopic gestations which were not observed on transabdominal sonography. There was excellent agreement between surgical findings and histological diagnosis in this study ($\kappa = 1.00$) which validates our use of intraoperative findings as a gold-standard.

The main limitation of this study, however, is the retrospective collation and analysis of data which made it difficult to obtain uniform and more specific information about the ultrasound findings, for example, where an appearance was not categorically stated as being absent in the ultrasound report, it was impossible to say if it was omitted or not seen at the time of the examination. In addition, the small sample size may introduce observer bias limiting application to the general populace; hence, this preliminary report.

Conclusion

The deployment of transvaginal ultrasonography in early pregnancy is yet to be widely practiced in Nigeria.^[14,20] A number of factors are responsible for this issue, such as non-availability of the equipment or technical skill required

to perform a transvaginal ultrasound scan and sometimes cultural beliefs. Thus the transabdominal route still plays a huge role in evaluating ectopic pregnancies especially in low-resource settings.^[14,20] As it has been established that transvaginal ultrasonography has a high diagnostic accuracy in detecting ectopic pregnancy and its complications, many authors have advocated the combined use of transabdominal and transvaginal ultrasonography. Therefore, transvaginal ultrasonography is indicated when transabdominal ultrasonography is inconclusive.^[17,25] The findings in this preliminary study show that transabdominal ultrasonography can still be used to diagnose ectopic pregnancy and detect its main complication (rupture with haemoperitoneum) in low-resource settings where availability of the equipment and or technical skill for transvaginal ultrasound is still limited.

Financial support and sponsorship

Nil.

Conflicts of interest

There are no conflicts of interest.

References

1. Surette A, Dunham SM. Early pregnancy risks. In: Alan H. DeCherney, Lauren Nathan, Neri Laufer, Ashley S. Roman, editors. *Current Diagnosis and Treatment: Obstetrics and Gynaecology*. 11th ed. USA: Appleton & Lange Publishers; 2013.
2. Varma R, Gupta J. Tubal ectopic pregnancy. *BMJ Clin Evid* 2009;1406.
3. Lawani OL, Anozie OB, Ezeonu PO. Ectopic pregnancy: A life-threatening gynecological emergency. *Int J Womens Health* 2013;515-21.
4. Igberase GO, Ebeigbe PN, Ighekoyi OF, Ajufoh BI. Ectopic pregnancy: An 11-year review in a tertiary centre in the Niger Delta. *Trop Doct* 2005;35:175-7.
5. Cornelius AC, Onyegbule A, Onyema, Uchenna ET, Duke OA. A five year review of ectopic pregnancy at Federal Medical Centre, Owerri, South East, Nigeria. *Niger J Med* 2014;23:207-12.
6. Omokanye LO, Balogun OR, Salaudeen AG, Olatinwo AW, Saidu R. Ectopic pregnancy in Ilorin, Nigeria: A four year review. *Niger Postgrad Med J* 2013;20:341-5.
7. Akaba GO, Agida TE, Onafowokan O. Ectopic pregnancy in Nigeria's federal capital territory: A six year review. *Niger J Med* ;21:241-5.
8. Igwegbe A, Eleje G, Okpala B. An appraisal of the management of ectopic pregnancy in a Nigerian tertiary hospital. *Ann Med Health Sci Res* 2013;3:166-70.
9. Gharoro EP, Igbafe AA. Ectopic pregnancy revisited in Benin City, Nigeria: Analysis of 152 cases. *Acta Obstet Gynecol Scand* 2002;81:1139-43.
10. Schoen JA, Nowak RJ. Repeat ectopic pregnancy: A 16-year clinical survey. *Obstet Gynecol* 1975;45:542-6.
11. Anorlu RI, Oluwole A, Abudu OO, Adebajo S. Risk factors for ectopic pregnancy in Lagos, Nigeria. *Acta Obstet Gynecol Scand* 2005;84:184-8.
12. Coste J, Bouyer J, Ughetto S, Gerbaud L, Fernandez H, Pouly JL, *et al.* Ectopic pregnancy is again on the increase. Recent trends in the incidence of ectopic pregnancies in France (1992-2002). *Hum Reprod* 2004;19:2014-8.
13. Sivalingam VN, Duncan WC, Kirk E, Shephard LA, Horne AW. Diagnosis and management of ectopic pregnancy. *J Fam Plann Reprod Health Care* 2011;37:231-40.

14. Iyoke CA, Ugwu OG, Ezugwu FO, Onah HE, Agbata AT, Ajah LC. Current approaches for assessment and treatment of women with early miscarriage or ectopic pregnancy in Nigeria: A case for dedicated early pregnancy services. *Niger J Clin Pract* 2014;17:419-24.
15. Walker JJ. Ectopic pregnancy. *Clin Obstet Gynecol* 2007;50:89-99.
16. Horne AW, Duncan WC, Critchley HO. The need for serum biomarker development for diagnosing and excluding tubal ectopic pregnancy. *Acta Obstet Gynecol Scand* 2010;89:299-301.
17. Gramith F, Sirr S, Hollerman J, Hawks L. Transvaginal versus transabdominal sonography in patients suspected of having ectopic pregnancy. *Minn Med* 1991;74:27-31.
18. Sawyer E, Jurkovic D. Ultrasonography in the diagnosis and management of abnormal early pregnancy. *Clin Obstet Gynecol* 2007;50:31-54.
19. AIUM practice guideline for the performance of obstetric ultrasound examinations. *J Ultrasound Med* 2010;29:157-66.
20. Airede LR, Ekele BA. Ectopic pregnancy in Sokoto, Northern Nigeria. *Malawi Med J* 2005;17:14-6.
21. Jain KA, Hamper UM, Sanders RC. Comparison of transvaginal and transabdominal sonography in the detection of early pregnancy and its complications. *AJR Am J Roentgenol* 1988;151:1139-43.
22. Thorsen MK, Lawson TL, Aiman EJ, Miller DP, McAsey ME, Erickson SJ, *et al.* Diagnosis of ectopic pregnancy: Endovaginal vs transabdominal sonography. *AJR Am J Roentgenol* 1990;155:307-10.
23. Swende TZ, Jogo AA. Ruptured tubal pregnancy in Makurdi, north central Nigeria. *Niger J Med* 2008;17:75-7.
24. Baffoe S, Nkyekyer K. Ectopic pregnancy in Korle Bu Teaching Hospital, Ghana: A three-year review. *Trop Doct* 1999;29:18-22.
25. Nyberg DA, Mack LA, Jeffrey RB, Laing FC. Endovaginal sonographic evaluation of ectopic pregnancy: A prospective study. *AJR Am J Roentgenol* 1987;149:1181-6.
26. Kirk E, Bourne T. Diagnosis of ectopic pregnancy with ultrasound. *Best Pract Res Clin Obstet Gynaecol* 2009;23:501-8.
27. Braffman BH, Coleman BG, Ramchandani P, Arger PH, Nodine CF, Dinsmore BJ, *et al.* Emergency department screening for ectopic pregnancy: A prospective US study. *Radiology* 1994;190:797-802.
28. Shalev E, Yarom I, Bustan M, Weiner E, Ben-Shlomo I. Transvaginal sonography as the ultimate diagnostic tool for the management of ectopic pregnancy: Experience with 840 cases. *Fertil Steril* 1998;69:62-5.
29. Chama CM, Obed JY, Ekanem IA. Transvaginal ultrasound scan versus laparoscopy in the diagnosis of suspected ectopic pregnancy. *J Obstet Gynaecol* 2001;21:184-6.