

Case Report

Third-trimester ultrasound diagnosis of twin-to-twin transfusion syndrome (TTTS) - A review of two cases

JA AKINMOLADUN, GO OBAJIMI¹Departments of Radiology, ¹Obstetrics and Gynaecology, Faculty of Clinical Sciences, University of Ibadan, Ibadan, Nigeria

ABSTRACT

Twin-to-twin transfusion syndrome (TTTS) is an unbalanced net transfusion of blood between twin fetuses through placental anastomoses. It is a complication of monochorionic diamniotic (MCDA) twin gestation in which one of the twins is the donor while the other twin acts as the recipient. TTTS without treatment is a major cause of increased morbidity and mortality among MCDA twin pregnancies. Ultrasound diagnosis and staging of TTTS are based on Quintero staging which influences the choice of management. We present two cases of ultrasound diagnosed TTTS. A 27-year-old G2P1+0 with twin gestation who had an ultrasound scan at 34 weeks gestation, and a diagnosis of Quintero stage 1 TTTS was made. She had an emergency caesarian operation and was delivered of two live babies. A 24-year-old G1P0+0 with twin gestation who had an ultrasound scan at 35 weeks gestation, with a diagnosis of Quintero stage 5 TTTS. The donor twin was alive while the recipient twin had hydrops fetalis with no cardiac activity. An emergency caesarian section was done and the donor twin survived. TTTS is a common complication among MCDA twins and it is a cause of increased morbidity and mortality among them. Early diagnosis through ultrasonography and prompt management will help reduce the morbidity and mortality associated with the syndrome.

Key words: Third trimester; twin-to-twin transfusion syndrome; ultrasound.


Introduction

Twin-to-twin transfusion syndrome (TTTS) is an unbalanced net transfusion of blood between twin fetuses through placental anastomoses occurring between 15 and 26 weeks of gestation.^[1] It affects majorly the monochorionic diamniotic (MCDA) twin gestation, although it has been described in some monochorionic monoamniotic (MCMA) twin pregnancies.^[2] About 10%–15% of monochorionic pregnancies will develop TTTS.^[1,2] In the 19th century, Friedrich Schatz, a German obstetrician, extensively studied the twinning process and was the first to postulate a relationship between vascular anastomoses and the development of TTTS.^[1,3]

Monochorionic twins normally exchange blood during gestation, and two patterns of interfetal transfusion have

been described based on ultrasound studies. The most frequent pattern which occurs in 90% of cases results from constant but balanced bidirectional interfetal transfusion between the twins. This means that transfusion from one is counterbalanced by transfusion from the other. In 10% of cases, a chronic imbalance in net flow develops, resulting in twin-to-twin transfusion (TTT). If this condition progresses, the recipient twin develops a generalized swelling which increases the risk of heart failure and hydrops fetalis.^[4] There is also polyhydramnios due to increased urinary output. Meanwhile, the donor twin remains small and underdeveloped with decrease in urinary output, which

Address for correspondence: Dr. GO Obajimi, Department of Obstetrics and Gynaecology, Faculty of Clinical Sciences, University of Ibadan, Ibadan, Nigeria. E-mail: gboleeyahoo.com

Access this article online	
Website: www.tjogonline.com	Quick Response Code 
DOI: 10.4103/TJOG.TJOG_2_18	

This is an open access journal, and articles are distributed under the terms of the Creative Commons Attribution-NonCommercial-ShareAlike 4.0 License, which allows others to remix, tweak, and build upon the work non-commercially, as long as appropriate credit is given and the new creations are licensed under the identical terms.

For reprints contact: reprints@medknow.com

How to cite this article: Akinmoladun JA, Obajimi GO. Third-trimester ultrasound diagnosis of twin-to-twin transfusion syndrome (TTTS) – A review of two cases. *Trop J Obstet Gynaecol* 2018;35:199-203.

may lead to renal failure and oligohydramnios. One cannot obviously expect the classical oligo-polyhydramnios sequence observed in MCDA twins in MCMA twins, so the diagnosis is based on the observation of polyhydramnios and discordant bladder size.^[4]

A staging method for TTTS was developed by Quintero which is now widely used in assessing the severity of the syndrome and when to intervene.^[5] The current treatment modalities for TTTS include serial amnioreduction^[6] and fetoscopic laser coagulation of vascular anastomoses.^[7] Without treatment, TTTS is a major cause of increased morbidity and mortality among MCDA twin pregnancy.^[5-7]

We present two MCDA twin gestations with TTTS diagnosed by ultrasound in the third trimester.

Case study 1

A 27-year-old G2P1⁺⁰ (1A) presented to the ultrasound unit of the antenatal clinic of the University College Hospital for a routine third-trimester ultrasound scan. The pregnancy was booked at 29 weeks + 1 day gestational age (GA) at the antenatal clinic of the University College Hospital, Ibadan. There were no complaints so far during the course of pregnancy. She had two previous ultrasound scans in private clinics which revealed normal development of the twin gestation.

Ultrasound findings revealed live twin gestation at a GA of 34 weeks + 1 day; they were in two different sacs; the first twin [Figure 1] had increased amniotic fluid around it with an unstable lie. The deepest vertical pool (DVP) was 11.1 cm and the placenta was seen anteriorly. The fetal heart rate was 135 bpm with regular rhythm. The urinary bladder was seen and the estimated fetal weight (EFW) was 2.25 kg.

The second twin [Figure 2] appeared stuck to the superior portion of the uterine cavity with minimal movement and minimal fluid seen around it. The DVP was 2.2 cm. Minimal urine was noticed within the urinary bladder. The fetal heart rate was 148 bpm. Doppler of both umbilical and middle cerebral arteries was done and they showed normal Doppler indices. Figure 3 shows Doppler ultrasound of the middle cerebral artery of the first donor twin. EFW was 2.2 kg. The cervical os was closed. An impression of MCDA twin gestation at 34 weeks GA with stage 1 TTTS was made.

The patient was referred to the emergency unit of the antenatal clinic where she was scheduled for an emergency lower segment caesarean which was done the same day. She was delivered of two live male neonates. Twin I (recipient twin) weighed 2.25 kg with Apgar score of 6¹ 9⁵, while twin

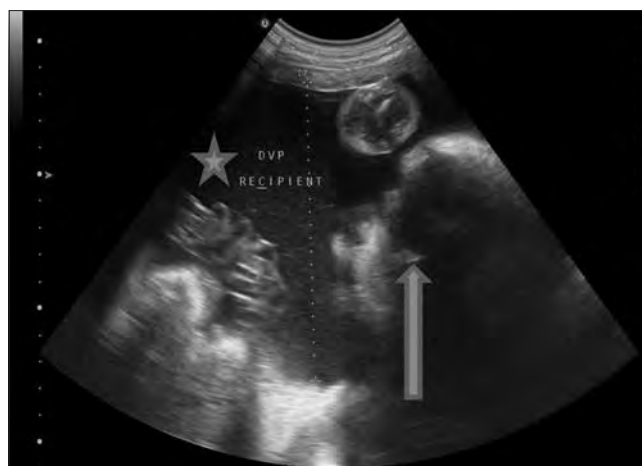

Figure 1: The recipient twin (block arrow) with increased fluid (star) around it. The deepest vertical pool was 11.1 cm

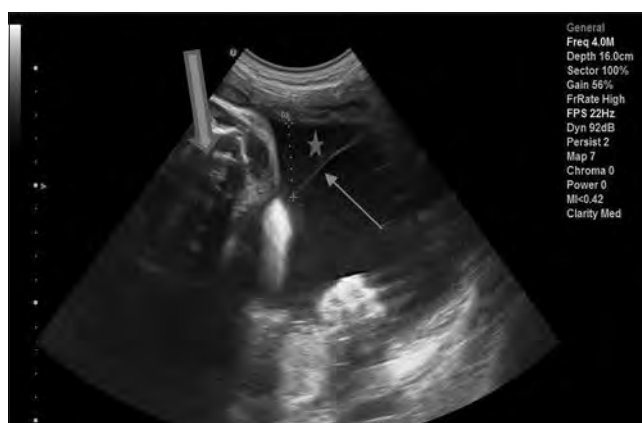

Figure 2: The "stuck" donor twin (thick arrow) with minimal fluid (star) around it. The DVP was 2.2 cm. The thin amniotic membrane (thin arrow) is seen to separate the two fetuses

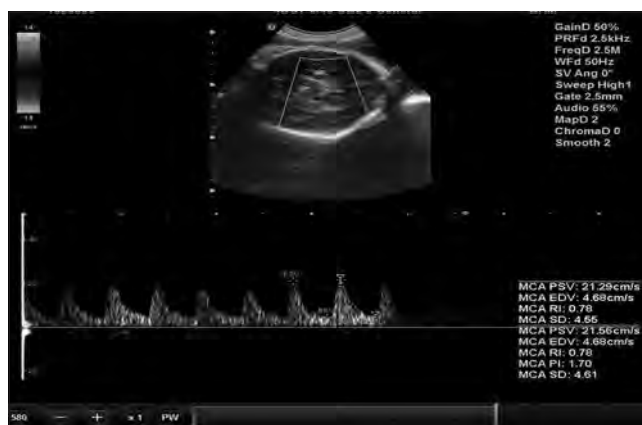

Figure 3: Doppler ultrasound of the middle cerebral artery of the first donor twin showing normal Doppler indices

II (donor twin) also weighed 2.25 kg with Apgar score of 8¹ 9⁵. Both babies were discharged home on the fourth day of life.

Case study 2

A 24-year-old primigravida with twin gestation presented

for routine ultrasound scan at 35 weeks GA at the ultrasound unit of the antenatal clinic of the University College Hospital, Ibadan. She booked the index pregnancy at 14 weeks GA and had four previous ultrasound scans at outside facilities which revealed MCDA twin gestation. No abnormality was detected.

Our ultrasound finding revealed twin female fetuses at a GA of 34 weeks + 1 day; they were in two different sacs; the first twin [Figure 4] showed no cardiac activity and it showed fluid within both pericardial and peritoneal cavities with skin edema. There was increased amniotic fluid around it with DVP of 12.3 cm [Figure 5a].

The second twin [Figure 5b] appeared stuck to the superior portion of the uterine cavity with minimal movement and minimal fluid seen around it with a DVP of 1.8 cm. Minimal urine was noticed within the urinary bladder. The fetal heart rate was 152 bpm and EFW was 2.5 kg, which was small for the GA and suggestive of some form of intrauterine growth restriction (IUGR). Doppler ultrasound of the umbilical artery, however, showed normal Doppler indices [Figure 6]. An impression of MCDA twin gestation at 34 weeks GA with TTTS Quintero stage 5 was made. An emergency caesarian section was done the same day and the donor twin survived with an Apgar score of 8¹ 10⁵ and fetal weight of 2.65 kg. She was discharged home on the fifth day of life, hale and hearty.

Discussion

TTTS, also known as fetofetal transfusion syndrome and twin oligohydramnios-polyhydramnios sequence is a complication of disproportionate blood supply between monozygotic twins, which results in high morbidity and mortality.^[1,4] The presence of placental vascular anastomoses is an etiological factor for the development of TTTS.^[3] Injection studies of twin placentas have shown that such anastomoses are almost invariably present in monozygotic twins and extremely rare in dichorionic twins.^[3,7-9]

Three types of anastomoses have been documented in monozygotic twin pregnancies: from artery to artery (AA), from vein to vein (VV), and from artery to vein (AV). AV anastomoses are unidirectional and are referred to as “deep” anastomoses since they proceed through a shared placental cotyledon, whereas AA and VV anastomoses are bidirectional and are referred to as “superficial” since they lie on the chorionic plate. AV anastomoses are found in 90%–95% of MCDA pregnancies, AA in 85%–90%, and VV in 15%–20%. TTTS is caused by net imbalance of blood flow between the twins due to AV anastomoses.^[8-10]

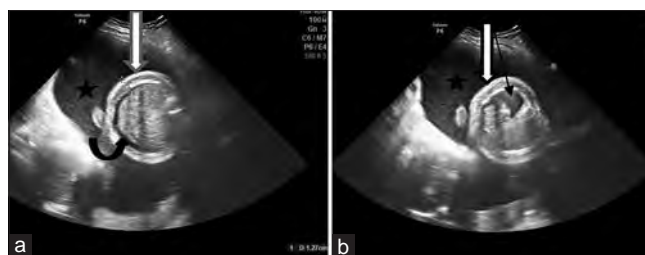


Figure 4: (a) Transverse view of the recipient through the abdomen showing skin edema (block arrow) and free fluid (ascites) within the abdomen (curved arrow). Increased amniotic fluid (star) is noticed around it. (b) Transverse view through the thorax showing skin edema (block arrow) as well as pericardial effusion (thin arrow)

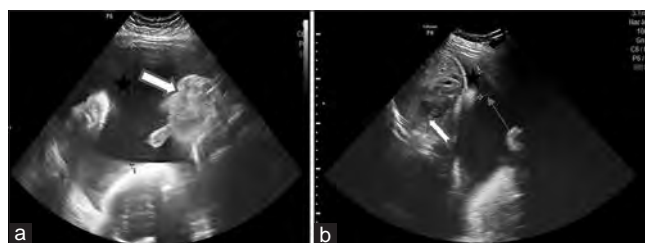


Figure 5: (a) Ultrasound image showing the recipient twin (block arrow) with increased fluid (star) around it. The deepest vertical pool was 12.3 cm. (b) The “stuck” donor twin (notched arrow) with minimal fluid (star) around it. The DVP was 1.8 cm. The thin amniotic membrane (thin arrow) is seen to separate the two fetuses

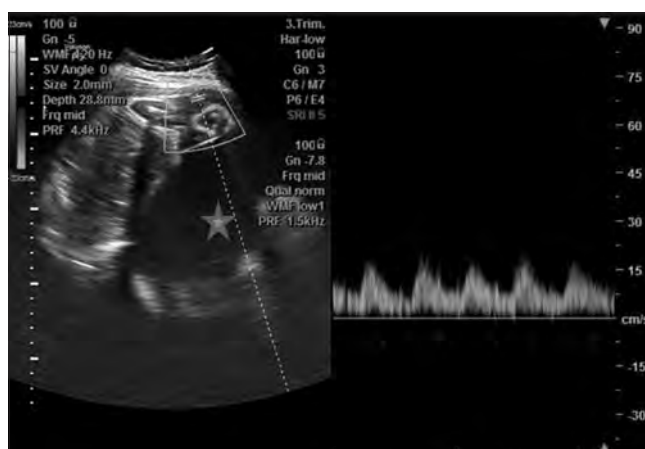

Figure 6: Doppler ultrasound of the umbilical artery of second “stuck” donor twin showing normal spectral wave pattern. Increased fluid (star) is noticed in the sac containing the recipient

The classification of TTTS is currently defined by a staging method by Quintero *et al.*^[5,11] which is based on ultrasound and Doppler studies [Table 1]. Five possible stages have been described in the progression of TTTS. This staging method is now widely used in assessing the severity of the syndrome and when to intervene. There has been a lot of debate about the Quintero staging method; it has been said that stage 1 does not necessarily have the best outcomes because some degrees of cardiac dysfunction have been noted within this stage. Another criticism is that it does not accurately

Table 1: Quintero staging

Stage	Ultrasound parameter	Criteria
I	DVP of amniotic fluid	DVP <2 cm in donor sac; DVP >8 cm in recipient sac
II	Fetal bladder	Non-visualization of fetal bladder in donor twin over 60 min of observation
III	Umbilical artery, ductus venosus, and umbilical vein Doppler waveforms	Absent or reversed umbilical artery diastolic flow, reversed ductus venosus a-wave flow, pulsatile umbilical vein flow
IV	Fetal hydrops	Hydrops in one or both twins
V	Absent fetal cardiac activity	Fetal demise in one or both twins

DVP, Deepest vertical pocket

represent a chronological order of deterioration and does not correlate with perinatal survival.^[5,11-13] Despite its limitations, Quintero staging is still a well-recognized tool in diagnosing TTTS and it is widely used to determine the severity of the condition and when to intervene. The two cases presented had stages 1 and 5, respectively.

A series of events occur in the twins; the donor twin develops anemia, hypotension, and oligohydramnios (deepest vertical pocket of amniotic fluid less than 2 cm), with the twin often stuck to the uterine wall and tightly wrapped in its amniotic sac, giving it the name “stuck twin.” This was noticed in the two cases presented. The fetal growth of this twin is also restricted leading to IUGR which was demonstrated in the second case presented. Poor blood circulation will eventually lead to renal failure with non-visualization of urine in the fetal bladder and fetal demise due to circulatory failure.^[4,5,11] There may also be derangement in Doppler studies evidenced by absent or reversed umbilical artery diastolic flow, low pulsatility index (PI) in the middle cerebral artery, reversed ductus venosus a-wave flow, or pulsatile umbilical vein flow.^[12] None of these was present in the two cases presented.

The recipient twin, on the other hand, would develop polycythemia from the increased blood volume, leading to hypertension which would cause great stress on the heart. Polyuria develops with increased urinary output in an attempt to reduce blood volume, consequently leading to polyhydramnios (deepest vertical pocket greater than 8 cm). Polyhydramnios was noticed in the sacs of the recipients in the two cases presented. A long-term complication of this is cardiac failure which is closely followed by hydrops fetalis; generalized swelling, pleural effusion, and accumulation of ascites; and then death^[5,11] which was demonstrated in second case presented.

TTTS usually presents in the second trimester and it is a dynamic condition that can remain stable throughout gestation, may regress spontaneously, progresses slowly over the weeks, or rapidly within a period of days with rapid deterioration in the well-being of the twins.^[9,13] Both cases presented were detected in the third trimester, which may

be as a result of lack of expertise by the sonographers who scanned them before their presentation at our facility.

The management options for TTTS include expectant management, amnioreduction, fetoscopic laser photocoagulation of placenta anastomoses, septostomy, and selective reduction.^[4,7,14] The management option varies depending on the GA and stage at the time of diagnosis. Recommendations about the timing of delivery vary and many factors such as the response to treatment, fetal growth, and disease progression determine the timing of delivery. However, the median GA at delivery for most studies which used laser treatment was 33–34 weeks, especially in severe cases. For stages I and II with reassuring surveillance, delivery is delayed till 34–37 weeks.^[4,15] The two cases presented had emergency caesarean sections as soon as the diagnosis was made. This was due to the fact that both were detected beyond fetal viability in the third trimester and also because surveillance and other less invasive therapeutic facilities are not available and routinely practiced at our center. This underscores the need for manpower development and funding in the area of feto-maternal care in the tropics.

Conclusion

TTTS is a common complication among MCDA twins and it is a cause of increased morbidity and mortality among them. Early sonographic diagnosis and prompt management by well-trained and equipped obstetric team would in no small measure stem the tide in the rising morbidity and mortality associated with the condition especially in low-income countries.

Declaration of patient consent

The authors certify that they have obtained all appropriate patient consent forms. In the form the patient(s) has/have given his/her/their consent for his/her/their images and other clinical information to be reported in the journal. The patients understand that their names and initials will not be published and due efforts will be made to conceal their identity, but anonymity cannot be guaranteed.

Financial support and sponsorship

Nil.

Conflicts of interest

There are no conflicts of interest.

References

1. Skupski DW. TTTS: Where did we come from? Distant history. In: Skupski DW, editor. *Twin-To-Twin Transfusion Syndrome*. 1st ed. New Delhi, London, Philadelphia, Panama: Jaypee Brothers Medical Publishers (P) Ltd; 2013. p. 3–15.
2. Botting BJ, Davies IM, Macfarlane AJ. Recent trends in the incidence of multiple births and associated mortality. *Arch Dis Child* 1987;62:941–50.
3. Lopriore E, Middeldorp JM, Sueters M, Vandenbussche FP, Walther FJ. Twin-to-twin transfusion syndrome: From placental anastomoses to long-term neurodevelopmental outcome. *Curr Pediatr Rev* 2005;1:191–203.
4. Osaghae DO, Unuigbo JA. Transfusion syndromes in monochorionic multiples: An overview. *Trop J Obstet Gynaecol* 2016;33:135-42.
5. Quintero RA, Morales WJ, Allen MH, Bornick PW, Johnson PK, Kruger M. Staging of twin-twin transfusion syndrome. *J Perinatol* 1999;19:550-5.
6. Crombleholme TM, Shera D, Lee H, Johnson M, D'Alton M, Porter F, *et al*. A prospective, randomized, multicenter trial of amnioreduction vs. selective fetoscopic laser photocoagulation for the treatment of severe twin-twin transfusion syndrome. *Am J Obstet Gynecol* 2007;197:396.e1-9.
7. Diehl W, Hecher K, Zilulnig L, Vetter M, Hackeloer BJ. Placenta vascular anastomoses visualized during fetoscopic laser surgery in severe mid-trimester twin-twin transfusion syndrome. *Placenta* 2001;22:876-81.
8. Fisk NM, Duncombe GJ, Sullivan MH. The basic and clinical of twin-twin transfusion syndrome. *Placenta* 2009;30:379-90.
9. Kaufmann P, Mayhew TM, Charnock-Jones DS. Aspects of human fetoplacental vasculogenesis and angiogenesis. Changes during normal pregnancy. *Placenta* 2004;25:114-26.
10. Lopriore E, Slaghekke F, Middeldorp JM, Klumper FJ, Oepkes D, Vandenbussche FP. Residual anastomoses in twin-to-twin transfusion syndrome treated with selective fetoscopic laser surgery: Localization, size, and consequences. *Am J Obstet Gynecol* 2009;201:66.e1-4.
11. Ville Y. Twin-to-twin transfusion syndrome: Time to forget the Quintero staging system? *Ultrasound Obstet Gynecol* 2007;30:924-7.
12. Tan TY, Taylor MJ, Wee LY, Vanderheyden T, Wimalasundera R, Fisk NM. Doppler for artery-artery anastomosis and stage-independent survival in twin to twin transfusion. *Obstet Gynaecol* 2004;103:1174-80.
13. Michelfelder E, Gottliebson W, Border W, Kinsel M, Polzin W, Livingston J, *et al*. Early manifestations and spectrum of recipient twin cardiomyopathy in twin-twin transfusion syndrome: Relation to Quintero stage. *Ultrasound Obstet Gynecol* 2007;3:965-71.
14. Lewi L, Jani J, Blickstein I, Huber A, Gucciardo L, Van Mieghem T, *et al*. The outcomes of monochorionic diamniotic twin gestation in the era of invasive fetal therapy: A prospective cohort study. *Am J Obstet Gynecol* 2008;199:514.e1-8.
15. Bebbington MW, Tiblad E, Hussler-Chrles M, Wilson RD, Mann SE, Johnson MP. Outcomes in a cohort of patients with stage I twin-to-twin transfusion syndrome. *Ultrasound Obstet Gynaecol* 2010;36:48-51.