

Case Report

Subserous uterine fibroid presenting atypically with features of pseudo-meig's syndrome

SULE-ODU AO, ANDU BABATUNDE¹, AKISEKU ADENIYI¹

Department of Obstetrics and Gynaecology, Faculty of Clinical Sciences, Obafemi Awolowo College of Health Sciences, Olabisi Onabanjo University, ¹Department of Obstetrics and Gynaecology, Olabisi Onabanjo University Teaching Hospital, Sagamu, Ogun State, Nigeria

ABSTRACT

To describe an atypical presentation of subserous uterine fibroid. We report a case of pseudo-Meig's syndrome from subserous uterine fibroid in a 31-year-old para 0⁺ woman who had myomectomy, appendectomy, and bilateral wedge resection of both ovaries. Histopathological examination confirmed uterine leiomyoma, appendicitis, and normal ovaries. Pseudo-Meig's syndrome is a condition which describes the association of any ovarian tumour (other than ovarian fibroma) or any other pelvic tumor such as leiomyoma with ascites and pleural effusion. Very few studies have reported the association of this entity with leiomyoma. It becomes highly important to identify this condition as it is a curable condition mimicking malignancy and can avoid unnecessary interventions. Subserous fibroid presenting with pseudo-Meig's syndrome is a rarely reported entity, especially in Nigeria, which can mimic malignant condition; hence, it is important to consider it as a differential in patients within the reproductive age presenting with ascites.

Key words: Atypical presentation; pseudo-Meig's syndrome; subserous uterine fibroid.

Introduction

Uterine fibroid is a benign smooth muscle tumor of the uterus that commonly affects women of reproductive age. Uterine leiomyomas are remarkably common, however, only a subset of women have fibroids clinically detected, have associated symptoms, or have surgical treatment.^[1] Although the cause of uterine fibroids remain unclear and the biology poorly understood, the key regulators of fibroid growth are ovarian steroids (both estrogen and progesterone), growth factors and angiogenesis, and apoptosis.^[1,2]

The lifetime risk of fibroids in a woman over the age of 45 years is more than 60%, with incidence higher in blacks than in whites.^[2] In Nigeria, an incidence of 9.3–24.7% had been reported.^[3-5] Known risk factors for uterine fibroids are black race, heredity, nulliparity, obesity, diabetes, and hypertension.^[6] Majority

of women with uterine fibroid are often asymptomatic; the common symptoms in symptomatic cases include menstrual dysfunction, sub-fertility, abdominal swellings, pressure related symptoms, urinary incontinence, or retention and pain.^[1]


Meig's syndrome refers to coexistence of pleural effusion and ascites with ovarian fibroma while pseudo-Meig's syndrome is defined by an association of any pelvic tumor other than ovarian fibroma with pleural effusion and ascites.^[7] Leiomyoma of the uterus or broad ligament are the most common tumours described.^[7] Other cases reported are germ cell tumours, mucinous, or serous cystadenoma and struma ovarii tumors.^[7]

Address for correspondence: Prof. Sule-Odu AO, Department of Obstetrics and Gynaecology, Faculty of Clinical Sciences, Obafemi Awolowo College of Health Sciences, Olabisi Onabanjo University, Sagamu, Ogun State, Nigeria. E-mail: adewalesuleodu@yahoo.com

This is an open access journal, and articles are distributed under the terms of the Creative Commons Attribution-NonCommercial-ShareAlike 4.0 License, which allows others to remix, tweak, and build upon the work non-commercially, as long as appropriate credit is given and the new creations are licensed under the identical terms.

For reprints contact: reprints@medknow.com

How to cite this article: Sule-Odu AO, Babatunde A, Adeniyi A. Subserous uterine fibroid presenting atypically with features of pseudo-meig's syndrome. Trop J Obstet Gynaecol 2018;35:93-5.

Access this article online	
Website: www.tjgonline.com	Quick Response Code 
DOI: 10.4103/TJOG.TJOG_75_17	

In Pseudo-Meig's syndrome, the pleural effusion and ascites usually contains no malignant cells and resolve after removal of tumour. However, the pathogenesis of the formation of ascites and pleural effusion in Meig's is unknown. It has been hypothesized that the fluid accumulation in the peritoneal cavity may result from imbalance between fluid production and lymphatic drainage in association with the tumour and pleural effusion arises secondary to ascites through passage in the diaphragm.^[7,8] Other variants of Meig's/pseudo-Meig's syndrome are sometimes associated with pericardial effusion necessitating pericardial drainage through pericardial fenestration and pericardiectomy.^[9]

Very few cases with such a condition from subserous uterine fibroid have been reported, especially in developed countries, none however reported draining as much as twelve litres of ascites seen in this case reported, we describe an atypical presentation of subserous fibroid with pseudo-Meig's syndrome.

Case Report

A 31-year-old artisan, para 0⁺⁰ was referred from a private hospital on account of progressive abdominal swelling and lower abdominal pain of 4 years duration, with progressive weight loss of 2 years duration. Easy satiety and bloating was also reported. She usually menstruates for 3 days in a regular 28 days cycle until 4 months prior to presentation when her menses ceased. She has been desirous of pregnancy for 5 years but no history of use of ovulation induction medications. She presented cachectic and pale with bilateral pitting pedal edema to the knees. The abdomen was grossly distended up to the xiphisternum and the abdominal organs were difficult to palpate. Fluid thrill was positive and bowel sounds appeared distant.

Abdomino-pelvic scan revealed massive ascites with floating bowel loops. There was a huge oval-shaped echogenic largely solid mass seen in the pelvis, more on the right, measuring 17.9 × 18.6 cm, features likely a huge ovarian mass. CA 125 was 403.9 u/ml. She was taken for surgery during which about 12l of clear ascitic fluid was drained from the intraperitoneal cavity. A huge subserosal uterine fibroid was seen with a stalk from the right lateral side of the fundus, measuring about 20 cm × 20 cm in dimension and completely enclosed by large tortuous omental vessels giving it a reddish fleshy appearance. A 12-week size intramural fibroid was seen along with an anterior cervical fibroid of 6 cm × 4 cm. The appendix was inflamed while the ovaries and tubes appeared grossly normal. The surfaces of the diaphragm and liver were free of deposits. There were no palpable para aortic and pelvic lymph nodes. She had myomectomy, appendectomy and bilateral wedge biopsies

of the ovaries. In the postoperative period, there was disappearance of ascites and restoration of normal breathing pattern. Cytology of the ascitic fluid was free for malignant cells. She was discharged on the 7th postoperative day.

She presented for follow-up visit at the gynecological clinic 2 weeks after discharge when there was no re-accumulation of ascites and no features of pleural effusion and she had normal breathing pattern. Histopathology showed uterine leiomyoma and acute appendicitis with normal ovaries.

Discussion

Meig's syndrome is a rare condition comprising ovarian fibroma with ascites and hydrothorax that quickly resolve after removal of the fibroma. Pseudo-Meig's syndrome is usually caused by a different tumors unlike ovarian fibroma in Meig's syndrome.^[7] Salmon in 1934 first described a similar clinical association of uterine fibromata with ascites and pleural effusion which was reported as either pseudo-Meig's or atypical Meig's syndrome.^[8] The cause of ascites in pseudo-Meig's associated with leiomyomas are not known, but it has been proposed to be due to leakage of intratumoral fluid as a result of hydropic degeneration of subserosal fibroid and peritoneal inflammation, or from direct pressure on surrounding lymphatics or vessels, hormonal stimulation, and tumor torsion.^[7,10] Uterine fibroid is the most common benign neoplasm that occurs in the female reproductive system presenting around the fourth decade of life. Majority of patients with fibroids are asymptomatic with the remainder presenting with symptoms and signs ranging from menstrual irregularities, pelvic pain, subfertility, and pressure symptoms to mention a few.^[11]

The patient illustrates the diagnostic dilemma with ultrasonography in establishing the origin of large pelvic masses; the subserous fibroid was taken for a huge ovarian mass. The ultrasonographic appearance of ovarian fibroma is variable, but usually seen as a solid hypoechoic mass with sound attenuation.^[12] Uterine fibroids typically appear as well-defined solid masses with a whorled appearance on ultrasonography, and are usually of similar echogenicity to the myometrium, but sometimes hypoechoic.^[12] However, taking into account the similar ultrasonographic features of ovarian fibroma and uterine fibroid and also the limited field of view on ultrasonography, it may be difficult to differentiate these conditions especially when the mass is large. In this patient the huge subserous fibroid and the ascites made it difficult to identify the normal ovaries. Magnetic resonance imaging has been demonstrated to be more sensitive than ultrasonography in establishing the origin of large pelvic masses.^[12]

Correct assessment and diagnosis of a possible clinical case of uterine leiomyoma is usually straightforward with the advent of ultrasonography, however, in a few clinical settings especially when the mass is large, it could present atypically causing diagnostic dilemma, as seen in the case.

Conclusion

Pseudo-Meig's syndrome caused by leiomyomas is quite rare. Very few cases with such a condition from subserous uterine fibroid have been reported in Nigeria/Africa; we describe an atypical presentation of subserous fibroid with pseudo-Meig's syndrome. One should entertain this in the differentials when confronted with a diagnostic dilemma in a patient within the reproductive age presenting with ascites. Identification of such a syndrome can result in an accurate diagnosis and appropriate surgical treatment.

Declaration of patient consent

The authors certify that they have obtained all appropriate patient consent forms. In the form the patient(s) has/have given his/her/their consent for his/her/their images and other clinical information to be reported in the journal. The patients understand that their names and initials will not be published and due efforts will be made to conceal their identity, but anonymity cannot be guaranteed.

Financial support and sponsorship

Nil.

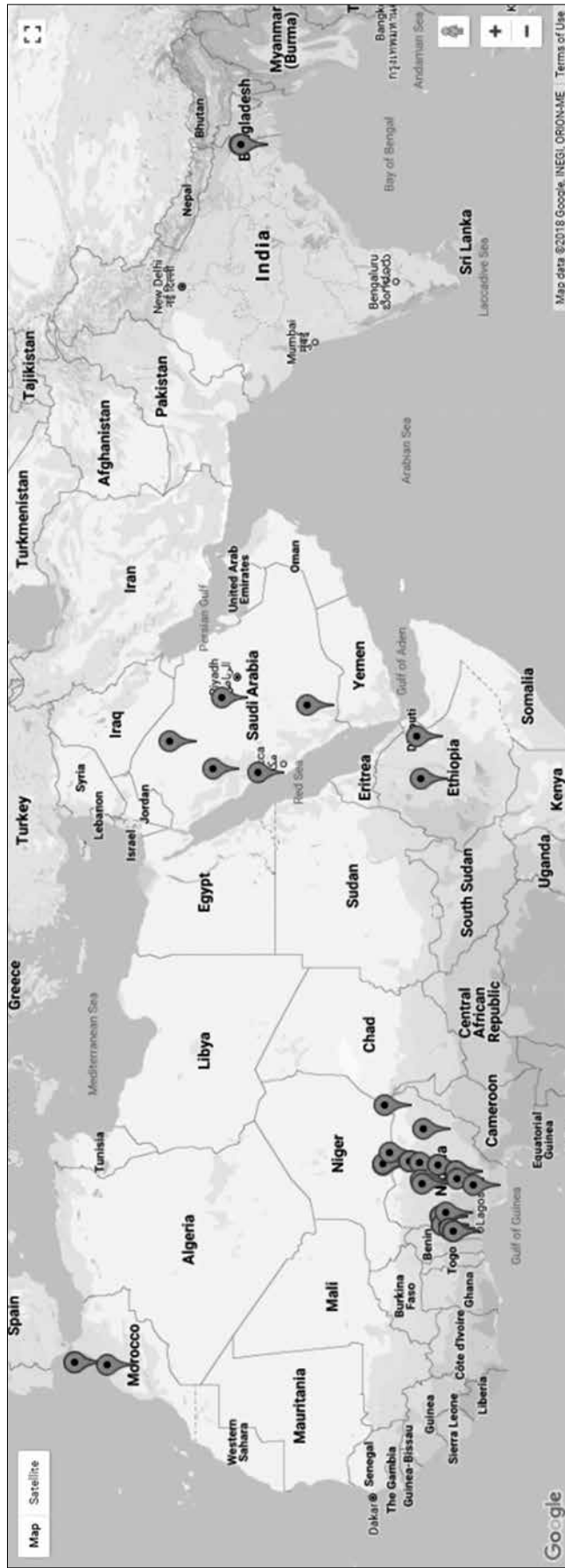
Conflicts of interest

There are no conflicts of interest.

References

1. Okogbo FO, Ezechi OC, Loto OM, Ezeobi PM. Uterine Leiomyomata in South Western Nigeria: A clinical study of presentations and management outcome. *Afr Health Sci* 2011;11:271-8.
2. Okezie O, Ezegwui HU. Management of uterine fibroids in Enugu, Nigeria. *J Obstet Gynaecol* 2006;26:363-5.
3. Ezeama CO, Ikechebelu JI, Obiechina NJ, Ezeama NN. Clinical Presentation of Uterine Fibroids in Nnewi, Nigeria: A 5-year Review. *Ann Med Health Sci Res* 2012;2:114-8.
4. Obuna JA, Umeora OU, Ejikeme BN, Ekwuatu VE. Uterine fibroids in a tertiary health centre South East Nigeria. *Niger J Med*. 2008;17:447-51.
5. Omole-Ohonsi A, Belga F. Surgical management of uterine fibroids at Aminu Kano Teaching Hospital. *Obstet Gynaecol Int* 2012;2012:702325.
6. Khaund A, Lumsden MA. Benign Disease of the Uterus. In: Edmonds DK, editor. *Dewhurst's Textbook of Obstetrics and Gynaecology*. 8th ed. United Kingdom: Wiley-Blackwell Publishing; 2012. pp 715-26.
7. Yamuna J, Rajeswaran R, Prabhu R, Usha R. Pseudo Meig's Syndrome: An Unusual Presentation. *Br J Med Med Res* 2016;11:1-4.
8. Liao Q, Hu S. Meigs' Syndrome and Pseudo-Meigs' Syndrome: Report of four cases and Literature reviews. *J Cancer Ther* 2015;6:293-8.
9. Kenichi O, Satoshi N, Osamu N, Masako I, Yasuhiro Y, Goh T, *et al.* A case of Meigs syndrome with preceding pericardial effusion in advance pleural effusion. *BMC Pub Med* 2016;16:71.
10. Amatya A, Rana A, Gurung G. Pseudo Meig's syndrome- a case report. *J Inst Med* 2006;28:77-9.
11. Su WH, Lee WL, Cheng MH, Yen MS, Chao KC, Wang PH. Typical and atypical clinical presentation of uterine myomas. *J Chinese Med Ass* 2012;75:487-93.
12. Ho G, Chan SWV, Lam PW, Chai J. Massive ascites in Pregnancy: Meig's Syndrome. *Hong Kong J Radiol* 2013;16:55-60.

Author Institution Mapping (AIM)



Please note that not all the institutions may get mapped due to non-availability of the requisite information in the Google Map. For AIM of other issues, please check the Archives/Back Issues page on the journal's website.