

# Preterm vaginal birth in the background of an unrepaired vesicovaginal fistula: A case report

**OLAJIDE E BABALOLA, OLUWASEUN O SOWEMIMO, OLUSOLA B FASUBAA**

Department of Obstetrics, Gynaecology and Perinatology, Obafemi Awolowo University Teaching Hospitals Complex, Ile-Ife, Osun State, Nigeria

## ABSTRACT

Obstetric fistula accounts for most genital tract fistulae seen in the developing countries and poses significant psychosocial stress on the woman. It is a cause of marital disharmony, stigmatization, and infertility. Thus, women with unrepaired vesicovaginal fistula (VVF) rarely present with coexisting pregnancy. We present a rare case of a 29-year-old unbooked G3P2 (1A) with unrepaired VVF who presented with an advanced second stage of labor of a preterm fetus at 32 weeks of gestation. She was referred from a primary health center in labor. She had ruptured her fetal membranes about 3 days before presentation. She had been experiencing continuous involuntary leakage of urine about 2 weeks after vaginal delivery of a macerated male stillbirth following prolonged labor at a traditional birth home about 13 months earlier. She had not sought any specialized care for her condition due to financial challenges. She had regular unprotected coitus despite urinary soiling; her menstrual cycle was regular and she achieved conception. At presentation, she was in intermittent painful distress with bearing down efforts and had ammoniacal fetor. Fundal height was 34 cm and a singleton fetus was palpated in longitudinal lie and cephalic presentation with a normal fetal heart rate. The fetal head was visible at the introitus without parting the labia, and amniotic liquor was foul smelling with ammoniacal dermatitis of the vulva and upper thigh. She delivered a live male baby with poor APGAR scores and birth weight of 1.96 kg. A 4 cm × 4 cm mid-vaginal defect was noticed on the anterior vaginal wall accommodating an inflated balloon of urethral catheter. She subsequently had VVF repair and rehabilitation. Financial challenge is an impediment to adequate care of VVF. This report establishes the possibility of regular coitus leading to conception and a live birth despite ongoing urinary soiling. Enhancement of social support services is advocated.


**Key words:** Infertility; vesicovaginal fistula; VVF repair.

## Introduction

Obstetric fistula accounts for most genital tract fistulae seen in the developing world.<sup>[1]</sup> Its occurrence poses social, psychological, and physical stress to affected women.<sup>[2]</sup> The passion for motherhood is an important aspect of social roles for women in our society and lack of accessible basic and comprehensive emergency obstetric care changes the path from safe motherhood to that fraught with significant maternal and perinatal morbidity and mortality, obstetric fistula inclusive.<sup>[3-6]</sup> Obstetric fistula is a known cause

of amenorrhea and infertility arising from malnutrition, hypothalamic dysfunction, panhypopituitarism, and intrauterine scarring.<sup>[7-9]</sup> Often, women with obstetric fistula are abandoned socially and sexually and rarely present with coexisting pregnancy in gynecological clinics.

**Address for correspondence:** Dr. Olajide E Babalola, Department of Obstetrics, Gynaecology and Perinatology, Obafemi Awolowo University Teaching Hospitals Complex, Ile-Ife, Osun State, Nigeria.  
E-mail: drjide360@gmail.com

Access this article online	
<b>Website:</b> www.tjogonline.com	<b>Quick Response Code</b> 
<b>DOI:</b> 10.4103/TJOG.TJOG_3_18	

This is an open access journal, and articles are distributed under the terms of the Creative Commons Attribution-NonCommercial-ShareAlike 4.0 License, which allows others to remix, tweak, and build upon the work non-commercially, as long as appropriate credit is given and the new creations are licensed under the identical terms.

For reprints contact: reprints@medknow.com

**How to cite this article:** Babalola OE, Sowemimo OO, Fasubaa OB. Preterm vaginal birth in the background of an unrepaired vesicovaginal fistula: A case report. Trop J Obstet Gynaecol 2018;35:87-9.

We present a rare case of a 29-year-old unbooked G3P2 (1A) with unrepaired vesicovaginal fistula (VVF) who subsequently got pregnant and presented with head on perineum of a preterm fetus at 32 weeks of gestation.

## Case Report

A 29-year-old unbooked G3P2 (1A) was referred from a peripheral health center in labor at 32 weeks of gestation. Her husband was a farmer and her highest educational level was senior school certificate. She had ruptured her fetal membranes for three days and had been in labor for about a day prior to presentation.

She gave a history of involuntary leakage of urine which started approximately 2 weeks after her last delivery about 13 months earlier when she had vaginal delivery of a macerated male stillbirth at term following prolonged labor which lasted for 5 days at a traditional birth attendant home. She used clothes and sanitary pads to contain urine and had not been able to get specialized care for her condition due to financial constraints. She resumed her menstruation approximately 12 weeks post-delivery and had regular unprotected penetrative and ejaculatory sexual intercourse with her husband despite the involuntary urine leakage. She had good social support from her husband and relatives. She became pregnant approximately 3 months after the return of her menstruation.

Her first confinement was 3 years earlier. She had uncomplicated vaginal delivery of a live male baby at term in a mission home. Birth weight was unknown.

At presentation in labor at our facility during her index pregnancy, she was in intermittent painful distress with

amniacal fetor. Her vital signs were within normal limits. The abdomen was uniformly enlarged with 34 cm fundal height and adequate uterine contractions. A singleton fetus was palpated in longitudinal lie, cephalic presentation, right occipito-anterior position, and the fetal heart tone was heard. She expressed the urge to bear down while being examined and progressed to deliver a live male baby birth weight 1.96 kg and poor APGAR scores necessitating neonatal ward admission. The liquor was turbid and foul smelling. Third stage of labor was actively managed. Urogynecological examination following delivery revealed moist vulva with amniacal dermatitis and involuntary urine leakage not associated with straining; an anterior vaginal wall defect [Figure 1] in direct communication with the urinary bladder with inflated balloon of urethral catheter bulging through the defect. The defect measured approximately 4 cm × 4 cm and is at the mid-vaginal portion. The baby and placenta are shown in Figure 2.

She was counseled on the findings and the need for fistula repair. Social health workers were invited to contribute to her care towards ensuring adequate care in view of her social class.

## Discussion

VVF is a cause of isolation, stigmatization, and depression in women, leading to marital disharmony. Amenorrhea, and by extension, infertility is a common complication of this condition.<sup>[7-9]</sup> Therefore, regular coitus is rare in such cases, and if it occurs, the likelihood of achieving conception is low.

Contrary to common findings that women with VVF are often ostracized by their husbands, families, and communities,<sup>[10]</sup> our patient had good family support. The presence of a living

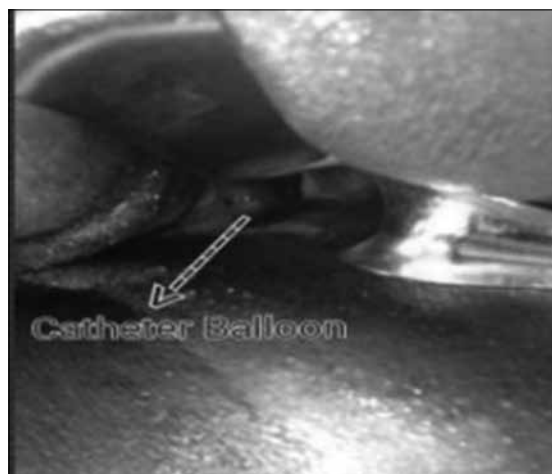

Figure 1: Picture showing the inflated urinary catheter balloon protruding through the defect on the anterior vaginal wall

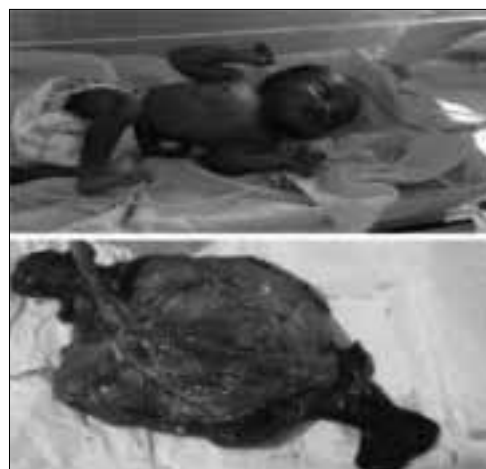

Figure 2: Picture showing the baby being nursed in incubator in Neonatal ward and the placenta below

child may be contributory to her marital stability as proposed in a study conducted in Zaria, Northern Nigeria.<sup>[11]</sup> She resumed spontaneous menstruation soon after developing urinary fistula, had regular coitus, and achieved spontaneous conception. She, however, had no formal antenatal care in pregnancy due to financial constraints. She had prelabor rupture of fetal membranes which she was able to differentiate from the persistent urinary leakage as a sudden gush of clear copious fluid *per vaginum*, which tracked to her limbs heralding the onset of preterm labor.

She presented in the second stage of labor and had vaginal delivery of a live baby. The preterm prelabor rupture of fetal membranes might have been as a result ascending infection from continuous drainage of urine. This was observed on the fetal membranes and necessitated antibiotics prescription in the postnatal period. The institution's social welfare unit was invited to enhance support and follow-up towards ensuring her fistula repair. She benefitted from the hospital's free VVF repair program and achieved continence following the repair.

## Conclusion

VVF is a known cause of marital disharmony, isolation, and amenorrhea. This case report identifies financial challenge as an impediment to seeking fistula care. It also establishes the possibility of regular coitus leading to conception despite ongoing urinary leakage. Enhancement of social support services is advocated in the care of women with this condition.

## Declaration of patient consent

The authors certify that they have obtained all appropriate patient consent forms. In the form the patient(s) has/have given his/her/their consent for his/her/their images and other

clinical information to be reported in the journal. The patients understand that their names and initials will not be published and due efforts will be made to conceal their identity, but anonymity cannot be guaranteed.

## Financial support and sponsorship

Nil.

## Conflicts of interest

There are no conflicts of interest.

## References

- Hilton P. Obstetric fistulae. In: Cardozo L, Staskin D, editors. Textbook of female urology and urogynaecology. London: Isis Medical Media Ltd; 2001. pp 711-9.
- Siddle K, Mwambingu S, Malinga T, Fiander A. Psychosocial impact of obstetric fistula in women presenting for surgical care in Tanzania. *Int Urogynecol J* 2013;24:1215-20.
- Landry E, Frajzyngier V, Ruminjo J, Asiimwe F, Barry TH, Bello A, *et al.* Profiles and experiences of women undergoing genital fistula repair: Findings from five countries. *Glob Publ Health* 2013;8:926-42.
- Nielsen HS, Lindberg L, Nygaard U, Aytenfisu H, Johnston OL, Sørensen B, *et al.* A community based long-term follow up of women undergoing obstetric fistula repair in rural Ethiopia. *BJOG* 2009;116:1258-64.
- Browning A. Pregnancy following obstetric fistula repair, the management of delivery. *BJOG* 2009;116:1265-7.
- Paxton A, Maine D, Freedman L, Fry D, Lobis S. The evidence for emergency obstetric care. *Int J Gynecol Obstet* 2005;88:181-93.
- Arrowsmith S, Hamlin EC, Wall LL. Obstructed labor injury complex: Obstetric fistula formation and the multifaceted morbidity of maternal birth trauma in the developing world. *Obstet Gynecol Surv* 1996;51:568-74.
- Wall LL. Dead mothers and injured wives: The social context of maternal morbidity and mortality among the Hausa of Northern Nigeria. *Stud Fam Plan* 1998;29:341-59.
- Ezegwui HU, Nwogu-Ikojo EE. Vesico-vaginal fistula in Eastern Nigeria. *J Obstet Gynecol* 2005;25:589-91.
- Harrison KA. Obstetric fistula: One social calamity too many. *BJOG* 1983;90:385-6
- Murphy M. Social consequences of vesico-vaginal fistula in Northern Nigeria. *J Biosoc Sci* 1981;13:139-50.