

*Trop J Obstet Gynaecol, 31 (1), April 2014*

## **B-LYNCH SUTURE-UTERINE ARTERY LIGATION IN SEVERE POSTPARTUM HAEMORRHAGE: FIRST EXPERIENCE AT A NEW TERTIARY INSTITUTION IN NIGERIA.**

***Babatunde Ajayi Olofinbiyi<sup>a</sup>, Olusola Peter Aduloju<sup>a</sup>, Biodun Nelson Olagbuji<sup>a</sup>, Idowu Pius Ade-Ojo<sup>a</sup>, Oluwole Dominic Olaogun<sup>b</sup>, Jide Michael Afolayan<sup>c</sup>.***

*<sup>a</sup>Department of Obstetrics and Gynaecology, Ekiti State University College of Medicine, Ado-Ekiti, Nigeria.*

*<sup>b</sup>Department of Obstetrics and Gynaecology, Ekiti State University Teaching Hospital, Ado-Ekiti, Nigeria.*

*<sup>c</sup>Department of Anaesthesia, Ekiti State University College of Medicine, Ado-Ekiti, Nigeria.*

### **ABSTRACT**

Postpartum haemorrhage is a major contributor to maternal morbidity and mortality. Numerous medical and surgical methods have been used to arrest bleeding but none has been uniformly successful. Experience with combined B-Lynch suture (Brace suture) and bilateral uterine artery devascularisation procedure is limited in southwestern Nigeria as there is dearth of data on it and most times (especially in our center) hysterectomy is done to secure haemostasis in severe postpartum haemorrhage which could as well, in well selected cases, respond to the procedures being described. A combined B-Lynch suture and bilateral ligation of the uterine vessels (the first experience in the centre of study) was done in the case reported below which was successful and effective with no complications. This is thus highly recommended as alternative to obstetric hysterectomy especially in well selected primipara.

(B-Lynch, uterine artery ligation, postpartum haemorrhage, Nigeria)

### **INTRODUCTION**

Postpartum haemorrhage (PPH) is an obstetric emergency that can follow vaginal or caesarean delivery. It is a major cause of maternal morbidity and one of the top three causes of maternal mortality in both high and low per capital income countries.<sup>1</sup> It has been estimated that worldwide, over 125,000 women die of postpartum haemorrhage each year.<sup>2</sup> Maternal morbidity and mortality rise with delay in diagnosis and management. Postpartum haemorrhage is commonly due to uterine atony, retained placenta including placenta accreta

and its variants, genital tract lacerations and coagulation abnormalities. However, uterine atony accounts for about 75-90% of all cases<sup>3,4</sup>. A study done in southwestern Nigeria revealed atonic postpartum haemorrhage as one of the commonest indications for obstetric hysterectomy (32.5%)<sup>5</sup>. There are a variety of medical and surgical treatments available for

---

**Corresponding Author:** Dr. B.A. Olofinbiyi  
tundereader@yahoo.com  
+234[0]8035033677

control of PPH, uterine artery ligation and B-Lynch suture are part of the conservative surgical techniques that preserve the uterus and fertility especially in low parity women<sup>6</sup>. A case report of severe postpartum haemorrhage in a primiparous, baby not alive, woman who had combined B-Lynch suture and uterine ligation is presented below. This type of case should rekindle awareness about effectiveness and remarkable conservative value of these procedures in severe postpartum haemorrhage due to atony or placenta praevia especially in a primipara whose baby's chance of survival is slim.

### **CASE SUMMARY**

A 27-year-old booked primigravida was admitted at a gestational age of 29 weeks with a complaint of bleeding per vaginum which was unprovoked and painless; with no bleeding from any other body orifices. There was no history of such bleeding earlier in the pregnancy. The index pregnancy had been uneventful until the onset of the presenting complaint. She was the only wife of her husband; got married eight months before presentation. She had a Bachelor degree in science. She neither smoked cigarettes nor drank alcohol. On examination, she was healthy looking, anxious, not pale or in respiratory distress. Her pulse rate and blood pressure were 90bpm and 110/70mmHg respectively. The uterus was about 30 weeks size. Obstetric ultrasonography revealed a single viable fetus with type IIb placenta praevia. She was managed as a case of antepartum haemorrhage due to major placenta praevia. While on bed rest, she developed a sudden onset of lower abdominal pains and torrential vaginal bleeding and was prepared for emergency caesarean section. She subsequently

delivered on the operating table a live female neonate weighing 1.1kg with Apgar Scores of 7 and 9 at 1 and 5 minutes respectively. She continued to bleed per vaginum despite being given oxytocic drugs (oxytocin infusion, 3 doses of intravenous ergometrin, 1000ug of misoprostol). Genital exploration was done that excluded cervical, vaginal and perineal lacerations. It was noticed that bleeding per vaginum reduced with uterine massage and bimanual compression while the uterus got atonic again and again between the acts of compression and massage. Since the patient was still bleeding profusely, laparotomy was performed. Intraoperatively, the uterus was intact but grossly atonic, no retained products of conception. As the vital signs were still fairly stable; with blood transfusion commenced, the B-Lynch suture was applied which significantly reduced the vaginal bleeding; with satisfactory haemostasis achieved by complimentary bilateral uterine artery ligation. Perioperative pulse rate and blood pressure ranges were 115-126 and 90/?-100/60mmHg respectively. Three units of cross-matched blood were transfused intra-operatively and one unit given post-operatively. She remained well on antibiotics and haematinics in the post-operative period and was discharged home on the 9<sup>th</sup> post-operative day with a packed cell volume of 28%; to be seen in two weeks. At two weeks her general condition was satisfactory; with a packed cell volume of 30%. However, her baby died at the neonatal intensive care unit on the 6<sup>th</sup> post-operative day. Six weeks post partum, patient was in good condition now with a packed cell volume of 35% (booking packed cell volume being 37%). She resumed menses 4 months post partum and menstrual periods have since been normal. She is being followed up.

## **MATERIALS AND METHOD**

After ascertaining the need for laparotomy, general anaesthesia was administered and the patient was put in the Lloyd Davies position, abdomen was cleaned and draped. A second assistant was stationed to observe the perineum, assessing the effectiveness of the procedures being carried out. A midline sub-umbilical incision was made on the skin which was deepened in layers to gain access to the peritoneal cavity. The bladder was retracted away from the lower uterine segment using Doyen's retractor. Above intraoperative findings were noted. A bimanual compression of the uterus was done which was observed to significantly reduce the bleeding per vaginum; thus informing the decision to apply B-Lynch suture as follows. The loose uterovesical peritoneum was picked with non-toothed dissecting forceps and incised transversely. With blunt finger dissection, the lower flap of the peritoneum and the bladder were separated from the lower uterine segment. The Doyen's retractor was now reinserted into peritoneal flap to displace the bladder downwards. The upper flap of the peritoneum was similarly formed. With continuous uterine compression maintained by the senior assistant, a low-transverse uterine incision was made and a large round bodied needle of chromic catgut 2 was used to puncture the uterus about 3cm inferior to the left edge of the uterine incision and 3cm from the left lateral border of the uterus. The suture was threaded through the uterine cavity to emerge 3 cm above the incision margin and 4cm from the left lateral border of the uterus. The suture was then passed over the fundus of the uterus about 4cm from the left cornual border and down posteriorly under moderate tension to pierce the uterine cavity at

the same level as the upper anterior entry point. The suture was now made to lie horizontally on the cavity side of the posterior uterine wall to pierce the wall bringing the suture over the top of the fundus and unto the anterior right side of the uterus. The needle re-entered the cavity exactly in the same way as it did on the left side to come out finally through 3 cm below the incision margin. The senior assistant maintained the compression as the suture material was milked through from its different portals to ensure uniform tension and no slipping. The two ends of the suture were put under tension and a double throw knot was placed for security to maintain tension after the lower segment incision had been closed in two layers.

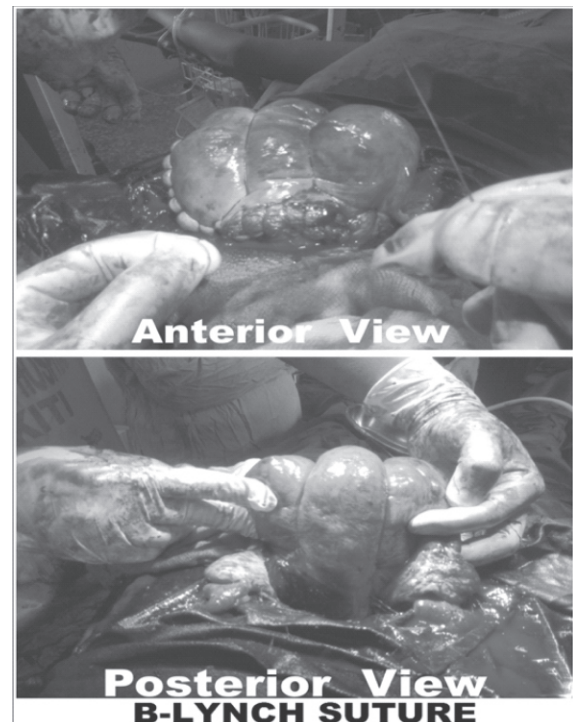
A bilateral ligation of the uterine vessels was done at four levels with chromic catgut 2 as follows. On the left side of the uterus, a curved needle with chromic catgut 2 was passed through the myometrium in the lower uterine segment, about 3cm medial to the uterine vessels and through an avascular area of the broad ligament; The suture was then tied to compress these vessels. The same procedure was repeated on the right side. The utero-ovarian anastomotic vessels were similarly ligated around the cornual end of the uterus just distal to the point of attachment of the ovarian ligament by passing a suture ligature through the myometrium just medial to the vessels, then back through the broad ligament just lateral to the vessels and then tied to compress the vessels; with precautions taken not to injure the tubes. The ligation of these vessels subsequently resulted in cessation of uterine bleeding. The uterovesical peritoneal fold was repaired. The procedures were well tolerated.

## DISCUSSION

Primary postpartum haemorrhage is a common obstetric emergency that can lead to emergency hysterectomy in medical treatment resistant life threatening bleeding and this still poses a great challenge to obstetricians especially the concern about the future loss of fertility in women of low parity.<sup>7</sup> A variety of surgical techniques have been proposed to avoid hysterectomy, each is associated with identifiable benefits and risks. Bilateral uterine and utero-ovarian arteries ligation have been recommended and found helpful in 95% cases of massive obstetric haemorrhage but not in cases of placenta praevia and accreta.<sup>8</sup>

The brace suture, which was first reported by B-Lynch, is very useful as an alternative to hysterectomy for control of massive postpartum haemorrhage with great success achieved in cases of placenta praevia and accreta. The net effect of B-Lynch suture is to compress the uterus as in bimanual compression. Conservation of the uterus and reproductive capacity as achieved by B-Lynch brace suture is its greatest advantage.<sup>6</sup> Previous reviews have demonstrated the effectiveness of brace suture<sup>6,9</sup>. Smith et al<sup>9</sup> reported that six out of seven cases of uterine atony that were unresponsive to oxytocic agents were successfully managed by B-Lynch compression suture and this should be applied before considering hysterectomy. Wergeland et al<sup>10</sup>, in their study, concluded that stepwise devascularisation and hysterectomy are technically difficult and time consuming while B-Lynch suture is less mutilating to women and can arrest serious postpartum haemorrhage. Here we have presented a case of severe obstetric haemorrhage in a primiparous, baby not alive, woman that was successfully managed by combined uterine vessels ligation and B-

Lynch compression suture. This was a departure from the usual emergency hysterectomy that is usually done. Therefore, in well selected cases, with good anaesthesia and quality blood transfusion facilities, combined use of B-Lynch suture and uterine vessels ligation is an easy and effective method of controlling severe postpartum haemorrhage thus saving life and preserving fertility potential.



## REFERENCES

1. Mousa HA, Alfirevic Z. Treatment for primary postpartum haemorrhage. Cochrane database Syst Rev 2003;:CD003249.
2. Hayman RG, Arulkumaran, Stear P.J. Uterine compression suture: Surgical management of postpartum haemorrhage. Obstet. Gynaecol. 2002; 99(3):502-6.
3. Macphail S, FitMacphail S, Fitald J. Massive postpartum haemorrhage. Curr Obstet Gynaecol 2001; 11: 108-14
4. Naheed F, Shakila Y, Joveria S. Combined

- use of B-Lynch brace suture and uterine packing in primary post-partum haemorrhage: saving life and fertility. *J Surgery Pakistan* 2010; 15(3): 144-46
5. Okogbenin SA, Gharoro EP, Otoide VO, Okonta PIJ Obstetric hysterectomy: fifteen years' experience in a Nigerian tertiary centre. *Obstet Gynaecol.* 2003 Jul;23(4):356-9.
  6. Shakila Y. B-lynch brace suture as an alternative to hysterectomy for severe postpartum haemorrhage. *Pakistan J Med. Res.* 2003; 42(3):
  7. Hackethal A, Brueggmann D, Oehmke F, Tinneberg HR, Zygmunt MT, Muenstedt K. Uterine compression sutures in primary post-partum haemorrhage after caesarean section: fertility preservation with a simple and effective technique. *Human Reproduction* 2008; 23(1): 74-9.
  8. O' Leary JA. Stop of haemorrhage with uterine artery ligation. *Contemp Obstet Gynaecol* 1986; 28: 13-6.
  9. Smith KL, Baskett JF. Uterine compression sutures as an alternative to hysterectomy for severe post-partum hysterectomy. *J Obstet Gynaecol* 2003; 25(3): 197-200.
  10. Weryeland H, Alagic E, Lokvik B. Use of B-Lynch suture technique in post-partum haemorrhage. *Tidsskr Nor Laegeforen* 2002; 122(4): 370-2.

### **Erratum**

A mistake in the name of the fourth author in the article titled "Anaemia in pregnancy: Maternal and parental outcome in Ibadan, South western Nigeria in Vol. 29, number 2, August 2012. In *TJOG* should read:

"Anaemia in pregnancy: Maternal and parental outcome in Ibadan, South western Nigeria".

David O. Awonuga, Akintunde A. Odukogbe, Oladapo Olayemi, Adetunji O. Adeniji.

The error is highly regretted.

### **Editor**