

THE GASTRO-CAMERA: TECHNIQUE AND DIAGNOSTIC VALUE IN GASTRIC DISEASE*

R. FOCHE, M.R.C.P., D.M.R.D., SIMMY BANK, M.B., CH.B., M.R.C.P., B. BROM, M.B., CH.B., I. N. MARKS, M.B., F.R.C.P., G. O. BARBEZAT, M.B., CH.B., M.D. AND Z. RUBINSTEIN, M.B., CH.B., F.C.P., M.MED. (RAD.),
Gastro-intestinal Service and Departments of Medicine and Radiology, Groote Schuur Hospital, Cape Town

Basically there are two ways of photographing the inside of the stomach: Firstly, a camera may be attached to the eyepiece of a gastroscope or fibrogastroscope and, secondly, a miniaturized camera may be introduced into the stomach, so that intragastric photographs of the mucosa may be obtained. The earliest photographs using the first method were obtained in 1938, and it is of interest that the passage of a camera into the stomach was originally attempted in 1898. However, it was not until the development of the gastro-camera in 1950 in Tokyo that really satisfactory photography using the internal technique of gastrophotography was achieved.¹ The instrument has been further perfected, and a range of gastro-cameras of varying grades of sophistication are now manufactured by the Olympus Optical Company of Tokyo.

The technique of gastrophotography has not yet been widely used outside Japan,²⁻⁵ but extensive literature on gastrophotography and its diagnostic uses, particularly in the diagnosis of early gastric cancer, is available from Japanese workers.⁶⁻¹⁰

The purpose of the present paper is to discuss our technique of gastrophotography and compare the relative value of gastro-camera, radiology, gastroscopy and the augmented histamine test in 108 consecutive patients.

METHODS

The Instrument

The Olympus GT gastro-camera, used in the present study, is illustrated in Fig. 1. The camera is situated at the tip of a flexible tube which connects it to the control unit. The camera is 10 mm. in diameter and the flexible tube 75 cm. in length. The lens has a focal length of 3.6 mm. and is stopped at f. 17 so that it has a wide focal range (2 - 10 cm.). Exposures are made by actuating the electronic flash bulb. The flash time is fixed to approximately 1/10 sec., but exposure can be varied by altering the voltage applied to the flash bulb and thereby altering the flash intensity.

*Date received: 19 February 1969.

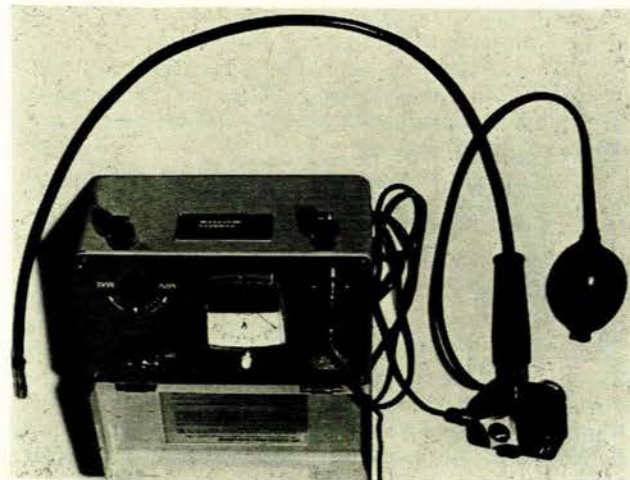


Fig. 1. Olympus GT 5 gastro-camera unit.

Air is introduced into the stomach through small valves at the tip of the instrument by using the rubber bulb attached to the control unit. Angulation of the tip through 35°, both upwards and downwards, gives added photographic coverage and is actuated by a knob on the control unit. After each exposure a fixed length of the film strip, which is contained in a cassette housed in the tip of the instrument, is wound up the tube.

The film strip, which is 5 mm. wide and approximately 300 mm. in length, permits 32 exposures (Fig. 2). One film strip is used per patient. The availability of Ekta-

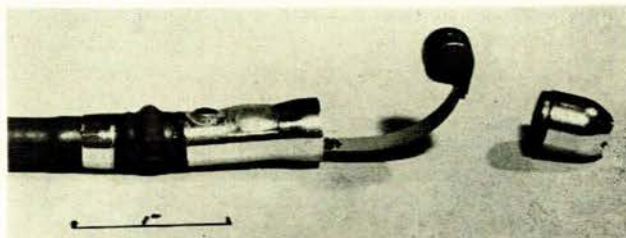


Fig. 2. Film strip attached to the end of the gastro-camera.

chrome colour film (ASA 125) makes it preferable to the Japanese films.

Two GT 5 gastro-cameras were used during the 3-year period of the present study. Only one significant instrument fault was encountered during this period.

Patient Preparation and Passage of the Instrument

The majority of the gastro-camera examinations were carried out on outpatients, most of whom had had a recent barium-meal examination. Gastrophotography was seldom carried out without a previous X-ray examination.

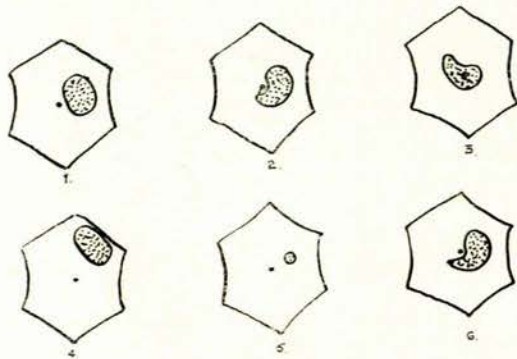
The patient was instructed to fast, following supper the previous evening (as for barium-meal examination). Pre-medication was not essential, but Valium, 5 - 10 mg. intravenously, was often used to facilitate the examination. An antifoam agent was sometimes administered $\frac{1}{2}$ hr before the examination. Gastric aspiration was carried out if the stomach was known to contain excess residue. The pharynx was anaesthetized with 4% Xylocaine spray immediately before passage of the instrument, and dentures, if present, were removed.

The instrument was usually passed with the patient lying on the left side, but the supine or sitting position was sometimes used. Passage was usually simple and pain-free, but difficulty was occasionally experienced in passing the pharynx. Delay in the lower oesophagus due to spasm was rarely encountered. Extreme gentleness was practised throughout the examination since hasty or rough handling almost invariably produced spasm, anxiety and pain which made the procedure difficult and uncomfortable. Requesting the patient to swallow and take deep, slow breaths concentrating on exhalation usually overcame oesophageal spasm. Oesophageal stricture was an obvious contraindication to the passage of the instrument, as was pharyngitis, severe oesophagitis or varices.

In our experience of over 400 examinations we have not encountered any morbidity resulting from the passage of the instrument.

Photography

Once the camera tip had been introduced into the stomach, the patient was turned supine, and the head of the table was lowered slightly to drain fluid into the fundus of the stomach. The room was then darkened. Approximately 15 bulbfuls of air were then introduced slowly in order to distend the stomach, the correct degree of distension being most important. The position of the camera in the stomach could be assessed by fluoroscopy, and this method is suggested if a difficult area of the stomach is to be examined, i.e. the cardia. With experience, however, fluoroscopy was seldom necessary since an accurate estimate of the position of the camera could be made from the position and shape of the light which transilluminated the abdominal wall when the electronic flash was activated (Fig. 3).



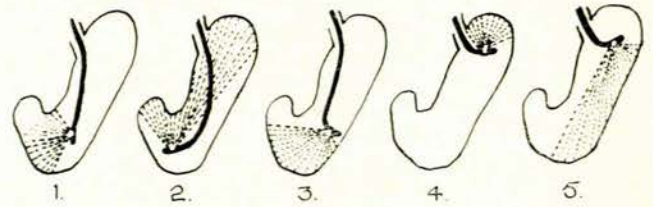
When adequate air is introduced the flash should be moderately large and diffuse. A small coin sized flash (5) means that the instrument is too near the stomach wall, and, either more air should be added, or the camera position should be changed.

- ① Area of lesser curve at and above angulus.
- ② Proximal antrum ~ distal body.
- ③ Antrum and pre-pylorus.
- ④ Fundus.
- ⑤ Low retroflexion.

Fig. 3. See text.

A routine method of photography should be adopted in order to ensure adequate coverage of the stomach, though this routine should be modified according to the shape of the stomach and also the area in which pathology is suspected. A study of the barium-meal examination is therefore of the greatest value in planning the gastro-photography. Usually photography is started with the camera just above the angulus. Photographs are exposed towards the lesser curve, then the anterior and posterior walls, before moving the instrument more distally. Three photographs are then obtained lower down, and so on. The patient holds his breath at the time of exposure. Fig. 4 shows the type of average coverage obtained in different positions. The shape of the stomach will, of

course, modify this considerably. Fig. 5 gives an indication of the area coverage obtained by tip angulation upwards, downwards or in the neutral position.



- ① Low lesser curve - angulus.
- ② Antrum - angulus.
- ③ Low greater curve and stomal region.
- ④ Fundus.
- ⑤ Mid greater curve.

Fig. 4. See text.

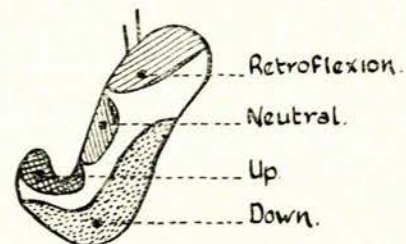
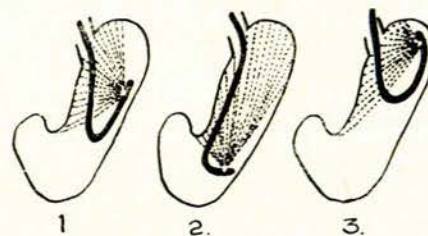


Fig. 5. See text.

The lesser curve of the body of the stomach and the region of the cardia and fundus are difficult to photograph satisfactorily in the average stomach, using the usual technique described above. In order to overcome this difficulty the Japanese developed the manoeuvre known as 'retroflexion' (Fig. 6). This manoeuvre is not particularly



- ① Lesser curve.
- ② General coverage of upper stomach.
[low retroflexion]
- ③ Fundus and cardia.
[high retroflexion]

Fig. 6. See text.

difficult to achieve, especially if fluoroscopy is used. With the tube high in the stomach, the camera is rotated towards the greater curve, the tip is angled up, and then the tube is passed further down and gently pressed against the greater curve. This usually produces a sufficient curve to achieve the manoeuvre.

Photographic results are usually excellent, though mucus on the lens or gastric spasm or excess fluid will render an examination useless. The time taken for an examination varies, but, with experience, is usually not longer than 5-7 minutes per patient.

Material

One hundred and eight consecutive patients referred to the Gastro-intestinal Service for investigation of abdominal symptoms were investigated. Barium-meal examinations were carried out by the senior radiological staff of the hospital. It is emphasized that the radiologist's report was accepted as the final radiological opinion for the purpose of this series. Gastroscopies (Herman-Taylor) were done by a member of the Gastro-intestinal Service and the gastro-camera studies by a member of the radiological staff. Acid secretory studies were carried out as a routine on all patients. The result reported by each investigator was accepted as the final result for the analysis of the data. The final diagnosis on laparotomy, clinical course or obvious lesion by one of the procedures are shown in Table I. Sixty-three patients were proved to have a

TABLE I. FINAL DIAGNOSIS IN 108 CONSECUTIVE CASES INVESTIGATED

Proved gastric lesion		No gastric lesion	
Lesion	No.	Diagnosis	No.
Gastric ulcer	45	No abnormality	27
Carcinoma	12	Duodenal ulcer	8
Polyp	2	Postgastrectomy	4
Lymphoma	2	Postvagotomy	3
Acute ulcer	2	Pernicious anaemia	3
Total	63		45

definite gastric lesion, and chronic gastric ulcer or carcinoma accounted for 57 of these. Forty-five patients were shown to have no gastric lesion and these covered a wide variety of non-gastric diseases or symptoms including 7 with symptoms after gastric surgery.

RESULTS

Patients with No Gastric Lesion

Considering first the 45 patients who were eventually shown to have no gastric lesion, the tests were in agreement, i.e. all showed a normal stomach in 22 (50%). The most important cause of non-agreement between the tests in the remaining 50% was, as one might expect, the radiological finding of a possible gastric abnormality—this was presumably the reason for referral for further investigation. Most of these patients had functional dyspepsia or other generalized or intestinal disease.

There were 2 patients in whom all the tests suggested the presence of possible gastric disease and in whom laparotomy disproved these findings.

Patients with Proved Gastric Lesions

The results in the 63 patients with proved gastric lesions (Table II) showed that the abnormality in the stomach was demonstrated by radiology in 81%, by gastroscopy in 76% and by gastro-camera in 80%. The augmented histamine test, although never diagnostic by itself, was very helpful in enhancing the probability of a lesion in 27%, particularly in suggesting a correct diagnosis of carcinoma in patients with a suspi-

cious gastric lesion or suspected benign gastric ulcer on one or other of the tests.

TABLE II. RELATIVE VALUE OF INVESTIGATIONS IN THE 63 PROVED GASTRIC LESIONS

Diagnosis	No. of cases	X-ray	Gastroscopy	Camera	Acid secretion
Gastric ulcer	45	39	33	36	5
Carcinoma	12	11	12	9	9
Polyp	2	1	2	2	1
Lymphoma	2	1	0	2	2
Acute ulcer	2	0	1	1	0
Total	63	52	48	50	17
% abnormality on test		81	76	80	27
Lesion suggestive only		7	5	7	
Misinterpretation		9	0	3	2
Total absolute accuracy of diagnosis		36	43	40	(15)
% absolute accuracy of diagnosis		53	68	63	(25)

However, the more or less 80% positive abnormal findings for each of the individual investigations proves, on closer analysis, to be flattering to these investigations (Table II). Hence, if one deducts those cases in which the lesion was suggestive only (for example, possible gastric ulcer, possible gastric carcinoma), as so often occurs, and where the lesion was visualized but its nature was unsure or misinterpreted (for example, possible ulcer, possible carcinoma or lymphoma) the effective absolute accuracy rate for each investigation is much reduced and the non-agreement between the tests considerable. The absolute accuracy rate was thus only 53% for radiology, 68% for gastroscopy, 63% for gastro-camera and 25% for acid studies (Table II).

Perhaps the most important considerations in the use of the combined investigative approach are (a) the presence of a gastric lesion where the barium meal is negative; (b) a negative or misinterpreted barium meal report in the presence of a carcinoma; and (c) the misinterpretation of all 4 tests combined.

A negative radiological report was returned in 9 patients who were later proved to have chronic gastric lesions (Table III). Two patients with acute ulcers or erosions, which are notoriously difficult or even impossible to demonstrate radiologically, have been excluded. Six were shown to have gastric ulcers and there was one

TABLE III. GASTRO-CAMERA, GASTROSCOPY AND ACID RESULTS IN 9 PATIENTS WITH NEGATIVE RADIOLOGY

X-ray	Gastroscopy	Camera	AHT	Diagnosis of 9 cases
—	++	±	±	Pre-pyloric ulcer
—	—	+	±	Lesser curve gastric ulcer
—	++	—	+(H)	Pre-pyloric ulcer
—	+	+	+(A)	Pyloric polyp
—	+	+	+(A)	Lesser curve carcinoma
—	+	+	±	Lesser curve gastric ulcer
—	±	++	+(A)	Lymphoma cardia
—	+	+	±	Posterior wall gastric ulcer
—	+	+	±	Pre-pyloric ulcer

TABLE IV. FINAL DIAGNOSIS IN 4 CASES WHERE ALL INVESTIGATIONS WERE MISINTERPRETED

	X-ray	Gastroscopy	Gastro-camera	AHT	Surgery
False negative	? Ca. antrum	Failed (TU)	—ve	Unhelpful	Gastric ulcer, lesser curve
	? Pre-pyloric ulcer	Irregularity	? —ve	Unhelpful	2 gastric ulcers, lesser curve
False positive	? Gastric ulcer, lesser curve	? Lesion	? Antral Ca.	No acid	—ve
	? Pre-pyloric ulcer	? Ca. ? Trauma	? Pre-pyloric ulcer	Unhelpful	—ve

4 cases only 1 test positive: radiology 2; camera 2
Complete non-agreement and only 1 test positive: 4 of 108 = 3.7%

each of carcinoma, lymphoma and pre-pyloric polyp.

A negative or misinterpreted radiological report was evident in 5 patients with proved carcinoma or lymphoma (Table IV). In 3 a benign ulcer was suspected from the barium-meal examination, and this emphasizes the need for a full gastric examination in patients reported as having a benign lesion before medical treatment is started.

In 4 of the 108 patients there was complete non-agreement between the tests. Two of these were false negatives in the sense that the presence of a gastric ulcer was missed or misinterpreted and 2 were false positive in the sense that each of the investigations suggested a possible lesion which was proved to be absent.

TABLE V. DIAGNOSTIC ACCURACY OF THE 4 PROCEDURES

	Proved gastric lesions (63)		All cases (108)
	% abnormality	Accuracy	
Radiology	81	53	66
Gastroscopy	76	68	81
Gastro-camera	80	63	85
Acid secretion	(27)	25*	(94)*
Total accuracy rate	96.8%		96.3%

* Acid studies compatible with the final diagnosis.

Conversely, there were 4 cases in which only 1 test was positive in proved gastric lesions—of these radiology showed the only positive abnormality in 2 and gastro-camera the only positive abnormality in 2. In addition, there were a number of cases in which an accurate diagnosis was made by one or other of the tests.

DISCUSSION

The value of a combined investigative approach in the diagnosis of gastric disease has been clearly established. In 1963 we reported a 96% diagnostic accuracy rate in 100 patients with gastric carcinoma by the combined use of radiology, gastroscopy, exfoliative cytology and acid secretory studies.¹¹ Since then a number of newer instruments have come into general use for a comprehensive gastric study. One of these, the gastro-camera, has been incorporated in the present study.

The final results of the investigations would appear, at first glance, to represent a rather disturbing picture: in only 51 of the 108 patients could complete agreement be reached in all 4 tests, and in no less than 57 cases there was non-agreement between the tests. However, this only seems to highlight the importance of the multiple combined approach to suspected gastric lesions. When all 4

tests were considered, the absolute diagnostic accuracy rate for proved gastric lesions was 96.8% and for all patients investigated with or without a gastric lesion 96.3% (Table V). Whether 100% diagnostic accuracy will be attained with the addition of newer fibroscopes with controllable ends, biopsy gastroscopes, more refined cytology and radioisotope techniques must await further appraisal. Clearly the odd submucosal carcinoma will from time to time defy all the presently available investigations.

The most common sites in the stomach for non-visualization, indefinite reporting or misinterpretation of lesions varied with the investigation. Radiology was frequently negative or indefinite in pre-pyloric or fundal lesions and also in flat, lesser-curve ulcers. Gastroscopy, in this instance with the partially flexible gastroscopes, was commonly negative in the same areas with an added high incidence of unsuccessful examinations. On the other hand, gastro-camera studies were particularly accurate in pre-pyloric, antral and fundal disease (provided retroflexion was used in the latter), the negative results occurring largely for technical reasons and by not using retroflexion in every case. The investigation has taught us that retroflexion is essential in every gastro-camera examination, even though radiology may suggest a lesion of the antrum or angulus only.

SUMMARY

This study has served to highlight the importance of a comprehensive gastric examination in suspected gastric disease, each of the tests complementing the others to produce a high diagnostic accuracy rate. Suspected pre-pyloric and fundal lesions are particularly amenable to diagnosis by gastro-camera and those on the lesser curve are more accurately interpreted by gastroscopy. Retroflexion is essential in all gastro-camera studies so that the whole of the lesser curve may be visualized.

We should like to thank Dr J. G. Burger, Medical Superintendent, for permission to publish; the members of the medical, surgical and radiological staff for their active support; and Mr T. Marais, senior photographer of the Hendrik Verwoerd Hospital, Pretoria, for supplying the Ektachrome film strips. This study was supported by the South African Council for Scientific and Industrial Research and the Herman Bequest.

REFERENCES

1. Uii, T., Shirokoro, T. and Hayashida, T. (1952): Tokyo Medical Journal, **61**, 135.
2. Chrysospathis, P. (1963): Surgery, **54**, 292.
3. Morrissey, J. F., Honda, T., Hara, Y., Juhl, J. H. and Perna, G. (1965): Gastroenterology, **48**, 711.
4. Hadley, G. D. (1965): Brit. Med. J., **2**, 1209.
5. Scarrow, G. D. (1967): Brit. J. Radiol., **40**, 23.
6. Loubser, J. S. (1966): S. Afr. J. Surg., **4**, 21.
7. Tasaka, S. (1959): *The Gastro-Camera*. Tokyo: Ogata Book Co.
8. Nakajima, T. and Miwa, S. (1960): Gastroint. Endosc., **1**, 71.
9. Takasu, S., Sakita, T., Kuroyanagi, S., Oguro, Y., Kashiwada, N., Ichikawa, H., Uamada, T. and Doi, H. (1963): Proceedings of the Annual Meeting of the Japan Endoscopic Society, p. 77.
10. The Endoscopic Group, National Cancer Centre Hospital, Tokyo (1964): Personal communication.
11. Louw, J. H., Marks, I. N., Bank, S. and Watson, C. E. (1963): S. Afr. J. Surg., **1**, 12.